


UNIVERSITY OF TORONTO



3 1761 00935850 8



Digitized by the Internet Archive  
in 2008 with funding from  
Microsoft Corporation















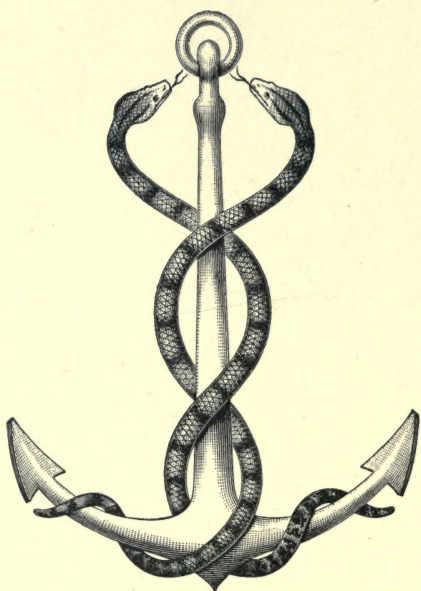
Mr. Henderson

Velyen E. Henderson





THE STUDY OF THE PULSE



NUNQUAM ALIUD NATURA, ALIUD SAPIENTIA DICIT.



THE  
STUDY OF THE PULSE  
ARTERIAL, VENOUS, AND HEPATIC  
AND OF THE  
MOVEMENTS OF THE HEART

BY  
(Sir) JAMES MACKENZIE, M.D. (EDIN.)  
BURNLEY

460937  
19.4.47

EDINBURGH AND LONDON  
YOUNG J. PENTLAND

1902

RC

74

M2

EDINBURGH: PRINTED FOR YOUNG J. PENTLAND, 11 TEVIOT PLACE AND 38 WEST  
SMITHFIELD, LONDON, E.C., BY R. AND R. CLARK, LIMITED

*All rights reserved.*

TO  
MY OLD FRIEND  
DR. JOHN BROWN





## PREFACE.

---

IN the following pages I give the results of an enquiry into certain features of the circulation which has engaged my attention for the last twenty years. Originally begun in order to ascertain the changes in the maternal circulation during pregnancy, the enquiry has broadened out, so that it embraces all forms of heart failure. For instance, I found pulse irregularity a very frequent symptom in pregnancy. The question was then forced upon me, "What is the clinical significance of pulse irregularity?" I think it will be readily admitted by all who are familiar with books dealing with the pulse that the present-day knowledge is not merely imperfect—it is chaotic. I was consequently led into a very intricate enquiry as to the different forms of pulse irregularity, and in order to appraise its value as a diagnostic sign I had to watch individual patients for many years during a great variety of conditions that entailed great stress upon the heart. The results of my enquiry I have now embodied, and this study has opened up a field for ingenious speculation far beyond what either physiologists or clinicians have imagined. Experimental observations have failed to give anything like the interesting and easily demonstrated results obtained by the simple methods I have employed. Apart from the academic interest that such a study may excite, it is of real service in giving us the true significance of, and bringing us into intimate relationship with, one of the most common and least understood symptoms that daily confronts the medical practitioner.

Another symptom that early arrested my attention was the pulsation that at times occurred in the jugular veins. These movements were so numerous and so rapid that no safe deductions could be drawn from observation alone. Several observers had obtained tracings of these movements, but they had failed to interpret them satisfactorily. Having devised a simple method for recording them, with the radial pulse as a standard, the interpretation of these movements became easy. The field of enquiry thus opened up is of exceptional interest, as it leads to the demonstration of the movements of the different chambers of the heart.

In dealing with the venous pulse I have been careful to avoid merely the registration of exceptional cases, but have extended my observations over a large number of patients and under a great variety of conditions.

Whilst I may have occasion to refer to what I consider the erroneous view of others, I am conscious that where so many more competent observers have erred, it is but likely that I should go astray. In writing this work the necessity therefore has been kept distinctly in view of giving a clear conception of the facts as distinct from the theories; on that account numerous illustrations have been used, and the manner of taking the tracings and of timing the events has been fully explained, so that should the interpretations be valueless, the recorded movements of the veins may still be reliable, and may serve for other and more fitting explanations.

In seeking a solution for the numerous questions that arose in connection with this study I was brought into intimate relationship with many other symptoms which have been hitherto either imperfectly described or erroneously interpreted. In order to get a complete view of the whole matter I have been forced to undertake a study of the arterial pulse, and of the movements of the heart. I was reluctant to do this, for the pulse has formed the subject of monographs by authors justly celebrated in their particular spheres. Nevertheless I found it impossible to deal logically with my results unless I ventured on a full description of the whole subject. For this purpose I

have attempted to reduce to order and system a vast amount of information which at present exists in a very nebulous condition in most medical books and in many medical minds. I do not profess to have been successful in the attempt, but I hope the arrangement here adopted will help in giving definiteness of aim to such as care to pursue the subject further. Much that I have written does not lead to definite conclusions, mainly for the reason that I have not had time to follow them out. Such chapters as that on "The Pulse and Respiration" are given to show what fields for investigation are still unexplored. Further, I have been as wishful to show where our information fails us in drawing definite conclusions, as in demonstrating where it leads to successful results.

Here I would like to say something regarding graphic records of the pulse and other movements of the circulation. It is now the fashion to decry the value of the sphygmograph. Some say that the information it is capable of demonstrating is exhausted, while others relegate it to the physiological laboratory. In my opinion the instrument has never yet had a fair chance. It was expected to give information of a kind that it was incapable of supplying. There are many ways in which the instrument can be usefully employed. It should be far more used in teaching, and thus students, accustomed to use the instrument, would become more familiar with the variations in the pulse. There are teachers in the present day demonstrating features in the circulation that are incorrectly perceived by their unaided senses, and which they wrongly interpret. Did they use graphic records to verify their observations, their teaching would gain in accuracy though it might lose in piquancy. Authors would add much to the value of their descriptions if, instead of relying upon their imagination and their rhetoric, they simply gave a pulse tracing. Thus when we find a leading authority on the heart telling us that "the pulse was irregular from loss of vagus control," can we for one moment pretend to understand what he means? The usefulness of the instrument in general practice will, I trust, be fully demonstrated in the following pages.



I am conscious that readers will find a lack of sequence in the development of the arguments in this volume. This is mainly due to two reasons. In order to complete the study of any one subject (as pulse irregularity), a reference to the venous pulse is necessary. But as this subject is at first somewhat difficult to comprehend, it would lead to confusion to give all the facts bearing on the subject at once. I have therefore first described the movements of the heart and the arterial pulse from facts that are part of our common knowledge. In order to render the subject more easy of study I have broken the text up into numerous sections, giving a heading to each section. These headings are not always very apposite, but they serve a useful purpose in rendering cross references easy. A second reason is the fact that this volume has been written amid the distractions of the life of a busy general practitioner. I have seldom been able to give an uninterrupted hour's study to the subject. While working out some argument interruptions have often been fatal to its completion, as it has been days and even weeks before I have again been able to resume it. While the working out of these problems has been a source of interest and of pleasure, the labour of writing them out has been a weariness to the flesh. This I do not offer as an excuse, but as an explanation.

In order to reduce this volume to reasonable limits I have avoided entering at length into the discussion of experimental observation and debatable points. I have therefore given such views as commended themselves to me by their reasonableness. Only a few references to authors are given. I had intended at one time to give a full bibliography, but did not find it necessary in view of the fact that this has been so admirably done in such works as those of Von Frey, Tigerstedt, and Gibson. A full bibliography of the venous and liver pulses will be found in my paper in the *Journal of Pathology and Bacteriology*.<sup>1</sup>

J. M.



# CONTENTS.



## PART I.—THE ARTERIAL PULSE AND MOVEMENTS OF THE HEART.

### CHAPTER I.

#### DETERMINATION OF THE VALUE OF SYMPTOMS.

	PAGE
§ 1. The pulse alone not a safe guide. § 2. Similarity of pulse in diseased and in healthy hearts. § 3. The cardiac field of response. § 4. The significance of pulse peculiarities. § 5. The personal equation in the examination of the pulse. § 6. Necessity of verification by instrumental methods . . . . .	3

### CHAPTER II.

#### INSTRUMENTAL METHODS OF EXAMINATION EMPLOYED IN THIS RESEARCH.

§ 7. The sphygmograph. § 8. The polygraph. § 9. The clinical polygraph . . . . .	8
--	---

### CHAPTER III.

#### INTERPRETATION OF A SPHYGMOGRAM.

§ 10. Definition of a sphygmogram. § 11. Relation of the arterial to the ventricular pressure. § 12. Nature of the information derived from the study of a sphygmogram. § 13. Events occurring during a cardiac revolution revealed by the sphygmogram: (a) the systolic period; (b) the diastolic period. § 14. Features of the sphygmogram due to instrumental defect. § 15. Conclusions drawn from the study of instrumental defects. § 16. The character of the arterial blood pressure as revealed by the sphygmogram. § 17. The significance of a well-marked systolic wave. § 18. The significance of dicrotism. § 19. The significance of hyperdicrotism. § 20. The correspondence between tracings from pulses with different arterial pressures . . . . .	16
---	----

## CHAPTER IV.

## THE MOVEMENTS OF THE HEART IN HEALTH AND DISEASE.

	PAGE.
§ 21. The standards for recognising the events in a cardiac revolution.	
§ 22. Conditions of the chest wall permitting the recognition of certain movements of the heart.	
§ 23. The nature of the movements.	
§ 24. The apex beat.	
§ 25. Interpretation of a tracing of an apex beat due to the systole of the left ventricle.	
§ 26. Retraction of yielding structures in the neighbourhood of the heart during ventricular systole.	
§ 27. Liver movements due to cardiac aspiration.	
§ 28. Epigastric pulsation.	
§ 29. The apex beat due to the right ventricle.	
§ 30. Change of the apex beat due to the left ventricle to one due to the right ventricle.	
§ 31. Significance of the inverted cardiogram.	
§ 32. Alteration of the apex beat due to retraction of the lung.	
§ 33. The shock due to the ventricular systole.	
§ 34. Clinical significance of the cardiogram	29

## CHAPTER V.

## FACTORS CONCERNED IN THE PRODUCTION OF THE PULSE.

§ 35. How the object of the circulation is attained.	
§ 36. The left ventricle.	
§ 37. The arteries.	
§ 38. The nerves.	
§ 39. The blood	47

## CHAPTER VI.

## THE PULSE FROM INFANCY TO OLD AGE.

§ 40. Periods of life.	
§ 41. Changes in the circulatory organs.	
§ 42. Relation of the normal conditions to the pathological.	
§ 43. The pulse rate.	
§ 44. Variation of the pulse rate due to stimulation of the heart.	
§ 45. Variations of the pulse rhythm.	
§ 46. Changes in the artery.	
§ 47. Changes in the pulse wave and arterial pressure.	
§ 48. Diminution of the capillary field and of the quantity of blood in the old	51

## CHAPTER VII.

## EXAMINATION OF THE PERIPHERAL CIRCULATION.

§ 49. Inspection of the capillary circulation.	
§ 50. Inspection of the minute cutaneous veins.	
§ 51. Inspection of the larger veins.	
§ 52. What is the pulse?	
§ 53. Inspection of the arteries.	
§ 54. Digital examination of the arterial pulse	58

## CHAPTER VIII.

## ARTERIAL PRESSURE.

§ 55. The causes of arterial pressure.	
§ 56. The standard of arterial pressure.	
§ 57. The character of the pulse in increased arterial pressure.	
§ 58. Con-	

ditions giving rise to increased arterial pressure. § 59. Recurrent high arterial pressure. § 60. Symptoms associated with increased arterial pressure. § 61. Recurrent high arterial pressure as a cause of angina pectoris. § 62. Vasomotor angina pectoris. § 63. Low arterial pressure. § 64. Character of the pulse in low arterial pressure. § 65. Conditions giving rise to low arterial pressure. § 66. Symptoms associated with low arterial pressure. § 67. The pulse in syncope . . . . . 67

CHAPTER IX.

PULSE IRREGULARITY.

§ 68. Classification of irregularities : *A. The youthful type of irregularity.* § 69. Relation of rate to rhythm. § 70. Irregularity with natural slowing of the pulse. § 71. Irregularity after fever. § 72. Conditions in which the youthful type of irregularity occurs : *B. The adult type of irregularity.* § 73. The features characteristic of the adult type of irregularity. § 74. Experimental evidence of pulse irregularity. § 75. Distinction between the youthful and adult types of irregularity. § 76. Descriptive terms. § 77. The effect of the premature systole on the apex beat. § 78. Auscultation of the heart during an irregular period. § 79. Rhythmical irregularities of the pulse. § 80. The strong beat after the irregularity. § 81. The dropped beat. § 82. The dropped beat causing an infrequent pulse. § 83. What is the right side of the heart doing during these irregularities? § 84. The premature systole occurring in groups. § 85. The factors determining the presence of the premature pulse beat. § 86. Some exceptional forms of irregularity. § 87. Mixed irregularities . . . . . 83

CHAPTER X.

THE CLINICAL SIGNIFICANCE OF PULSE IRREGULARITIES.

§ 88. Misconception of the symptoms of pulse irregularity. § 89. Irregularity not necessarily a bad sign. § 90. Pregnancy and pulse irregularity. § 91. Pulse irregularity and hard work. § 92. Pulse irregularity common after middle age. § 93. Pulse irregularity and a failing heart. § 94. Predisposition to irregularity. § 95. Pulse irregularity and mental affections. § 96. Pulse irregularity and fever. § 97. Pulse irregularity in pneumonia. § 98. Pulse irregularity and chloroform. § 99. Estimation of the value of pulse irregularity . . . . . 106

CHAPTER XI.

INCREASED FREQUENCY OF THE PULSE.

§ 100. Classification of cases. § 101. Cases in which the heart responds to a call upon its energy by increased frequency. § 102. Cases in which the pulse rate is continuously increased in frequency : (a) valvular diseases ; (b) affections of the myocardium : (c) pregnancy : (d) alcohol : (e) neuritic

	PAGE
cases ; ( <i>f</i> ) exhausting diseases ; ( <i>g</i> ) exophthalmic goitre. § 103. Cases in which the increased frequency occurs in irregular paroxysmal attacks :	
( <i>a</i> ) palpitation ; ( <i>b</i> ) paroxysmal tachycardia . . . . .	117

## CHAPTER XII.

### DIMINISHED FREQUENCY OF THE PULSE (BRADYCARDIA).

§ 104. The normal slow pulse. § 105. Occasional or recurrent bradycardia. § 106. Symptoms associated with recurrent bradycardia. § 107. Classification of cases. § 108. The slow pulse, with rhythmical action of all the heart chambers. § 109. The slow pulse due to missed beats. § 110. The slow pulse due to inhibition of the ventricle . . . . .	133
---	-----

## CHAPTER XIII.

### THE PULSE IN FEBRILE CONDITIONS.

§ 111. Response of the circulation to fever depends mainly on the nature of the poison. § 112. The pulse in ague. § 113. Response of the circulation to increased temperature. § 114. The pulse in sthenic fever. § 115. The pulse in asthenic fever. § 116. Varied reaction to fever according to idiosyncrasy and nature of poison. § 117. Increase of temperature without increase of pulse rate. § 118. The pulse in pneumonia. § 119. Summary . . . . .	137
--	-----

## CHAPTER XIV.

### SOME CHARACTERISTIC PULSES.

§ 120. Conditions giving rise to them. § 121. The pulse of aortic regurgitation. § 122. The alleged delay of the pulse in aortic regurgitation. § 123. The pulse in aortic stenosis. § 124. The pulsus bisferiens. § 125. The pulse in aortic aneurysm. § 126. Blocking of the lumen of an artery. § 127. Atheroma of the arteries. § 128. The mitral pulse. . . . .	148
--	-----

## CHAPTER XV.

### PULSE AND RESPIRATION.

§ 129. Sources of error in making observations. § 130. Variations in rhythm accompany variations in arterial pressure. § 131. The influence of the respiratory movements on the circulation. § 132. Effects of holding the breath on different pulses. § 133. Respiration and blood pressure. § 134. The pulse with slow respiration. § 135. The pulse with laboured respiration. § 136. The pulsus paradoxus. § 137. Type of pulse irregularity due to respiration . . . . .	162
---	-----



## PART II.—PULSATION IN THE VEINS AND LIVER.

## CHAPTER XVI.

## GENERAL INTRODUCTION.

	PAGE
§ 138. What the venous pulse shows. § 139. Movement of the blood in the veins. § 140. Pulsation in the peripheral veins. § 141. Movements in the veins due to respiration. § 142. Relation of the venæ cavæ to the venous flow. § 143. Incompetence of the ostial veins. § 144. Incompetence of the tricuspid valves. § 145. Incompetence of the jugular valves. § 146. Competence of the jugular valves. § 147. Sounds produced by the stretching of the valves in the veins. § 148. Inspection of the jugular pulse . . . . .	175

## CHAPTER XVII.

## CONSTITUTION OF THE VENOUS AND LIVER PULSES.

§ 149. The recognition of the events in a venous pulse. § 150. Description of the events in a cardiac cycle. § 151. The arterial pulse as a standard. § 152. The venous pulse represents the auricular pressure. § 153. The cause of the variations in the auricular pressure. § 154. The cause of the venous pulse. § 155. Illustration of the changes that take place in a venous pulse. § 156. The liver pulse when established more constant than the jugular. § 157. Individual cases illustrating changes in the venous and liver pulses. § 158. Division of the venous and liver pulses into two groups (auricular and ventricular) . . . . .	181
--	-----

## CHAPTER XVIII.

## CONDITIONS GIVING RISE TO THE VARIOUS FORMS OF THE VENOUS AND LIVER PULSES.

§ 159. The auricle remains active in the majority of cases. § 160. A powerful right ventricle with tricuspid incompetence necessary to paralyse the auricle. § 161. In muscle failure the auricle remains active. § 162. The liver pulse is absent in cases of muscle failure. § 163. The liver pulse of the auricular type implies hypertrophy of the auricle. § 164. The effect of tricuspid stenosis on the right auricle. § 165. Possible auricular hypertrophy in the absence of tricuspid stenosis . . . . .	194
--	-----

## CHAPTER XIX.

## THE AURICULAR FORM OF THE VENOUS PULSE.

§ 166. The auricular venous pulse differs from the liver pulse. § 167. The effect of the carotid pulse on tracings of the jugular pulse. § 168. The	
---	--

carotid wave in tracings by other observers. § 169. The period of stasis in the venous pulse. § 170. Changes due to variations in the rate of the heart's action. § 171. Timing with the arterial pulse necessary for the certain recognition of the nature of the venous pulse. § 172. Variations in the size of the auricular wave. § 173. Significance of the auricular and ventricular diastolic depressions. § 174. Prolongation of the ventricular wave after closure of the semilunar valves. § 175. The notch in the ventricular wave not due to instrumental defect. § 176. The cause of the increase in the ventricular wave after the closure of the semilunar valves . . . . .	197
--	-----

## CHAPTER XX.

### PARALYSIS OF THE AURICLE AND THE VENTRICULAR FORM OF THE VENOUS PULSE.

§ 177. Increase of the ventricular wave synchronous with diminution of the auricular wave. § 178. Paralysis of the auricle. § 179. A presystolic murmur is never present with a ventricular venous pulse. § 180. Is the left auricle also paralysed? § 181. The appearance of the wave in the ventricular venous pulse earlier than that of the systolic wave in the arterial pulse. § 182. The ventricular venous pulse represents the pressure variations within the right ventricle. § 183. The period of stasis in the ventricular, venous, and liver pulses. § 184. The post-sphygmic portion is the most constant part of the ventricular wave . . . . .	209
--	-----

## CHAPTER XXI.

### ENLARGEMENT AND PULSATION OF THE LIVER.

§ 185. Neglect of the signs and symptoms. § 186. Signs of congestive enlargement of the liver. § 187. Cause of the congestive enlargement. § 188. A liver pulse usually present in congestive enlargement. § 189. Intimate relationship between hepatic and venous congestion. § 190. Two forms of liver pulse. § 191. The auricular liver pulse a probable sign of tricuspid stenosis. § 192. Differences between the venous and liver pulses. § 193. Differential diagnosis of the liver pulse from (a) movements communicated to the liver by the heart; (b) the pulse of the abdominal aorta . . . . .	220
--	-----

## CHAPTER XXII.

### THE CLINICAL SIGNIFICANCE OF THE VENOUS AND LIVER PULSES.

§ 194. Difficulty in recognising a venous pulse. § 195. The grouping of cases. § 196. A. The venous pulse without organic valvular disease. § 197. The venous pulse is significant of cardiac dilatation. § 198. Cases in which the auricular venous pulse occurs. § 199. The venous pulse in recoverable conditions (anæmia, pregnancy, fatty loaded heart, etc.). § 200. The venous pulse in fatal exhausting diseases (malignant cachexia and pernicious anæmia) . . . . .	228
---	-----

CHAPTER XXIII.

THE CLINICAL SIGNIFICANCE OF THE VENOUS AND LIVER PULSES (*Continued*).

	PAGE
§ 201. The degeneration of the heart muscle (fatty and fibrous, due to atheroma, alcohol, and overstrain). § 202. Illustrative cases. § 203. In organic disease of the valves, a venous pulse not a constant symptom. § 204. Character and significance of the venous and liver pulses in mitral disease. § 205. Prognostic value of the venous and liver pulses in pregnancy . . . . .	234

CHAPTER XXIV.

THE CLINICAL SIGNIFICANCE OF THE VENOUS AND LIVER PULSES (*Continued*).

§ 206. Signs and symptoms of acute dilatation of the heart. § 207. Acute dilatation in advanced mitral disease. § 208. Acute dilatation in the absence of valvular disease. § 209. Illustrative case. § 210. Explanation of the change in the venous pulse. § 211. Acute dilatation in paroxysmal tachycardia . . . . .	244
---	-----

PART III.—THE VENOUS AND LIVER PULSES IN IRREGULAR ACTION OF THE HEART.

CHAPTER XXV.

IRREGULAR HEART ACTION WHERE THE AURICLES AND VENTRICLES PARTICIPATE IN THE IRREGULAR RHYTHM.

§ 212. Graphic records necessary for the interpretation of pulse irregularities. § 213. Classification of irregularities. § 214. Cases where the auricles and ventricles participate in the irregular rhythm: (a) in the youthful form of irregularity; (b) in the adult form of irregularity; (c) during a series of premature contractions; (d) during persistent bigeminal irregularity . . . . .	259
--	-----

CHAPTER XXVI.

IRREGULAR HEART ACTION WHERE THE AURICLE RETAINS ITS RHYTHM DURING VENTRICULAR IRREGULARITY.

§ 215. Cases in which this form of irregularity occurs: (a) during occasional bigeminal irregularity; (b) during persistent bigeminal irregularity. § 216. Duration of the irregular period. § 217. The jugular pulse in slow action of the heart. § 218. The absence of the ventricular wave in the jugular pulse when the auricle maintained its rhythm during an irregular period . . . . .	268
--	-----

## CHAPTER XXVII.

IRREGULAR HEART ACTION WHERE THE VENTRICLE FAILS TO RESPOND  
TO THE STIMULUS AFTER THE AURICULAR SYSTOLE.

	PAGE.
§ 219. Illustrative case. § 220. Explanation of the phenomenon. § 221. The ventricles acted together. § 222. Do the auricles act together?	279

## CHAPTER XXVIII.

## IRREGULAR HEART ACTION WITH PARALYSIS OF THE AURICLES.

§ 223. Varied forms of pulse irregularity. § 224. Agreement in rhythm of both ventricles. § 225. Bigeminal pulsation in the pulmonary artery	285
---	-----

## CHAPTER XXIX.

IRREGULAR HEART ACTION WHERE THERE IS DISCORDANCE OF THE  
RIGHT AND LEFT CHAMBERS OF THE HEART (HEMISYSTOLE).

§ 226. Hemisystole a rare symptom. § 227. Hemisystole with the auricles active. § 228. Hemisystole with the auricles paralysed	291
---	-----

## CHAPTER XXX.

## THE CAUSES OF PULSE IRREGULARITY.

§ 229. The premature systole. § 230. Cushny's experiments compared with clinical observations. § 231. A local stimulus the probable cause of pulse irregularity due to premature beats. § 232. Pulse irregularity and vagus influence. § 233. The youthful form of irregularity prob- ably due to vagus influence. § 234. The pulse in auricular paralysis. § 235. The pulse (arterial and venous) in digitalis poisoning	297
--	-----

## CHAPTER XXXI.

## SOME INTERESTING POINTS CONCERNING THE VENOUS PULSE.

§ 236. The nature of the waves in the veins. § 237. The symptom of auricular paralysis. § 238. The relationship of the venous and arterial pressures. § 239. The arhythmic contraction of the cardiac cavities. § 240. The venous pulse in adherent pericardium. § 241. Summary	308
--	-----

INDEX	323
-------	-----



## REFERENCES.

1. MACKENZIE . . . "The Venous and Liver Pulses and the Arhythmic Contraction of the Cardiac Cavities."—*Journ. Path. and Bacteriol.*, Edin. and London, 1894, vol. ii. p. 84.
2. GERHARDT . . . *Klinische Untersuchungen über Venenpulsationen*, Leipzig, 1894.
3. VON FREY . . . *Die Untersuchung des Pulses*, Berlin, 1892.
4. ROY and ADAMI . . . "Heart Beat and Pulse Wave," *Practitioner*, London, 1890.
5. HUNTER . . . *Works*, Palmer's edition, 1835, vol. iii. p. 226.
6. MOSSO . . . *Die Diagnostik des Pulses*, Leipzig, 1879.
7. DELÉPINE . . . "Preliminary Report on the Meaning of Cardio-Pneumatic Impulses," *Brit. Med. Journ.*, London, 1891, vol. ii.
8. KEYT . . . *Sphygmography and Cardiography, Physiological and Clinical*, New York and London, 1887, p. 193, Fig. 113.
9. ROY and ADAMI . . . "Contributions to the Physiology and Pathology of the Mammalian Heart," *Phil. Trans.*, London, 1892, vol. clxii. B.
10. TIGERSTEDT . . . *Lehrbuch der Physiologie des Kreislaufes*, S. 31.
11. BROADBENT . . . *The Pulse*, London, 1890, p. 18.
12. MAREY . . . *La circulation du sang*, Paris, 1881, p. 195.
13. ALLBUTT . . . "Albuminuria in Pregnancy," *Lancet*, London, 1897, vol. i.
14. CAHEN . . . "Des nervoses vaso-motrices," *Arch. gén. de méd.*, Paris, 1863, tome ii. pp. 504 and 696.
15. LANDOIS . . . "Der Symptomencomplex "Angina Pectoris" physiologisch. analysirt, etc.," *Cor.-Bl. d. deutsch. Gesellsch. f. Psychiat.*, 1866.
16. NOTHNAGEL . . . "Angina Pectoris Vasomotoria," *Deutsches Arch. f. klin. Med.*, Leipzig, 1867.
17. POWELL . . . Allbutt's *System of Medicine*, 1899, vol. vi. p. 28.
18. HÜRTHLE . . . "Beiträge zur Haemodynamik," *Arch. f. d. ges. Physiol.*, Bonn, Bd. xlix. Tafel, Fig. 10.
19. MAREY . . . *Op. cit.*, p. 122.
20. WENCKEBACH . . . "Zur Analyse des unregelmässigen Pulses," *Ztschr. f. klin. Med.*, Berlin, 1899, Bd. xxxvi. S. 181.
21. CUSHNY . . . "On the Interpretation of Pulse Tracings," *Journ. Exper. Med.*, N.Y., 1899, vol. iv. Nos. 3 and 4.
22. TRAUBE . . . "Ein Fall von Pulsus Bigeminus, etc.," *Berl. klin. Wchnschr.*, 1872, No. 16, p. 185.
23. TRIPIER . . . "Des déviations du rythme cardiaque associées à l'épilepsie, à la syncope, etc.," *Rev. de méd.*, Paris, 1883, tome iii. p. 1001 et seq.

24. RICHARDSON . . . *Discourses on Practical Physic*, London, 1871.
25. BROADBENT . . . *Op. cit.*, p. 120.
26. RICHARDSON . . . "On Death by Chloroform," *Asclepiad*, London, vol. vii. No. 25.
27. ROUSSEAU . . . *Confessions of*, 4 vols., London, 1897, Book vi. pp. 82 and 113.
28. ALLBUTT . . . *System of Medicine*, 1898, vol. v. p. 825.
29. HENDERSON . . . *Edin. Med. Journ.*, 1837.
30. FLINT . . . *Diseases of the Heart*, p. 141.
31. BALFOUR . . . *Clinical Lectures on Diseases of the Heart and Aorta*, 1876.
32. BROADBENT . . . *Heart Disease*, London, 1897, p. 142.
33. MACKENZIE . . . "The Alleged Retardation of the Pulse in Aortic Regurgitation," *Edin. Med. Journ.*, Oct. 1898.
34. FRANÇOIS-FRANCK. *Compt. rend. Soc. de biol.*, Paris, Jan. 27, 1883.
35. KEYT . . . . . *Loc. cit.*
36. HÜRTHLE . . . . . *Loc. cit.*
37. BROADBENT . . . *Op. cit.*, p. 143.
38. GRAHAM STEELL "Pulse in Aortic Stenosis," *Lancet*, London, 1894, vol. ii.; "The Use of the Sphygmograph in Clinical Medicine," 1899.
39. BROADBENT . . . "Pulsus Bisferiens," *Brit. Med. Journ.*, London, 1899, vol. i. p. 75.
40. FRANÇOIS-FRANCK. *Journ. de l'anat. et physiol.*, etc., Paris, 1878, tome xiv.; 1879, tome xv.
41. WALLER . . . . . *Human Physiology*, 1891, p. 145.
42. BERNARD . . . . . *Compt. rend. Acad. d. Sc.*, Paris, 1858, p. 159.
43. PALMER . . . . . *Works of John Hunter*, London, 1825, vol. iii. p. 227.
44. CHAUVEAU and FAIVRE "Nouvelles recherches expérimentales sur les mouvements et les bruits normaux du cœur," etc., *Gaz. méd. de Paris*, 1856, tome v. p. 406.
45. FRIEDREICH . . . "Krankheiten des Herzens," 2te Aufl., Erlangen, 1867, S. 53; "Ueber den Venenpuls," *Deutsches Arch. f. klin. Med.*, Leipzig, 1865, Bd. i. Heft 3, Figs. 26, 27, 28, and 29.
46. POTAIN . . . . . "Des mouvements et des bruits qui se passent dans les veines jugulaires," *Mém. Soc. méd. hôp. de Paris*, 1867, p. 3.
47. RIEGEL . . . . . "Ueber den normalen und pathologischen Venenpuls," *Deutsches Arch. f. klin. Med.*, Leipzig, 1882, Bd. xxxi.
48. MOSSO . . . . . *Op. cit.* p. 64, Fig. 15.
49. PRAMBERGER . . . "Ein Beitrag zur Beobachtung des normalen Venenpulses," *Wien. klin. Wchnschr.*, 1885, Nos. 12 and 13.
50. GALABIN . . . . . "On the Construction and Use of a New Form of Cardiograph," *Med.-Chir. Trans.*, London, 1875, vol. lviii. p. 353, Fig. 4.
51. GIBSON . . . . . *Diseases of the Heart and Aorta*, 1897, p. 202.
52. GRAHAM STEELL "Heart Failure as a result of Chronic Alcoholism," *Med. Chron.*, Manchester, April 1893.
53. CHAUVEAU . . . "De la dissociation du rythme auriculaire et du rythme ventriculaire" *Rev. de méd.*, Paris, 1885, p. 161.

THE STUDY OF THE PULSE





PART I

THE ARTERIAL PULSE AND MOVEMENTS OF  
THE HEART



# THE STUDY OF THE PULSE

## CHAPTER I

### DETERMINATION OF THE VALUE OF SYMPTOMS

- § 1. The pulse alone not a safe guide.
2. Similarity of pulse in diseased and in healthy hearts.
3. The cardiac field of response.
4. The significance of pulse peculiarities.
5. The personal equation in the examination of the pulse.
6. Necessity of verification by instrumental methods.

§ 1, *The pulse alone not a safe guide.*—Before arriving at a final decision in regard to the character of a patient's pulse, it is essential to bear in mind the state of his general health. Too often the features of the pulse are made the basis for conclusions, irrespective of other elements that are necessary to a sound judgment. While it may seem trite and of little importance to assert, "never depend upon the pulse alone for drawing conclusions," yet in practice this remark is sadly needed. Not only is this too limited observation the custom of careless observers, but one frequently notes in text-books the exaggerated importance attached to some peculiarity of the pulse. Thus one may find a pulse unusually small, or exhibiting some irregularity, great rapidity or remarkable slowness, and yet the individuals are in no danger, but are not infrequently frightened and alarmed by the grave prognostications of their medical adviser.

§ 2. *Similarity of pulse in diseased and in healthy hearts.*—On the other hand, judgment dependent entirely upon the pulse may lull suspicions that other considerations would keep awake. Patients at rest may be in danger of rapid or sudden failure of the heart, yet all our methods of clinical examination are entirely at fault in giving us warning. The careful feeling of the pulse may show it to be of good arterial pressure,

without flaw in strength or in rhythm. The examination of the heart may reveal no sign of impending change, nor of its damaged condition. The pulse tracing of a patient with advanced fatty or fibrous degeneration of the heart will present features akin to, if not identical with, those from a healthy individual. The blood pressure measured with the most perfected of modern instruments corresponds to that found in vigorous manhood. Why is this? The following train of reasoning seems to supply the answer: A certain standard of arterial pressure is necessary to the performance of the functions of the organism. This is maintained when the body is at rest by the expenditure of a very small amount of the cardiac energy. A healthy heart does this by exerting a minimum amount of its strength. A damaged heart does this by exerting the bulk, if not the whole, of its strength. Yet in both cases the same amount of energy is spent. It seems therefore, for this reason, that hearts markedly diseased are able to maintain, when at rest, a degree of blood pressure capable of carrying on the functions of life, and to present clinical features resembling those of a healthy heart. The consideration of this view supplies us with a method for the appreciation of many symptoms, namely, by estimating the power of the heart to respond to exertion.

§ 3. *The cardiac field of response.*—In a healthy condition of the organism, the calls made upon the circulation by increase of function are readily responded to. But this response has its limits. It is what I venture to call the limitation of "the field of response" that offers the most valuable aid in judging of the condition of the heart and the whole circulation. There is no standard by which it may be measured outside each individual's own experience. A trained athlete may increase his field of response far beyond a man who takes but little exercise, yet the latter may be as healthy as the former. Each individual unconsciously acquires a fairly definite knowledge of what he can do. In early life the field is a constantly expanding one. In early middle age it begins to contract. But so accustomed does the individual become to its gradual variation, that he readily notes the sudden decrease of the field. The symptoms evoked by its unnatural limitation are various, and their presence in an unusual degree compels the attention of the individual. The most common of these symptoms is a shortness of breath on such exertion as the patient was wont to undertake without discom-



fort. Palpitation of the heart is a frequent symptom. Brain fatigue may be induced so easily as to direct the patient's attention to his condition. Pain of great severity may be induced on very moderate exertion. When a patient presents himself for examination and exhibits, it may be, a pulse with an occasional, or even a frequent, irregularity, or a pulse abnormally quick or abnormally slow, if there be entire absence of any cardiac enlargement and valvular disease, and the patient's field of response is what one would expect for his years, then we can safely assert that there is very little the matter, and for all practical purposes he is a healthy man. On the other hand, a man may be seated in his chair feeling in good health, acute in reasoning and mentally active, his heart exhibits no sign of any derangement, and his pulse seems good in every respect, yet whenever this man walks a hundred yards he is suddenly seized with a spasm of angina pectoris. Or we have to examine a patient in bed. The most careful physical examination of his circulatory system reveals no defect. He has taken no exercise for some time, so what response the heart is capable of making is unknown, but in the course of examination the patient is made to sit up and turn from side to side. After the examination the patient is found with laboured respiration and quickened pulse. We now recognise that in both cases we have to deal with feeble hearts whose only symptom is a field of response so much contracted that we are compelled to take a very grave view of their condition.

§ 4. *The significance of pulse peculiarities.*—While the examination of the pulse alone may not be a reliable guide, yet it often affords valuable information when it is impossible to test the heart's strength. In the course of a febrile complaint where the patient is confined to bed, no opportunity is afforded for ascertaining how his heart can respond to increased effort. The behaviour of the pulse is then the most salient feature. A knowledge of what is to be expected of the pulse under abnormal conditions will help one in anticipating the course of a disease; and here some apparently insignificant feature may be of vital importance. Thus a pulse of seventy or eighty per minute with a temperature of  $103^{\circ}$  occurring in a rheumatic fever may be a symptom of lethal significance. An undue rapidity, or a single irregular beat of the pulse in the course of a pneumonia, may be the first herald of an impending

collapse. It is impossible to lay down rules applicable for all occasions, but when one meets with an uncommon feature it should call for a careful scrutiny of all the other symptoms in order to appreciate its value.

§ 5. *The personal equation in the examination of the pulse.*—

With careful practice the trained finger can become a most sensitive instrument in the examination of the pulse. The recollections of the sensations conveyed to the mind are stored up, and are afterwards utilised for the purpose of comparison. We can only judge of the condition of any pulse by drawing on the impressions left upon our minds by previous experience. As impressions affect different minds in different ways, we cannot expect exact harmony in the accumulated experience of different individuals. As a matter of practice, however, we do find, within certain limits, a degree of unanimity. From this unanimity we are able to classify certain manifestations, which classification forms the basis of our physical diagnosis. Some of these signs are more readily demonstrable, and therefore more universal in their recognition, than others. The rate of the pulse is the most simple of all signs. Variations in rhythm are usually readily recognised. The timing of the various events in a cardiac revolution, such as the sounds of the heart with the carotid pulse can only be acquired by careful practice; but practical unanimity prevails among experienced observers. But when it comes to timing events that rapidly follow one another, a considerable divergence in opinion may result. In like manner practical unanimity may prevail in the recognition of the extremes of blood pressure within the radial artery; but between the extremes there is a wide field, and thus it frequently happens that much variety of opinion may exist as to what constitutes a departure from the normal. As it is impossible for an individual to translate his impressions into language that will convey exactly the same idea to the mind of others, it follows that each individual forms for himself standards based on his own experience. Minds being so differently constituted, a great diversity in standards must result.

§ 6. *Necessity of verification by instrumental methods.*—

There is a liability to error in relying on the impressions alone for the interpretation of the condition of the pulse. Writers speak of the interpretation of their sensations as if they were

describing facts. So long as the impressions conveyed by our sensations are the sole means of diagnosis, too great care cannot be bestowed on thoroughly testing the sensations, and conclusions cannot be drawn too cautiously. It often happens that a biassed observer discovers that which his preconceived notions would lead him to expect. A large bulk of medical literature on the heart consists in elaborating views based on impressions. In consequence of this it frequently happens that certain symptoms have not only been wrongly interpreted, but elaborate theories have been built upon them. While it will always be necessary to depend on impressions for the interpretation of symptoms, yet whenever possible other means of verification should be employed. Instrumental methods are the most helpful, and had they been more commonly employed much useless speculation would have been avoided. Not only this, but a greater stimulus would have been given to their employment, and in consequence much-needed improvement would have taken place. As it is, our instruments are still very imperfect, and it often happens that the interpretation of what the instrument records is at fault. Increased knowledge of instrumental methods will nevertheless elucidate much that is still obscure.



## CHAPTER II

### INSTRUMENTAL METHODS OF EXAMINATION EMPLOYED IN THIS RESEARCH

- § 7. The sphygmograph.
- 8. The polygraph.
- 9. The clinical polygraph.

§ 7. *The sphygmograph.*—It is scarcely necessary to enter into a full account of the construction of the various sphygmographs. They have been so frequently described in text-books that their construction is familiar to all medical men. They are all practically constructed on the same principle. A steel spring is laid upon the radial artery at the wrist in such a manner that while it compresses the artery it does not obliterate it. Attached directly to the spring is a long lever or a series of small levers that magnify the movements of the spring. The free extremity of the lever presses lightly against a strip of paper whose glazed surface has been blackened by the smoke of burning camphor or turpentine, the strip of paper passing at a uniform speed by means of a clock-work arrangement. Although I have worked with several instruments, yet I find the Dudgeon to be the handiest and most useful. Into all sphygmographic records certain errors, due to defects of the instruments, creep. Some of the more elaborate instruments may be more free from defect than the Dudgeon, but so long as one is cautious not to read into the tracings movements evidently due to instrumental errors, the Dudgeon sphygmograph is quite serviceable for a great many practical purposes. Several instruments have time markers attached to them. I have had constructed such an arrangement to the Dudgeon, but the additional weight rendered it more difficult to be kept steadily in place. When desirous of getting a time measure I have generally employed Von Jacquet's



sphygmograph. This instrument is constructed exactly on the same principle as Dudgeon's, only much larger, and with a time movement.

§ 8. *The polygraph.*—There are many perceptible movements due to the circulation that the sphygmograph is unfit to register. Hence when it was required to record these movements, other

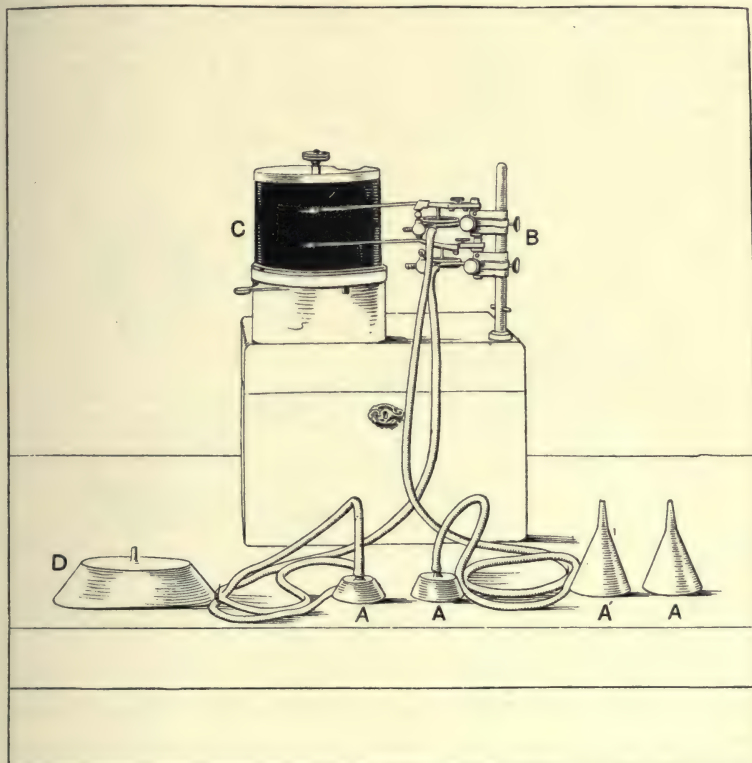


FIG. 1.—Knoll's polygraph with the receivers (A and D). Originally I used small funnels for receivers, but latterly I have used the cup-shaped receivers AA. D is the liver receiver, and is described in the text.

instruments had to be employed. The method most commonly adopted has been by conveying, by means of a tube containing air, the movements to be registered to a tambour, on which there rested a lever. The excursion of the lever is recorded on a revolving drum covered by smoked paper. Two or more tambours being used with their levers placed one above the other, the simultaneous record of different movements can be readily effected (Fig. 1).

The elaborate and bulky apparatus required for this purpose has restricted the employment of this method to such narrow limits, that numerous points of interest in clinical medicine have been either overlooked or misunderstood. In my investigations into the nature of the venous pulse I had at first to use this unwieldy instrument, but its cumbersomeness compelled me to devise a much simpler and more effective apparatus.

§ 9. *The clinical polygraph.*—Inasmuch as the apparatus can be used for taking, at the same time and on the same recording surface, tracings of the radial pulse, with tracings of the apex beat, carotid, venous or liver pulse, or the respiratory movements, and as its size is such as to permit it being carried

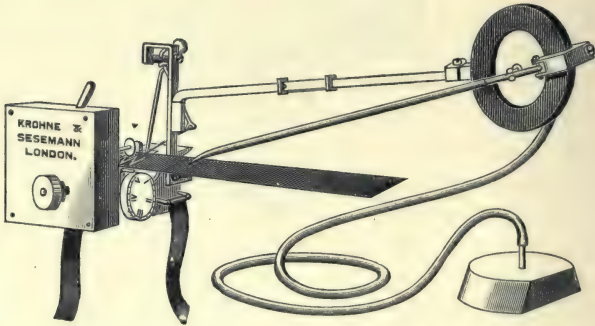


FIG. 2.—The clinical polygraph.

about with the greatest facility, and readily employed in general practice, I have called it the “clinical polygraph” (Fig. 2).

The essential parts of the instrument are a small cup for receiving the impressions of the pulsations, a tube for transmitting the impressions to a tambour and lever, the tambour being affixed to a Dudgeon or Jacquet sphygmograph.

The small cup for receiving the impressions (which will be referred to hereafter as the “receiver”) is simply a small shallow vessel, circular in shape, one and a half inches in diameter and half an inch in depth (A, Fig. 1). The open mouth is applied over the pulsating part in such a manner that its edges are so closely adapted to the skin that no communication is kept up with the outer air. From the roof of the receiver rises a narrow pipe, half an inch in length. To this pipe is fitted an india-rubber tube three to four feet in length, the other end of which

is connected with the tambour. A modification of this receiver is required when tracings of the liver pulse are taken. The "liver receiver" (D, Fig. 1) is larger, being five inches in length, two inches in breadth, and one inch in depth, its open edges slightly curved on their long axis. A small air-hole is made at one end near the roof. In employing the "liver receiver" the position of the lower margin of the liver having been ascertained, the receiver, held in the right hand, is laid lengthwise across the abdomen, its lower edge being two inches below the liver margin, and the end with the air-hole towards the middle line. Steady continuous pressure is applied to the lower margin of the receiver till it presses deeply into the abdomen, and then the upper margin is adapted closely to the skin. In this manner a considerable portion of the lower liver edge is embraced by the receiver. If the forefinger of the right hand be applied over the air-hole, the movements of respiration and liver pulse will be communicated to the lever. If the patient now stops breathing, the liver movements are alone transmitted.

The tambour (Fig. 3) supports a writing lever about six inches in length. From the under surface of the tambour a pipe protrudes, which is connected by the india-rubber tubing with the receiver. Screwed tightly to the bottom of the tambour is a stem B, six and a half inches in length, projecting outward parallel to the under surface of the tambour. Half an inch of the other extremity of the stem is bent almost at right angles, C, and this portion fits into a slot in the upright stem that supports the movable lever of a Dudgeon's sphygmograph (Fig. 2). When the tambour arrangement is adjusted to the sphygmograph, the tambour rests with its movable surface vertical, so that the writing lever moves horizontally. For the

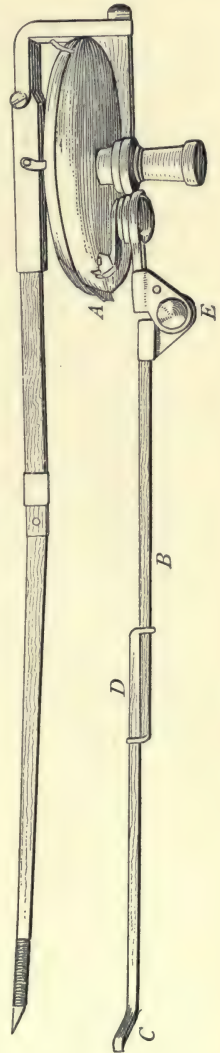


FIG. 3.



purpose of adjusting the point of the writing lever to any desired place on the recording paper the following movements are available:—The point of the lever can be approximated to, or withdrawn from any desired point by means of a sliding arrangement at D (Fig. 3), where the stem consists of two parts clasping one another. The writing point can be made to move in the horizontal direction, so as to write at any desired level on the paper, by means of a joint at E (Fig. 3), which moves stiffly, and retains the position in which it is placed. Finally, the lever can be raised out of reach during the adjustment of the sphygmograph to the pulse, and brought back and allowed to touch the surface of the blackened paper with sufficient delicacy to permit its movements to be accurately recorded, but not restrained by too close pressure, by rotating the tambour at a joint formed where the stem is fixed to the under surface of the tambour. By means of these arrangements the lever can be moved with great facility and accuracy in a vertical and a horizontal direction, as well as made to approach or recede from any given point. By this method any movement can be recorded at the same time, and on the same paper, as the radial sphygmogram. One can make the tambour lever write directly above or below the writing lever of the sphygmograph, or, when the movements are large, a little behind, so that the two levers do not come into contact during their excursions. Upright lines to show the relative time of the two tracings are obtained by allowing the lever to make distinct marks on the paper before starting and after stopping. With a pair of compasses the relative time of any event can be accurately gauged.

Some difficulty may be experienced in the employment of the clinical polygraph, on account of the weight of the tambour tilting the sphygmograph off the radial pulse. If we employ the inelastic band usually supplied with the sphygmograph, this inconvenience may possibly be very serious. I have long ago abandoned the use of the inelastic band (placing no reliance on the pressure supposed to be required to obtain an idea of the arterial pressure), and employ instead an elastic band, tying the instrument to the wrist by a knot. Should any slipping occur, the sphygmograph and tambour can readily be readjusted. It frequently happens that the radial pulse causes such a large excursion that there is no clear space on the paper for the venous or other pulsation. In such a case I either shift the sphygmo-



every point I have described in the venous pulse has been verified by one or other of these ways.

Since I published my description of the venous pulse in 1893,<sup>1</sup> additional and practically conclusive proof of the correctness of my tracings has been demonstrated by Gerhardt.<sup>2</sup> This observer has taken tracings by means of Hürthle's apparatus. His tracings differ from mine mainly in the point of size, but I can distinguish every movement that I have described in his tracings. Evidently he has not had as numerous nor as typical cases to examine as those I have been able to observe.

12 →

## CHAPTER III

### INTERPRETATION OF A SPHYGMOGRAM

- § 10. Definition of a sphygmogram.
11. Relation of the arterial to the ventricular pressure.
12. Nature of the information derived from the study of a sphygmogram.
13. Events occurring during a cardiac revolution revealed by the sphygmogram: (a) the systolic period; (b) the diastolic period.
14. Features of the sphygmogram due to instrumental defect.
15. Conclusions drawn from the study of instrumental defects.
16. The character of the arterial blood pressure as revealed by the sphygmogram.
17. The significance of a well-marked systolic wave.
18. The significance of dicrotism.
19. The significance of hyperdicrotism.
20. The correspondence between tracings from pulses with different arterial pressures.

§ 10. *Definition of a sphygmogram.*—When the spring of a sphygmograph is so accurately adjusted on an artery that it does not obliterate the artery when the arterial pressure is at the lowest, and still slightly compresses the artery when the arterial pressure is at the highest, the spring will oscillate with each variation of pressure within the artery. This oscillation being communicated to the lever and recorded on the tracing paper, gives us a series of wavy outlines which represent the variations of the pressure within the artery. *A sphygmogram may therefore be defined as a diagrammatic representation of the variations of pressure within an artery.* If we knew exactly the amount of pressure exercised by the spring we should be able to obtain the value of each movement. But the possibilities of error are so numerous that it is useless to draw conclusions from the amount of pressure supposed to be exercised.

§ 11. *Relation of the arterial to the ventricular pressure.*—

The arterial pulse being due to the ventricular systole, there will be a correspondence between the ventricular and arterial pressures during that period when the aortic valves are open. In Fig. 8 tracings of the aortic pressure and of the pressure within the ventricle were registered simultaneously. In the tracing of the pressure within the ventricle the diastolic

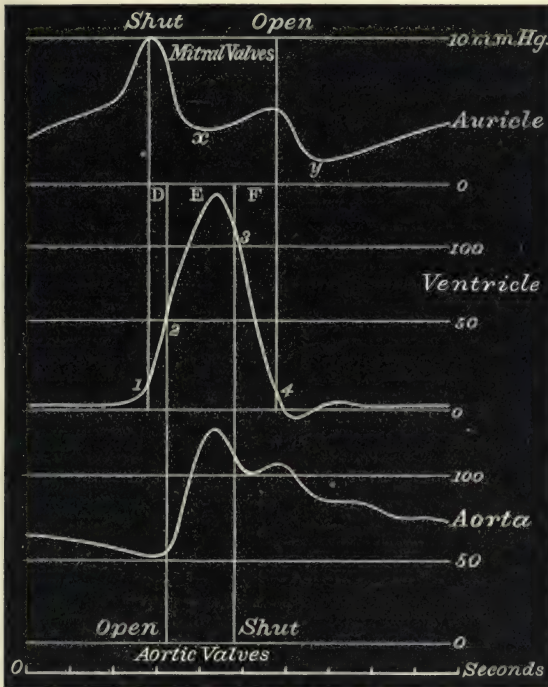


FIG. 8. Semi-diagrammatic representation of the pressure within the auricle, ventricle and aorta, during one cardiac revolution. The duration of increased ventricular pressure (1 to 4) corresponds to the time when the auriculo-ventricular valves are closed, and is divided into three periods: D, the presphygmic period; E, the sphygmic or pulse period; F, the post-sphygmic period. The importance of this division will be described in dealing with the venous pulse. (After Frey.)<sup>3</sup>

period ends at 1. The pressure within the ventricle has risen slightly by the accumulation of blood within the ventricle due to the auricular systole. After 1 the pressure within the ventricle rises suddenly, due to the beginning of the ventricular systole. It is still below the pressure within the aorta, which in the tracing shows a steady fall in pressure till 2. The period 1 to 2 represents the presphygmic interval, *i.e.* the period between the beginning of the ventricular

systole and the opening of the aortic valves. At 2 the pressure within the ventricle has risen higher than that within the aorta, and in consequence the aortic valves open and the two chambers (ventricle and aorta) are in free communication, and their pressures become approximated. While the aortic valves are open the contents of the ventricle are poured into the aorta, and thus the pressure in the arteries becomes greatly increased, which increase in pressure we recognise as the pulse. After a period the pressure within the aorta exceeds that of the ventricle, and when the ventricular pressure falls below the aortic at 3 the aortic valves close. From this period the ventricular and aortic pressures pursue very different courses. The ventricular pressure reaches very quickly the lowest point, while the aortic, with slight interruptions, sinks gradually to the lowest point, but this is much higher than the lowest point of the ventricular pressure.

§ 12. *Nature of the information derived from the study of a sphygmogram.*—In Fig. 8 the tracing of the aortic pressure was taken from within the aorta. The variations of the pressure within the more distal arteries approximate to that of the aorta, being slightly modified by the progress of the waves along the arteries. It is this modified pressure that the sphygmogram represents. But the sphygmogram cannot do this accurately, as the pressure is taken not from within the vessel but by compressing the arterial wall and covering tissues. The sphygmographic method introduces certain modifications. The artery being compressed by a steel spring, sudden changes of the pressure cause excursions of the lever in excess of the actual pressure present. Notwithstanding these defects, which can to a great extent be allowed for, the sphygmogram gives us much useful information. From the examination of a tracing we obtain information on three different points: first, concerning the rate and rhythm of the heart's action; second, concerning certain events occurring in a cardiac revolution; third, concerning the character of the blood pressure within the artery. The rate and rhythm of the heart's action will be discussed in separate sections later.

§ 13. *Events occurring during a cardiac revolution revealed by the sphygmogram: (a) the systolic period.*—If we take a tracing we can divide it into two periods: one (*E*, Fig. 9) during which the aortic valves are open and the ventricle pours its



contents into the aorta, and another (*G*, Fig. 9) during which the aortic valves are closed and the ventricle is in diastole. For

the sake of convenience in describing sphygmograms these two periods will be referred to as the systolic and diastolic periods, although in the space *G* the presphygmic and postsphygmic periods of the ventricular



FIG. 9.—Sphygmogram of the radial pulse. The space *E* is the period of ventricular systole when the aortic valves are open; the space *G* the period of ventricular diastole; *s* is the pulse wave due to the ventricular systole; *n* the aortic notch, *d* the dicrotic wave; and *p* wave due to instrumental defect.

systole are included (Fig. 8). The character of the systolic portion varies very much in different individuals. These variations depend mainly on the amount of resistance offered by the arterial blood pressure to the ventricular systole. In such a tracing as Fig. 9 there is first an abrupt rise, *p*, then a fall followed by a continuation of the wave, *s*, at about the same level. This period is usually described as being divided into two, the abrupt rise being spoken of as the primary or percussion wave, and the latter portion as the tidal or predicrotic wave (the papillary wave and outflow remainder wave of Roy and Adami).<sup>4</sup> This division has led to the idea that these represent two different events in the pulse itself. As a matter of fact the abrupt rise *p* above the level of the wave *s* is due to instrumental defect, and the whole period *E* is occupied by the ventricular pressure forcing blood into the arterial system, and corresponds with the period *E* in Fig. 8. In cases where the arterial pressure is low relatively to the strength of the ventricular systole, these two waves are so blended together that the so-called percussion and tidal waves can no longer be differ-




FIG. 10.—The letters have the same significance as in Fig. 9.

entiated (Fig. 10). The whole of this period, *E*, in the tracing will hereafter be referred to as the systolic period, and the wave, *s*, as the systolic wave, as it represents the period of ventricular

systole when the ventricle and arterial system are in free communication.

(b) *The diastolic period.*—With the closure of the aortic valves the arterial pressure falls rapidly to the bottom of the aortic notch *n* (Figs. 9 and 10). In the tracings this is seen to be at the beginning of the diastolic period. This fall is interrupted by a distinct rise in the pressure represented by the dicrotic wave *d*. There has been a good deal of discussion concerning the cause of the dicrotic wave. The following explanation seems to me the most probable. The semilunar valves are so delicately constructed that they readily respond when the pressure on one side rises above that on the other. As soon as the aortic pressure rises above the ventricular the valves close. At the moment this happens the valves are supported by the hard, contracted ventricular walls. The withdrawal of the support by the sudden relaxation of these walls will tend to produce a negative pressure wave in the arterial system. But this negative wave is stopped by the sudden stretching of the aortic valves, which, on losing their firm support, have now themselves to bear the resistance of the arterial pressure. This sudden checking of the negative wave starts a second positive wave, which is propagated through the arterial system as the dicrotic wave. After the dicrotic wave the arterial pressure curve gradually falls. Occasionally there are slight waves in the fall, but these are of doubtful import.

§ 14. *Features of the sphygmogram due to instrumental defect.*—In the study of sphygmographic tracings one has always to bear in mind that certain features may be due to the instru-

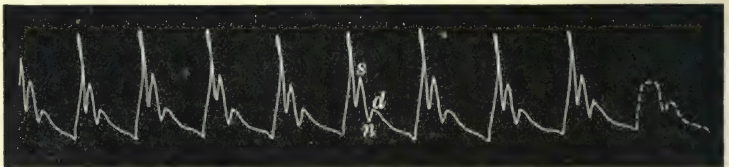


FIG. 11.—A strong beating ventricle has jerked the lever high above the true systolic wave, and the falling lever has made an artificial notch on the systolic wave *s*. The true pulse curve is probably represented in the dotted tracing.

ment itself. Speaking generally these instrumental features occur where there are sudden and forcible changes in the arterial pressure. The most frequent of these is the jerking up of the spring by the systolic wave itself. Then the next most

frequent is the formation of a notch on the tracing of the systolic wave due to the sudden fall of the spring after being jerked high up, as in Fig. 11. Occasionally one finds the aortic notch artificially deepened by the sudden lowering of the pressure, as in Fig. 12.

§ 15. *Conclusions drawn from the study of instrumental defects.*—As instrumental defects occur on account of sudden and forcible changes in the arterial pressure, we can draw certain inferences from their appearance. Thus a sharp rise high above the systolic wave proper indicates a ventricle contracting against an arterial pressure low in relation to the strength of the ventricle. The ventricular systole may be so forcible that the upstroke is uneven at the top, because the lever was not




FIG. 12.—The forcible changes in pressure have exaggerated the height and depth of all the waves.

pushed up by a continuous pressure, but jerked high by a sudden and strong pressure. This is well seen in Fig. 11. Here there was a temperature of  $103^{\circ}$ , with a pulse rate of 76. The pulse was rather firm, but the heart was acting powerfully, stimulated no doubt by the high temperature. Similar instances are often found in certain cases with aortic regurgitation, with atheromatous arteries, and especially with febrile excitation of the heart.

§ 16. *The character of the arterial blood pressure as revealed by the sphygmogram.*—In order fully to appreciate the significance of the change in the sphygmogram due to variation in the arterial pressure, it is best to study individual pulses where changes have been observed whose import can be recognised with certainty. If we take a series of tracings from a suitable case we can watch the gradual rise in the arterial pressure which proceeds *pari passu* with other symptoms that testify to the patient's gradual recovery. This is very manifest in febrile complaints, and illustrations will appear in the section dealing



with the febrile pulse. The following series of tracings was taken from a case of acute dilatation of the heart, where, after the first day, the rise of temperature ceased to complicate the observations. On the first day the observation was made the artery was large and full, and the impact of the pulse on



FIG. 13.

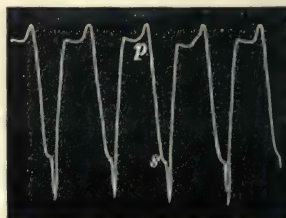


FIG. 14.

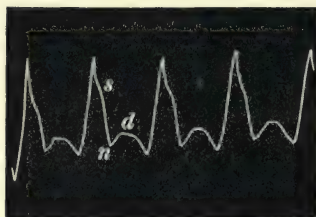


FIG. 15.

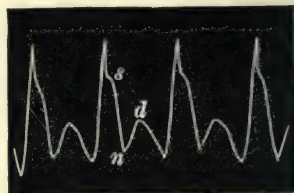


FIG. 16.




FIG. 17.

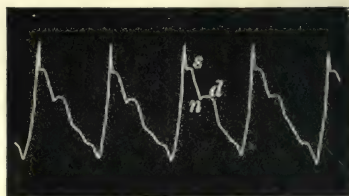


FIG. 18.

The tracings 13-18 show a gradual increase of arterial pressure coincident with diminution of the cardiac dilatation.

the finger sudden, of little strength, quickly subsiding with little resistance to the compressing finger between the beats. In the tracing (Fig. 13) there is an abrupt rise indicating little resistance to the ventricular systole. The lever is jerked high up, and its fall is slightly interrupted by the systolic wave at *s*. After this the fall is continued very low, with such directness that one can infer that the pressure in the arteries has fallen rapidly. The slight wave *d* is the small dicrotic wave, and it is



suddenly cut short by the next pulse beat. This tracing shows a pulse of extremely low pressure.

The tracing (Fig. 14) taken next day shows that the pulse is not so fast, fewer beats appearing in the same space. The lever here is jerked higher and its fall is slightly delayed by the systolic wave. After this delay the fall is continued with suddenness to a great depth, so that the aortic notch falls to the lowest point in the tracing. The lever is again raised by the dirotic wave, which is now more distinct. This tracing represents still a pulse of low arterial pressure, but it is distinctly higher than the pulse in Fig. 13, inasmuch as there is now a well-marked dirotic wave. The tracings (Figs. 15 and 16) show a still greater increase in the arterial pressure, inasmuch as now the dirotic notch no longer forms the lowest point in the tracing. The gradual rise of the aortic notch is readily noted in the last two tracings of the series (Figs. 17 and 18). It will be realised from the study of these tracings that a dirotic pulse, even when the dirotic wave is readily perceptible to the finger, is often a reassuring sign as to the condition of the pulse. It implies a pulse of low pressure indeed, but still a pulse of fair working amount of arterial pressure. In Fig. 17 there is no sign of any interruption of the falling lever due to the systolic wave; nevertheless this shows a better pulse than the three preceding sphygmograms, inasmuch as the aortic notch is much higher in this pulse tracing than in the others. This illustrates the fact that the height of the aortic notch is a more certain guide to the arterial pressure than the character of the systolic wave.

Fig 18. was from the same patient when he was restored to comparative health. Here we have a ventricle operating against a pressure which it readily overcomes, as shown by the upstroke being high above the systolic wave *s*. The evacuation of the ventricular contents is met by some resistance as the falling lever is delayed for a brief period by the systolic wave *s*. After the systolic wave there is only a short fall when it is interrupted by the dirotic wave. The aortic notch *n* is scarcely evident, because the dirotic wave is so slight that it forms at times a mere delay in the fall of the lever. The dirotic wave is always small when the notch is so high above the base line. The chief points to be noted in this series of tracings are: first, that the increase in size of the dirotic wave and the higher situation in the tracing of the aortic notch indicate an increase in the arterial pressure;

second, that with the restoration of the arterial pressure to the normal, the situation of the aortic notch rises, but that the size of the dicrotic wave diminishes. These changes in the pulse were coincident not only with the marked improvement in the patient's condition, but with the demonstrable reduction of the greatly increased venous pressure. This case illustrates in so striking a manner the connection of the arterial with the venous pressure that I have recorded it at some length in the chapter on acute dilatation of the heart (Chap. XXIV. § 209).

§ 17. *The significance of a well-marked systolic wave.*—A well-marked systolic wave implies that the resistance of the arterial pressure opposed to the ventricle is considerable, but it does not distinguish between a strong ventricle opposed to high arterial pressure, or a weak ventricle opposed to an arterial pressure actually low, but high in relation to the strength of the ventricle. Therefore, though the presence of a well-marked systolic wave may indicate a high arterial pressure, it is not necessarily an evidence of that condition. Thus in Fig. 19




FIG. 19.—Asthenic type of pulse with well-marked systolic wave *s*, and only a faint indication of the dicrotic wave *d*.

the systolic wave is very distinct. Nevertheless the pulse here was extremely soft and compressible. It will be noted, however, that there is only a very small dicrotic wave, and it is very low down. One therefore places more reliance on the position of the aortic notch and character of the dicrotic wave than on the character of the systolic wave, for the evidence of the arterial pressure in the sphygmogram.

§ 18. *The significance of dicrotism.*—With extreme lowering of the pressure the dicrotic wave becomes scarcely perceptible, as illustrated in Fig. 13. Its absence in certain cases is an ominous sign, as at the beginning of pneumonia. The presence of a dicrotic wave is evidence of the retention of an important amount of arterial pressure. Its relation to the arterial pressure may be illustrated in several ways. Already, in Figs. 13 to 18,

I have shown this, and it will be again demonstrated in dealing with the febrile pulse. Here I shall demonstrate it in two curious ways. In the one case the sphygmograms illustrate the increase in the size of the dicrotic wave, with increase in the arterial pressure, and in the other they illustrate the increase in the size of the dicrotic wave, with lowering of the arterial pressure. A male aged thirty-six was being examined, when he fainted. As soon as the pulse became perceptible I got Fig. 20.



FIG. 20.—Pulse of extremely low arterial pressure, from a man unconscious during an attack of syncope.

He was still unconscious and very pale. Five minutes later he had recovered consciousness, and a free perspiration was breaking out, and I obtained the tracing Fig. 21. The whole pulse beat

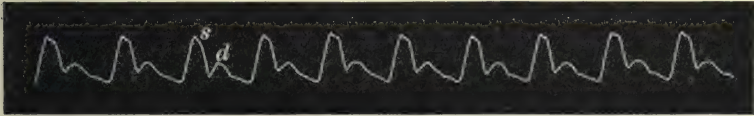


FIG. 21.—Pulse of low arterial pressure from the same patient as Fig. 20. Consciousness was returning, and there is now shown a marked rise in the systolic and dicrotic waves.

is increased in size, and the dicrotic wave, which is scarcely perceptible in Fig. 20, is a well-marked feature in Fig. 21. This illustrates the increase in the size of the dicrotic wave, with increase in the arterial pressure.

Fig. 22 is the tracing of an irregular pulse, where the ventricle has contracted with unequal force. When the ventricular contraction was strong the systolic wave (*s*) is well marked,

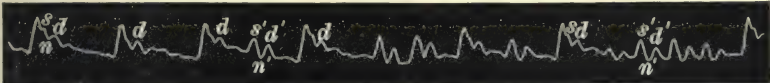


FIG. 22.—Tracing of an irregular pulse showing a small dicrotic wave, *d*, after a full ventricular systolic wave, *s*, when the arterial pressure is high, and a large dicrotic wave, *d'*, after an imperfect systolic wave, *s'*, when the arterial pressure is low.

and the aortic notch (*n*) small and high above the base line, indicating a considerable rise in arterial pressure. When the ventricular contraction was weak the systolic wave *s'* is low, the dicrotic notch *n'* is deep, reaching often to the base line, while



the dicrotic wave  $d'$  is much increased in size, indicating a remarkable fall in the arterial pressure during the irregular period of the heart's action.

§ 19. *The significance of hyperdicrotism.*—When the aortic notch,  $n$ , forms the lowest part of the tracing, as in Fig. 23, the




FIG. 23.—Tracing of a hyperdicrotic pulse.

pulse is spoken of as hyperdicrotic. This is not of necessity due to any extreme lowering of the blood pressure, for the rise after the aortic notch is due to the dicrotic wave, which, as I have said, is an evidence of a fair amount of arterial pressure. Hyperdicrotism is, as a rule, merely an evidence of a quickening of the pulse. The increase of pulse rate occurs mainly by the shortening of the diastolic period. When this shortening goes so far as to cut the descending limb of the dicrotic wave before it has reached the level of the aortic notch, then we have what is called hyperdicrotism of the pulse. It is therefore, properly speaking, not due to an increase of the dicrotism, but to a quickening of the pulse rate. That this is the correct interpretation is evident from the study of Fig. 24. In this pulse the speed varied considerably, occasional slow beats occurring, with beats of great rapidity. When there is a slow beat it will be noted that the pulse is markedly dicrotic, the tracing sometimes falling below the aortic notch at the end of diastole, as after the 14th beat of the tracing. In the first beat of the tracing the arterial pressure, before

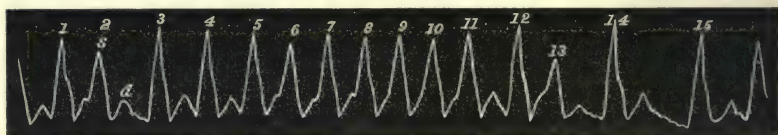


FIG. 24.—Tracing of an irregular pulse, illustrating the production of hyperdicrotism by increase of pulse rate.

the beginning of the beat, is nearly the same level as the aortic notch. In the following beats there is gradual increase



in the rapidity of the pulse. The systolic period remains constant, while the diastolic gradually shortens. This shortening is entirely at the expense of the descending limb of the dicrotic wave *d*, so that the hyperdicrotism becomes more and more marked, till, after the dicrotic wave of the 5th, 6th, and 7th beats, there is only a slight interruption indicating the separation of this dicrotic wave from the succeeding systolic wave. Even this is not evident before the 9th and 10th beats, for the systolic wave takes place before the summit of the dicrotic wave has been reached, so that we have two monocrotic pulse beats in the 9th and 10th of this tracing. The base line all through is at one level here, and therefore the increase in the hyperdicrotism cannot be due to the diminution of the arterial pressure, but is demonstrably due to the increase in the rate of the pulse.

§ 20. *The correspondence between tracings from pulses with different arterial pressures.*—One is often struck by the fact that tracings taken from an individual with a strong and healthy heart are apparently identical in character with those taken from an individual with a markedly weakened heart. Two reasons may account for this. Suppose that when both individuals are at rest an equal amount of arterial pressure is necessary to carry on the functions of life. In the one case the strong heart produces this, exerting only a portion of its strength; in the other case the weak heart is contracting with nearly its full amount of vigour. The result, so far as the arterial pressure goes, is the same, and as a consequence the sphygmograms resemble one another. The real difference between the two cases can only be found out when both hearts are exposed to a strain calling forth increased effort, and for this the sphygmograph is not usually serviceable. The other reason for the similarity between the tracings taken from individuals of different heart powers is, that the sphygmogram only represents variations in pressure. Thus a strong heart acting against a high arterial pressure will give a curve similar to a weak heart acting against a pressure which, though actually low, is high in relation to the strength of the ventricle. In other words, the weak ventricle has as much difficulty in overcoming the low arterial pressure as the strong ventricle has in overcoming

the high pressure. Though the character of the curves may be similar, the actual pressure exerted by the sphygmograph will no doubt be different. So far it has been impossible to get a reliable estimate of the pressure exerted by the sphygmograph.

## CHAPTER IV

### THE MOVEMENTS OF THE HEART IN HEALTH AND IN DISEASE

- § 21. The standards for recognising the events in a cardiac revolution.
- 22. Conditions of the chest wall permitting the recognition of certain movements of the heart.
- 23. The nature of the movements.
- 24. The apex beat.
- 25. Interpretation of a tracing of an apex beat due to the systole of the left ventricle.
- 26. Retraction of yielding structures in the neighbourhood of the heart during ventricular systole.
- 27. Liver movement due to cardiac aspiration.
- 28. Epigastric pulsation.
- 29. The apex beat due to the right ventricle.
- 30. Change of the apex beat due to the left ventricle to one due to the right ventricle.
- 31. Significance of the inverted cardiogram.
- 32. Alteration of the apex beat due to retraction of the lung.
- 33. The shock due to the ventricular systole.
- 34. Clinical significance of the cardiogram.

§ 21. *The standards for recognising the events in a cardiac revolution.*—Because of the easy recognition and determined place in the cardiac cycle of the carotid and radial pulses, these pulses form the most certain standards for finding out the place of other movements in a cardiac revolution. In describing many tracings frequent references will have to be made to these standards, and more particularly to that period during which the semilunar valves are open. This period is always indicated by the space *E*. When it appears in the radial tracing it corresponds to the effects of the ventricular systole upon the radial pulse—that is to say to the actual pulse wave, and not to the actual time of the occurrence of the ventricular systole. On account of the distance the pulse wave has

to travel, the period *E* will be later in the radial than the same period in the apex or carotid tracings. Thus in Fig. 41 the space *E* represents the duration of the ventricular systole as it affects the apex beat and the radial pulses, while the actual time of the occurrence of the systole is at *o*.

§ 22. *Conditions of the chest wall permitting the recognition of certain movements of the heart.*—The movements of the heart in a healthy person are usually so obscured by the lungs that only very little change is discernible in the external chest wall. In many cases the lungs are so voluminous, or the chest wall so fat and thick, that no movement can be detected. But when a large surface of the heart is directly exposed to a thin chest wall, either from increase in the size of the heart, the lung being displaced, or from retraction of the lung, as in certain cases of disease of the left lung, a series of movements of the chest wall due to the contraction and expansion of the heart can be recognised. The movements thus discernible are not the same in all cases, but depend on which part of the heart's surface comes in contact with the chest wall, and other yielding structures in the immediate neighbourhood of the heart. These movements take place so rapidly that it is difficult to interpret their significance by the unaided senses. As many writers on this subject have drawn elaborate, but nevertheless erroneous, conclusions from observations based entirely on the evidence of their senses, it seems to me that only accurate observations by the graphic method can furnish a clear and definite explanation.

§ 23. *The nature of the movements.*—The movements of the heart that are most readily recognised are those connected with the systole and diastole of the ventricles. Movements due to the auricles are so obscured by the unceasing larger and more vigorous movements of the ventricle that it is doubtful if they are ever capable of recognition. The movements most readily recognised are: first, the apex beat; second, the filling of the ventricles; third, the emptying of the ventricles; and fourth, the shock communicated by the sudden hardening of the ventricular walls as they pass into systole.

§ 24. *The apex beat.*—The chief movement, and the one which is usually most apparent, is that caused by the forcible outward projection of the apex of the heart during the ventricular systole—the apex beat. This is generally described as “the lowest and outermost point of the heart's impulse which strikes



against the chest wall." It is usually felt in the fifth left interspace, immediately inside the nipple line in healthy adults. It may, however, be situated in the fourth interspace, and outside the nipple line in children and in some adults. In disease of the heart it alters its situation with the increasing size of the heart. This forward thrust only occurs when the left ventricle is in contact with the chest. As will be shown later, a movement of another description occurs when the right ventricle constitutes the so-called apex beat. That the apex beat due to the left ventricle is a distinct displacement of the heart forward can be recognised by the senses of touch and sight.

During the whole time occupied by the systole of the ventricle the apex is usually kept projecting into the interspace, so that in

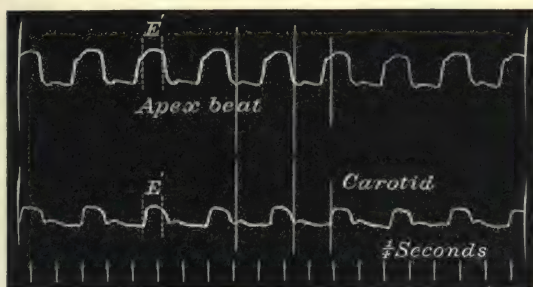


FIG. 25.—Simultaneous tracings of the apex beat and the carotid pulse, showing the "systolic plateau" in the cardiogram during the outflow from the ventricle (*E'*).

such a tracing as Fig. 25, the lever taking the tracing is kept raised during the whole time of the outflow from the ventricle (space *E'*). If the left ventricle is much hypertrophied, the same movement can sometimes be detected in two or three interspaces. If the interspaces be fairly open and the chest wall thin, and the tip of the finger be thrust into the third or fourth interspace near the sternum, the right ventricle can be felt hardening, and remaining thus hardened in contact with the finger during the whole period of the ventricular systole. It cannot, however, be averred that in this case there is a forward thrust. The heart here is always in contact with the chest wall, and the finger pushed into the interspace during the diastole in all likelihood impinges against the lax ventricular wall. As soon as the ventricle hardens, the finger recognises this hardening as something pushing against it. This sensation of a thrust is

sometimes actually synchronous with an indrawing of the soft structures filling up the interspace (Fig. 30).

§ 25. *Interpretation of a tracing of an apex beat due to the systole of the left ventricle.*—A tracing of the apex beat or cardiogram is a diagrammatic representation of: (a) the forward movement of the apex of the heart while the ventricular muscle is beginning to contract (space *D*, Fig. 26); (b) the retention of the apex beat against the chest wall while the ventricles are emptying (space *E*, Fig. 26); (c) the backward movement of the apex of the heart while the ventricular muscle is relaxing (space *F*, Fig. 26); (d) and the gradual swelling of the ventricle during diastole (space *G*, Fig. 26).

(a) *The period of commencing contraction of the ventricular muscle* (space *D*, Fig. 26).—(This period corresponds to the

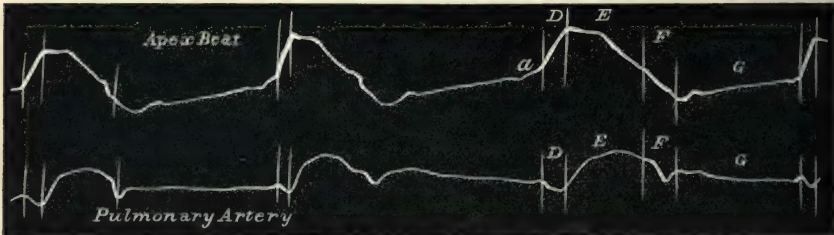


FIG. 26.—Simultaneous tracings of the apex beat and of the pulsation in the pulmonary artery. The letters represent the time during which the ventricle is passing into systole (*D*), emptying (*E*), relaxing (*F*), filling (*G*). *a* represents the small wave due to the auricular systole. While this tracing was being taken the cylinder was rapidly rotated. The letters *D*, *E*, *F* have reference to the same periods in the cardiac revolution as in Fig. 8.

presphygmie interval in Fig. 8.) During this period the pressure within the ventricle is rapidly rising. The auriculo-ventricular valves close as soon as the pressure within the ventricle rises above that in the auricle. As soon as the pressure in the ventricle rises above that in the aorta and pulmonary artery, the semilunar valves open. This occurs at the end of the period *D*, Fig. 26, and is usually indicated by the abrupt termination of the upstroke.

In Fig. 26 simultaneous tracings were taken of the pulsation in the pulmonary artery and of the apex beat. As the beginning of the pulse in the pulmonary artery indicates the opening of the semilunar valves, so it is found that the end of the period *D* corresponds exactly with the beginning of the pulsation of the pulmonary artery. When this figure was taken the cylinder was rotated rapidly in order to separate the events as widely

as possible. When the cylinder rotates at a slower rate, this period is represented by an almost perpendicular line (Fig. 27).

It will be noted that the termination of the upstroke corresponds exactly with the beginning of the outflow of the ventricle into the artery. These tracings were taken from a lad suffering from phthisis of the left apex. The lung had retracted from the heart, and through the thin chest walls the various movements of the heart could easily be observed. In the second left interspace there was a marked pulsation. Tracings of the pulsation, taken at the same time as the carotid pulse, left no doubt as to its being caused by the

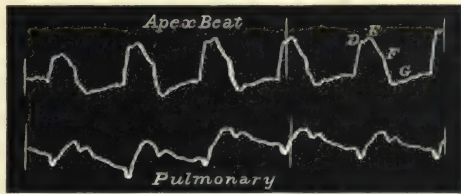


FIG. 27.—Simultaneous tracings of the apex beat and of the pulsation in the pulmonary artery. The letters have the same significance as those in Fig. 26.

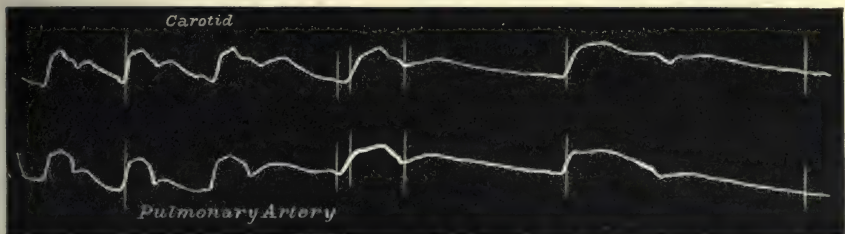


FIG. 28.—Simultaneous tracings of the pulses of the carotid and pulmonary arteries.

pulmonary artery (Fig. 28). It will be noticed that the carotid pulse appears just a very little later than the pulmonary. Here also after a few beats the cylinder was rapidly rotated with the hand to separate more widely the different events.

(b) *The period of ventricular outflow* (space *E*, Fig. 26).—(This period corresponds with the sphygmic or pulse interval in Fig. 8.) When the pressure in the ventricles exceeds that in the aorta and pulmonary artery, the semilunar valves open, and the blood flows out from the ventricles. During this period the apex is usually kept stationary, protruding against the chest wall, and in many tracings (as in Fig. 29) it is shown by a fairly level line—the systolic “plateau.” In place of a flattened top representing the period of ventricular outflow, the tracing may continue to rise (as in Fig. 25), indicating that the ventricle



is still slightly shifting. On the other hand, the tracing sometimes rapidly descends (Figs. 26 and 27). I cannot but think that this is due to the shrinking of the ventricle, during its systole, away from the interspace. I shall show later on that this shrinking can be demonstrated in various places, and I have found evidence of it immediately under a diffuse apex beat. The movement producing the apex beat is really a displacement of the heart forward, and while the heart is thus displaced the ventricles shrink in their emptying. If the lower edge of the apex just impinges in the interspace, it is possible that at the beginning of systole the apex is in the interspace, but as the shrinkage goes on it partially recedes. The termination of the ventricular outflow is occasioned by the pressure in the aorta becoming higher than that in the ventricle. In consequence of this the semilunar valves close, the ventricular muscle relaxes, and the systolic period terminates at the beginning of a sudden descent in the cardiogram.

(c) *The period of relaxation of the ventricular muscle* (space *F*, Fig. 26).—(This period corresponds with the postsphygmic interval *F* in Fig. 8.) With the relaxation of the ventricular muscle the apex retreats from the chest wall, as is indicated by the slanting downstroke in the tracing. Where the tracing is falling during the ventricular outflow (*E*), the beginning of this period (*F*) is indicated by a more rapid descent (Figs. 26 and 27). During this period the ventricular pressure is rapidly falling until the stage of complete relaxation, when the pressure inside the ventricles becomes lower than that inside the auricles. When this occurs the auriculo-ventricular valves open. The apex then has retreated its farthest from the chest wall, and in the tracing the lowest point is reached.

(d) *The period of filling of the ventricles* (space *G*, Fig. 26).—Following upon the opening of the auriculo-ventricular valves, the blood flows from the auricles into the ventricles. As the ventricles distend the heart pushes against the intercostal space and slightly raises the lever. This period is marked in the tracing by a gradual ascent. Frequently, however, the heart fails to affect the tissues in the interspace during this period, so that no indication of the filling of the ventricles is obtained; therefore, in such a tracing as Fig. 25, and many others given in the text, the whole of this period may be considered as a blank, so far as the heart is concerned. In tracings where this period



is represented there is occasionally found an abrupt though slight rise immediately preceding the beginning of the ventricular systole ( $\alpha$ , Figs. 26 and 29). This is due to a sudden increase in the contents of the ventricle by the contraction of the auricle.



FIG. 29.—Simultaneous tracings of the apex beat and of the radial pulse, showing the “systolic plateau” and the small wave ( $\alpha$ ) due to the auricular systole. The third beat in the apex tracing is obliterated by the movement of inspiration.

§ 26. *Retraction of yielding structures in the neighbourhood of the heart during the ventricular systole.*—When the ventricles expel their contents they must of necessity shrink. This shrinkage occurs abruptly, and with considerable force. The yielding tissues in the neighbourhood of the heart are dragged upon, and evidence of this dragging can be obtained from a variety of sources. John Hunter<sup>5</sup> originated the idea that the systole of the ventricles would have a tendency to produce a vacuum, and thus expedite the flow of the venous blood into the chest. Evidence of this “cardiac aspiration” affecting the lungs has been obtained by a number of observers. The observations of Mosso<sup>6</sup> and of Delépine<sup>7</sup> of the movements of the column of air in the respiratory passages, due to the cardiac aspiration, correspond exactly with these tracings obtained from the præcoridium (Fig. 30), from under the liver (Figs. 31, 32, and 33), and from the epigastrium (Figs. 34 and 35).




FIG. 30.—Simultaneous tracings of the heart movements (upper tracing) and of the radial pulse. The first part of the upper tracing was taken from the apex beat in the fourth interspace immediately outside the nipple, while the latter part was taken in the same interspace near the left border of the sternum. In the first part the cardiogram shows a “systolic plateau” during the ventricular outflow ( $E$ ), in the other part the cardiogram is inverted, *i.e.* there is a depression during this period ( $E$ ).

The tracing Fig. 30 demonstrates this drawing in of the

tissues in the intercostal spaces over the heart. It was obtained from a boy aged fourteen. The apex beat was well marked in the fourth interspace outside the nipple. At the same time that the apex was thrust outwards the skin and subcutaneous tissues over the same interspace inside the nipple were drawn in. In Fig. 30 the tracings of the apex beat were taken simultaneously with the radial pulse for four beats. The clock-work was then stopped, and the receiver, which had been applied over the apex, was placed over the præcordium inside the nipple, and the "inverted cardiogram" of the last portion was obtained. The space *E* represents the duration of the outflow from the ventricle; and this period, which in the apex tracing shows a flattened elevation, shows a great depression in that obtained from the front of the heart. The ascending limb of the apex tracing corresponds to the period during which the ventricle is contracting (space *D*, Fig. 26). This period in the inverted cardiogram is represented by a slight rise, due to the shock of the contracting ventricle. No blood as yet has escaped from the ventricle. As soon as the semilunar valves open the blood rushes out of the ventricle, the ventricles diminish in size and suck in the yielding tissues of the interspace, and cause the great fall, as represented in the inverted cardiogram (space *E*, in the latter half of Fig. 30).




FIG. 31.—Simultaneous tracings of the apex beat and of the movement of the liver. When the ventricle empties the liver is drawn up, and this causes the fall in the tracing.

§ 27. *Liver movements due to cardiac aspiration.*—Not only can this aspiration be demonstrated as affecting the pliable tissues immediately in contact with the heart, but in suitable cases it can be shown to produce a distinct excursion of the liver. All writers referring to this movement of the liver speak of it as a downward thrust during the ventricular systole. Careful tracings demonstrate that this movement is quite of the opposite nature—it is a drawing up of the liver during the ventricular systole. In Figs. 31 and 32 the apex beat is taken at the same time as the movement of the liver.

The apparatus taking the liver movement being applied to the under surface of the organ, a retraction of the liver upwards corresponds with a fall in the tracing and *vice versa*. It will be seen that the movement of the liver upwards takes place during the ventricular systole, while the downward movement is due to the diastolic filling of the ventricle. In Fig. 33 the movement of the liver is recorded at the same time as the carotid pulse. It is seen that as

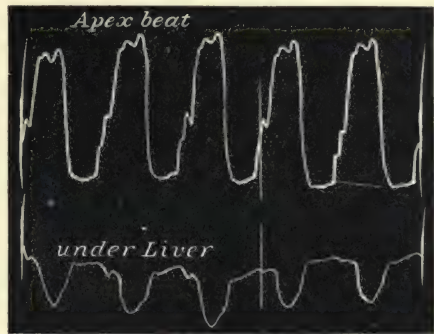


FIG. 32.—Shows the same as Fig. 31.

soon as the carotid pulse appears, the liver is drawn up, and remains there until the end of the ventricular systole, after which the liver gradually falls down. I do not mean that the

excursion of the liver is one of considerable extent, but the movement is so great as to be obvious to the palpating hand. It is distinct from a pulsation of the liver, which is a periodic swelling of the liver, while this is a displacement of the liver *en masse*.

§ 28. *Epigastric pulsation*.—The causes which may produce a pulsation in the epigastrium are: (a) a dilated right heart; (b) a hypertrophied left ventricle; (c) the abdominal aorta; and




FIG. 33.—Simultaneous tracing of the carotid pulse and liver movement. With the appearance of the carotid pulse there is a sudden fall of the liver tracing due to the liver being drawn upwards by the emptying ventricles.

(d) an aneurysm of the abdominal aorta.

In the later stages of typhoid fever and other exhausting diseases, epigastric pulsation is an ominous sign of cardiac enfeeblement. The movement consists of an alternate swelling and retraction of the epigastrium. It is invariably assumed that this swelling or pulsation is due to the right ventricular systole, and that it is of the same nature as the outward protrusion con-



stituting the apex beat. If this form of epigastric pulsation is carefully timed with the carotid pulse, it will be found that the epigastric pulse, protrusion, or swelling precedes the carotid pulse, and that the retraction of the epigastrium corresponds in time to the carotid pulsation. The apex beat is rarely available in these cases, on account of the right heart pushing the left ventricle backwards. In the tracings of the epigastric pulse (Fig. 34) the



FIG. 34.—Simultaneous tracing of the epigastric pulse, due to a dilated right heart, and of the radial pulse. The epigastric pulse shows a retraction during the ventricular systole (*E*), and a protrusion during the filling of the ventricle.

radial pulse is taken as the standard of time. The time occupied by the pulse travelling from the heart to the wrist being allowed for, it will be found that the great fall in the epigastric pulse corresponds exactly with the ventricular systole (*E*).

The patient from whom this tracing was taken was dying from pernicious anæmia. At the *post-mortem* examination a needle pushed through the epigastrium, at the place where the tracing was obtained, was found to have penetrated the right ventricle.

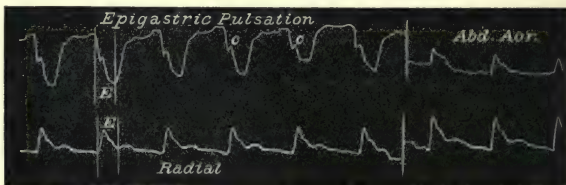


FIG. 35.—Shows the same features as Fig. 34, with the exception of the small wave (*c*) occasioned by the shock communicated to the epigastrium by the abdominal aortic pulse. A few beats of the abdominal aorta are also given.

In Fig. 35 a similar tracing is given, except that there is a slight interruption at *c*, on the line of descent. This will be found to correspond exactly to the time of the abdominal aorta, taken from the middle of the abdomen, a few beats of which are also given. This small wave (*c*) is due to the impulse imparted to the tissues by the pulse of the underlying aorta. Epigastric



pulsation, due to hypertrophied left ventricle, has the same character as an apex beat (Fig. 36). Epigastric pulsation, due

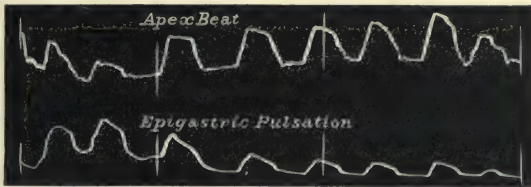


FIG. 36.—Simultaneous tracings of the apex beat and of the epigastric pulsation, due to a hypertrophied left ventricle.

to the abdominal aorta, presents quite a different character from that due to a dilated right ventricle, as shown in Fig. 37, where the pulse corresponds in character and time with the radial pulse. An epigastric pulsation due to an aneurysm of the abdominal aorta would assume the time and character of the abdominal aortic pulse (Fig. 37).

§ 29. *The apex beat due to the right ventricle.*

—Accepting the usual clinical definition of the

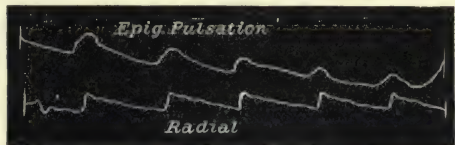

FIG. 37.—Simultaneous tracings of the epigastric pulse, due to the abdominal aorta, and of the radial pulse.

apex beat “being the lowest and outermost part of the heart’s impulse,” a totally different form of beat is found when the right ventricle causes this movement. In certain cases of dilatation of the right heart, nearly the whole anterior aspect of the heart is composed of the right auricle and ventricle, the left ventricle forming but a mere strip of the border. This portion of the left ventricle is situated so far back that it is covered by the lungs and does not reach the chest wall. Hence it is that “the lowest and outermost part of the heart” in contact with the chest wall is the right ventricle. The nature of the apex beat corresponds exactly with those features characteristic of the liver movements of the epigastric pulse, due to enlarged right heart, and of the inverted cardiogram in Fig. 30. In place of the outward thrust during the systole, as in the apex beat due to the left ventricle, there is an indrawing of the tissues.

Fig. 38. was taken from a youth, aged eighteen, with simple dilatation of the heart, and free from valvular disease. There was marked pulsation of the jugular veins, a few beats of which are

given. The apex tracing shows a great depression during the period of ventricular outflow (*E*). This period is immediately preceded by an abrupt rise due to the shock communicated to the chest by the sudden hardening of the ventricular wall. Although corresponding with the period *D* (Figs. 26 and 27) in the left ventricular apex tracings, I am inclined to think that the rise here is an instrumental fault, due to the violent shock communicated by the sudden and forcible ventricular contraction. This period is preceded by a small wave (*a*) in the tracing identical with the similar rise in Figs. 26 and 29 of the left ventricular apex beat. It is due in this case, as in those, to the distension of the ventricle by the auricular systole. It occupies exactly the same period in the cardiac revolution

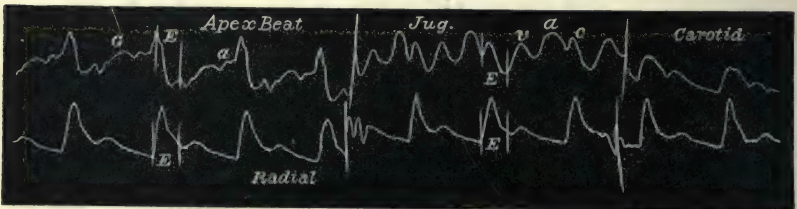


FIG. 38.—Tracings of the apex beat, jugular pulse, and carotid pulse (upper tracing), taken at the same time as the radial. The apex tracing is due to the right ventricle, and shows a depression (*E*) during the ventricular outflow. The sharp elevation preceding *E* is caused by the shock of the contracting ventricles. This is preceded by a small wave (*a*), which is due to the contracting auricle distending the ventricle, and corresponds in time exactly with the wave (*a*) in the jugular pulse, which is due to the contracting auricle sending a wave of blood back into the veins.

as the wave (*a*) in the venous pulse, and is produced by the same cause. The space (*E*) in all the tracings represents the period of ventricular outflow as it affects the different pulses. One can, therefore, readily and with certainty refer the different events to their causes. Thus we know that the wave of contraction arising in the auricle passes on to the ventricle, that between the auricular outflow and the ventricular outflow a period, the presphygmic (*D*, Fig. 26), exists, during which the ventricle is contracting and raising its pressure until it opens the semilunar valves. Thus the presphygmic period in the apex tracing exactly corresponds to the period from the summit of the wave (*a*) in the venous pulse due to the auricular systole, and to the wave (*c*) due to the carotid pulse. A few beats of the carotid are given, which can be taken as a standard of time to verify all these points. The period (*G*) is due to the filling of the ventricle.

§ 30. *Change of the apex beat due to the left ventricle to one due to the right ventricle.*—One can often demonstrate in individual cases the change of the apex beat, from one characteristic of the left ventricle to one characteristic of the right, during a period of heart failure, and the return of the apex beat to one characteristic of the left ventricle when compensation is re-established. Cases of heart failure from mitral stenosis afford the most typical examples.

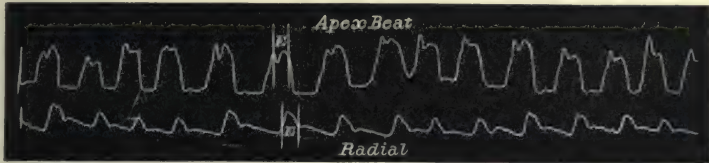

FIG. 39.—Simultaneous tracings of the apex beat and radial pulse from an old-standing case of mitral stenosis. The apex beat is due to the left ventricle, the period of ventricular outflow (*E*) being characterised by a sustained elevation.

Fig. 39 is a tracing of the apex beat and the radial pulse taken simultaneously from a patient suffering from mitral stenosis on 2nd of March 1893, the apex beat being in the sixth interspace. On 12th of February 1895 the patient was suffering from extreme heart failure, the apex beat being in the seventh interspace (Fig. 40). In Fig. 39 it will be noted that the systolic period (*E*) is marked by sustained elevation, char-

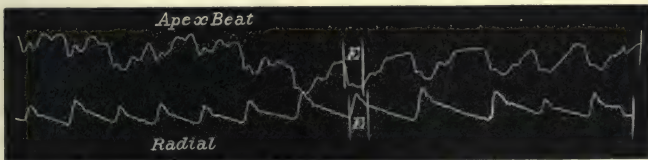

FIG. 40.—Simultaneous tracings of the apex beat and radial pulse, from the same patient as gave Fig. 39, during a period of extreme heart failure. The period of ventricular outflow (*E*) is now characterised by a fall in the tracing, and is therefore due to the right ventricle. The pulse is very irregular in rhythm.

acteristic of the apex beat due to the left ventricle. In Fig. 40, on the other hand, the systolic period (*E*) is marked by great depression.

On recovery from this attack of heart failure the apex beat was felt in the sixth interspace, and the outward protrusion had again returned to the systolic period (Fig. 41).

In other words, with restored compensation the right heart had become less dilated and had receded so far that the left



ventricle again came forward to the front of the chest, so that its apex again became perceptible. It will be noted that the



FIG. 41.—Simultaneous tracings of the apex beat and radial pulse, from the same patient as gave Figs. 39 and 40. During the ventricular systole (*E*) there is now a distinct elevation of the apex tracing.

systolic period (*E*) in Fig. 41 presents a sustained elevation corresponding to the same elevation in Fig. 39, but in striking contrast to the great depression in Fig. 40.

§ 31. *Significance of the inverted cardiogram.*—It is asserted in text-books that an indrawing of the apex during systole of the ventricles is a diagnostic sign of adherent pericardium. I have had several cases where I have got at one time tracings of the apex beat due to the left ventricle, and at other times tracings due to the right ventricle, with indrawing during systole; and at the *post-mortem* examination there has never been found any signs of adherent pericardium.

The fact that “the lowest and outermost point of the heart’s impulse which strikes against the chest wall” may be due to the right ventricle should be borne in mind. Whenever that occurs, the cardiogram is an inverted one—that is to say, there is a shrinking of the heart from the chest wall during the systole and a protrusion during the diastole of the ventricles. This is not always recognisable at first sight. Being somewhat familiar with the form of various apex beat curves, I had no difficulty in recognising Fig. 41 as being due to the left ventricle.

But when from another patient I took Fig. 42 I certainly was misled in the first instance. The abrupt rise and fall bear so close a resemblance to Fig. 41 that I put it down as an apex beat curve due to the left ventricle. Careful measurements with compasses showed that the relation of the elevation to the radial pulse was not at the period of ventricular systole, but occurred during ventricular diastole, while the systolic period (*E*) corresponded with the fall in the tracing. It is necessary to insist upon this view, because inferences drawn



from the apex beat alone are liable to lead one into error. Even so careful an observer as Keyt<sup>8</sup> has fallen into error in this respect, and by mistaking the nature of an apex beat tracing has imagined that he detected an extreme delay in the appearance of the arterial pulse. I have detected similar errors of interpretation in other writers' tracings. It follows then that for a guide to any event occurring during a cardiac

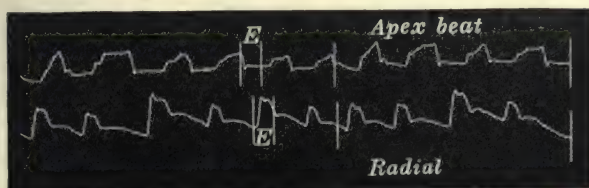


FIG. 42.—Simultaneous tracings of the apex beat and of the radial pulse. The rise in the apex tracing resembles the usual characters present in a tracing of the apex beat due to the left ventricle. On analysis it is found that the elevation is during the diastole, and the fall (E) during the systole, of the ventricle.

revolution the arterial pulse is the only safe and reliable one. When the apex beat is taken as a standard, careful inquiries should be directed to assure one of its true nature.

§ 32. *Alteration of the apex beat due to retraction of the lung.*—If one watches the progress of a case of advancing heart failure over a period of years, marked changes will sometimes be detected not only in the character but in the position of the apex beat. In the earlier stages of heart failure, due to mitral disease, for instance, the left ventricle may be pushed back by the distended right ventricle, so that it is entirely covered by the lung, and the apex beat may then be due to the right ventricle. In course of time, from pressure of the enlarged heart, the lung is compressed and recedes, leaving a large surface of the heart bare to the chest wall. In such cases the apex beat may be found in the posterior axillary line and in the eighth interspace. The tracing obtained then is one due to the left ventricle. In Fig. 303 there is a well marked apex beat with the elevation during ventricular systole obtained at this situation. At the *post-mortem* examination the point where the tracing was got was found to correspond with the position of the apex of the left ventricle. The lung was shrunken and retracted, and the whole anterior surface of the heart consisted of the enormously distended right auricle and right ventricle.

§ 33. *The shock due to the ventricular systole.*—I am of opinion that a good deal of confusion in regard to the correct interpretation of the heart movements has arisen from the association of the shock conveyed to the chest wall, when the ventricles pass into systole appearing to occur at the same time as the apex beat. Hence the apex beat and this impulse have become so connected that it is assumed that they are one and the same thing. The apex beat due to the left ventricle is a movement which lasts during the whole of the ventricular systole; the shock caused by the ventricular contraction endures but a short space of time, and occurs while the ventricular muscle suddenly hardens and corresponds with the upstroke only of the apex beat (*D*, Figs. 26 and 27). It is this shock which sends the lever so high in Figs. 29 and 38 at the beginning of the ventricular contraction. In the tracings of the liver movements (Figs. 31, 32, and 33) of the epigastric pulse (Figs. 34 and 35), and of the movement from the front of the heart (Fig. 30), the period of this shock is just before the fall due to the emptying of the ventricle. Thus, in noting the time of the shock and watching the epigastric pulse, for instance, as in Figs. 34 and 35, one could see that the retraction of the epigastrium followed it. If one associated the shock with the apex beat, it would therefore be assumed that the protrusion corresponded with the systole and the retraction with the diastole. It frequently happens that this shock is the only movement of the heart discernible on examining the chest. It is often markedly present in dilatation of the heart, when the heart's surface in contact with the chest wall is entirely made up of the right ventricle and auricle. In such cases it must not be assumed that the shock is the evidence of the contraction of the right ventricle only. It is impossible to distinguish the shock due to the right ventricle from the shock due to the left. The reason I insist upon this is because the perception of this shock has been assumed to be an evidence of the right heart contracting when the absence of a beat in the radial pulse was supposed to indicate the absence of a contraction of the left ventricle. As will be shown later, this sort of evidence is not only unreliable but actually misleading.

§ 34. *Clinical significance of the cardiogram.*—In order to appreciate the interpretations of tracings of the apex beat, it is necessary to comprehend fully what the apex beat really is.

During the diastole of the ventricles the heart is gradually swelling from the inrush of blood into all its chambers. With the occurrence of the auricular systole, a slight increase is made to the size of the ventricle by the addition of the auricular contents. Sometimes this addition is recognised as a slight wave in the cardiogram (*a*, Figs. 26, 29, and 38). Much more frequently this is not shown. With the onset of the ventricular systole a great change takes place in the position of the left ventricle. The muscle hardens and contracts upon its contents, and at the same time the heart twists round, so that the hardened apex projects forwards, pressing against the chest wall with considerable force. It is this that we recognise as the apex beat. During the emptying of the ventricle the apex is kept applied to the chest wall. After the ventricle is emptied the ventricular muscle relaxes and the apex recedes from the chest wall. It will thus be seen that the actual thrust of the apex—the apex beat proper—is a mere mechanical displacement of the heart. Now as certain events are known to occur at that time, such as the contraction of the ventricular muscle and a great rise of the intra-ventricular pressure, evidence of the character of these events has been sought in the tracings of this movement. But a moment's consideration will show that the movements registered by the mechanical displacement of the heart can give no more evidence of the strength of the muscular contraction or the pressure exerted by the ventricular systole, than a graphic record of a nudge of the elbow or a nod of the head would give of the strength of the muscles employed or the vigour with which they contracted.

Inasmuch as we know that the movement of the heart which we call the apex beat has a definite relation to the ventricular systole, we can get information in regard to the time and duration of other events in a cardiac revolution that are simultaneously recorded.

When the cardiogram is an inverted one, and obtained from the lowest and outermost point of the cardiac movement, it demonstrates the presence of a dilated right heart. Except in this instance a study of a cardiogram is not nearly so instructive as the physical examination of the apex beat. The position, the size, and the strength of the apex beat can be far better appreciated by the palpating hand. The duration of the ventricular systole can be far better recognised by the study of a



tracing of the radial pulse. For clinical purposes, therefore, tracings of the apex beat are of little value.

I have omitted reference to cases of adherent mediastinitis because my observations in these cases have been too limited to render my remarks of any value.



## CHAPTER V

### FACTORS CONCERNED IN THE PRODUCTION OF THE PULSE

- § 35. How the object of the circulation is attained.
- 36. The left ventricle.
- 37. The arteries.
- 38. The nerves.
- 39. The blood.

§ 35. *How the object of the circulation is attained.*—The object of the circulation is to supply a constant stream of material capable of nourishing the tissues and of replacing the loss sustained by the tissues in the evolution of energy, and to remove from the tissues such waste products as are capable of entering the circulating channels. In order to facilitate the exchange of products between the blood and the tissues, it is incumbent that they should be brought into intimate contact, and a certain amount of time allowed to permit the interchange. This is accomplished by maintaining a continuous pressure in the blood stream and a slowing of it as it approaches the capillaries, the current at the same time losing its intermittent character. To attain this, the object of the circulation, four factors are concerned: first, the left ventricle as the propelling force; second, the arteries as the channels; third, the nerves as regulators of the supply; fourth, the blood as the medium containing the nutritive elements.

§ 36. *The left ventricle.*—The left ventricle alone is the source of the power that causes the blood to move in the systemic arteries. To its inherent power of increasing or diminishing its activity is due the ability to supply the flow of blood according to the quantity required when the tissues are active or at rest. It is the strength of the left ventricle we are gauging when we seek to determine the strength of the

pulse. The full force of the ventricular contraction is not spent on the blood current merely during the period of its systole. Not only does the ventricle inject into the arteries a quantity of blood, but it does this with such force that it distends to a slight extent the larger arteries. The elastic coats of these arteries, as soon as the ventricular systole is over, compress the column of blood within them, and thus maintain a degree of arterial pressure during the period that the ventricle is not acting. The ventricular force is thus stored up by the distension of the elastic coats of the arteries, and liberated during the ventricular diastole.

§ 37. *The arteries.*—The arteries vary in the structure of their coats from the heart to the periphery. Roughly speaking, nearer the heart there is a predominance of the elastic coat, while towards the periphery the non-stripped muscular element predominates. As has already been said, the distension of the elastic membrane stores up the ventricular energy during systole, and the liberation of this energy during the ventricular diastole maintains a continuous pressure on the contained blood column. The non-stripped muscular fibres of the smaller arteries are employed to increase or diminish the calibre of the arteries according to the activity or quiescence of the tissues. The non-stripped muscular fibres of the whole system are not equally affected at the same time, but have the power of contracting and dilating the vessels in limited areas, according as the separate organs or tissues supplied are active or quiescent. This faculty is independent of the ventricular force, being regulated by the reflex nervous apparatus. These muscular fibres offer a continual but regulated resistance to the outflow of blood, and it is on account of this resistance that the arterial pressure is varied and maintained. Various conditions increase or diminish the amount of contraction of these fibres, and we recognise this variation by the amount of force we employ to overcome the arterial pressure in compressing the artery.

§ 38. *The nerves.*—The action of the nervous system in determining the condition of the pulse is (1) by regulating the rate, the rhythm, and the force of the ventricular contraction; (2) by regulating the calibre of the arteries. The first of these series of functions is effected by the nerve supply of the heart. This is threefold: (*a*) the intrinsic nervous mechanism of the heart; (*b*) the vagus nerves; (*c*) the sympathetic nervous system.

The function of the intrinsic nervous mechanism of the heart is not clear, but there are grounds for suspecting that it has some control over the rhythm of the heart, and it may be over the force of its contraction (§ 231). The vagus nerve when stimulated tends to slow the movements of the heart, and lowers the arterial pressure while the venous pressure rises. This is due to a diminished quantity of blood passing into the heart from the veins on account of the weakening or arrest of the contraction of the right auricle (Roy and Adami).<sup>9</sup> The sympathetic nerves when stimulated quicken the movement of the heart and augment the capacity of its chambers. But it is difficult to tell which of these nerves is the active agent in producing any given variation in the heart's action. Thus, when the heart's movements are accelerated, is it due to a suspension of vagus activity or to a stimulation of the sympathetic? The question is of some practical moment in regard to treatment, which may proceed on two lines. Thus, with a quick-beating heart or a heart easily excited to rapid action, treatment may aim at slowing the heart and increasing the force of its systole by the administration of digitalis, or it may aim at soothing the sympathetic by the administration of bromides or other sedatives. There are cases in which both kinds of treatment are followed by beneficial results.

The nerves supplying the arteries are derived from the sympathetic, and their function is limited to the regulation of the calibre of the arteries. There is a distinct relation between the action of these nerves and the action of those that regulate the heart. When the heart's action quickens the arteries dilate. The quickening of the heart movement is generally a sign that the heart is endeavouring to supply an increase of blood to the system, and whether this be due to increased exertion or weakening of the heart itself, the arteries respond to the demand by offering less resistance to the flow of blood. Perhaps it would be more correct to say that it is the dilatation of the arteries that causes the heart to quicken its action. This results whether the arteries dilate owing to external warmth, to increase of function, or to the tissues requiring more blood in consequence of the weakening of the heart. The converse occurs when the arteries contract. The resistance to the outflow of blood calls forth an increase in the strength of the ventricular systole. The duration of the systole thus lasts but slightly longer, whereas the duration of the diastole is considerably increased. Generally the slow



pulse is an indication of higher arterial pressure than the quick pulse. But this is only within certain limits. The high pressure pulse of Bright's disease is not of necessity a slow pulse, and slow pulses in healthy people never attain so high an arterial pressure as occurs in Bright's disease.

§ 39. *The blood.*—The blood being the fluid that circulates in the arteries, its condition modifies the character of the pulse. The blood may affect the pulse directly according to its quantity, or it may modify its character indirectly by its quality being so altered that it stimulates the regulating apparatus. The quantity of blood in the artery naturally gives a character to the pulse in regard to its size. The smallness or largeness of the artery does not necessarily imply a diminution or increase of the blood in the system. On account of the power of the arterial system to dilate and contract in sections, a small pulse may be quite consistent with a large quantity of blood in the system. The capacity of the venous system for storing large quantities of blood may likewise account for the appearance of a small supply of blood in the arterial system. Conversely, the large pulse characteristic of atheroma in advancing years is no criterion that there is a large quantity of blood in the system. Usually in such persons there is a remarkable absence of blood in the veins. Variations in the quantity of the blood in the system occur daily with the ingestion of food and drink. Loss of blood, whether occurring normally as in menstruation, or after childbirth, or through some wound, naturally modifies the pulse. In such cases in addition to the smallness of the pulse there is also a quickening of the rate and a lowering of the arterial pressure; but not always, for sometimes a slowing of the pulse may be a sign of internal hæmorrhage. The quality of the blood affects the pulse by stimulating the nervous supply regulating the circulatory mechanism (heart and blood vessels). Thus, in the various anæmias where there is a poverty in the oxygen-conveying elements of the blood, the heart is excited to more rapid action. Where there is some deleterious element in the blood, as in gout and Bright's disease, the peripheral resistance is increased by the stimulation of the vaso-constrictor nerves, so that increased arterial pressure and, it may be, slowing of the pulse, results.



## CHAPTER VI

### THE PULSE FROM INFANCY TO OLD AGE

- § 40. Periods of life.
- 41. Changes in the circulatory organs.
- 42. Relation of the normal condition to the pathological.
- 43. The pulse rate.
- 44. Variations of the pulse rate due to stimulation of the heart.
- 45. Variations of the pulse rhythm.
- 46. Changes in the artery.
- 47. Changes in the pulse wave and arterial pressure.
- 48. Diminution of the capillary field and of the quantity of blood in the old.

§ 40. *Periods of life.*—The life of a human being, from the period of the crying and puling baby to the lean and slippered pantaloons, passes through various phases—phases which permit the division of the period of human existence into various stages, according to the points and aspects from which it is viewed. In some respects it is the pulse, or rather the sum of the factors concerned in the production of the pulse, that gives the characteristic to each period, and the pulse itself also varies with each period of life. One can look upon the life of a human being as divided into three stages which merge the one into the other. In the first period the assimilation of nutriment exceeds the waste, and the whole organism increases in bulk and in strength. In the second period the process of assimilation of nutriment is practically counterbalanced by the waste, so that the body no longer increases in strength, though it may do so in bulk by the deposition of fat. In the third period the assimilation of nutriment no longer effectively replaces the waste, and the strength and the bulk of the organism gradually diminish.

§ 41. *Changes in the circulatory organs.*—All these changes are mainly dependent on the condition of the circulatory organs,

which also determine the character and duration of each period. But the organs concerned in the circulation are themselves affected by coincident changes which, in limiting the efficiency of the circulation, also limit the efficiency of the organism as a whole. The changes which take place in the organism with advancing years consist, therefore, in the main, of the inability to replace worn-out tissues by healthy virile structures. The imperfect restoration leads to imperfection of function. So far as the circulatory system is concerned the effect is first noticed in those structures that are poorly supplied with blood. The elastic coat of the arteries becomes first affected. This reacts in a double manner. The diminished resiliency of the arteries throws more work upon the heart, which has to encroach upon its reserve strength in order to maintain the blood pressure at that measure which is necessary for the due performance of the functions of life. The effect of this is to limit materially the field of cardiac response to effort. This arterial degeneration may react on the organs themselves. Thus in the heart fibrous or fatty degeneration of the muscular fibres may follow directly from the degeneration of the arteries, seriously and irreparably impairing the function of the organ.

§ 42. *Relation of the normal to the pathological.*—Although in considering the subject of this chapter we are supposed to take note only of the state of the pulse in the healthy organism, it will be seen from what has been said that what is called advancing age is in the later years of life but an interchangeable term for a progressive pathological condition. As these pathological changes are the common heritage, one can but look upon them as the expected, and therefore as normal to human existence. Inasmuch as the intensity of these changes and the rapidity with which they take place vary with each individual, no hard and fast rules can be laid down to distinguish what might be considered a normal variation in the pulse of old age from an abnormal one. Striking departures, however, from certain fairly defined limits should always arrest attention.

§ 43. *The pulse rate.*—The rate of the pulse gradually lessens from birth to about twenty-one. After this period the pulse rate remains fairly constant until after the age of sixty, when it may begin to quicken. The period at which quickening begins in old age and the extent to which it occurs depend, apart from other complicating diseases, mainly upon the

extent of the degenerative changes affecting the heart and blood vessels. The rate at any period of life is not the same in all individuals, and differences may exist within very wide limits. These will be appreciated from the study of the following table, given by Tigerstedt.<sup>10</sup> In this table there is given in the first column the age of the individuals examined; in the second column the greatest frequency of the pulse found in any one individual, and in the third column the slowest pulse; in the fourth column there is the average rate among all the individuals examined, and in the fifth column the number of individuals examined.

Age.	Pulse Frequency.			Number Examined.
	Maximum.	Minimum.	Average.	
0-1	160	101	134	59
1-2	136	84	111	33
2-3	134	84	108	48
3-4	124	80	108	63
4-5	133	80	103	94
5-6	128	70	98	56
6-7	128	72	93	42
7-8	112	72	94	39
8-9	114	72	89	48
9-10	120	68	91	47
10-11	106	56	87	73
11-12	120	60	89	75
12-13	112	67	88	107
13-14	114	66	87	80
14-15	112	60	82	71
15-16	112	66	83	77
16-17	108	54	80	54
17-18	104	54	76	67
18-19	108	60	77	48
19-20	106	52	74	57
20-21	99	59	71	67
21-22	96	41	71	54
22-23	100	56	70	63
23-24	96	50	71	60
24-25	96	50	72	44
25-30	102	52	72	180
30-35	104	58	70	125
35-40	100	56	72	144
40-45	104	50	72	105
45-50	100	49	72	102
50-55	94	52	72	42
55-60	108	48	75	58
60-65	100	54	73	60
65-70	96	52	75	51
70-75	104	54	75	44
75-80	94	50	72	44
80 and over	98	63	79	31



As a general rule it can be said that the larger the frame the slower the pulse. The pulse of tall men is slower than the average—in some instances markedly so. It is probably due to the fact that the body of the average female is smaller than that of the average male that the pulse is quicker in women than in men. The difference varies from five to ten beats per minute.

§ 44. *Variations in the pulse rate due to stimulation of the heart.*—The manner in which the pulse rate is modified by the various conditions of the healthy body is of considerable importance. The response of the heart to what one may call normal stimulation is frequently modified in various cardiac diseases. The knowledge of what should be expected from a healthy heart is necessary for the recognition of certain forms of heart failure. The healthy heart is readily affected by the most trivial circumstance. The exposure of the naked body to the cold air slows the pulse by a few beats per minute. The addition of clothing to the body, by increasing the warmth, increases the pulse rate. Increase of temperature has always a marked effect, whether derived from external sources or from a feverish condition of the body. When exposed to a high temperature in a dry atmosphere (as in a Turkish bath) it may attain a speed of one hundred and fifty per minute. It is because of the susceptibility to the variations of temperature that the pulse becomes increased in frequency in the tropics and lowered in frequency in the polar regions.

Effort (muscular or mental) has a distinct effect on the pulse; the former markedly, the latter only slightly. The change of position from lying to sitting up, with the legs down, increases the pulse rate from two to five beats per minute. On standing up a further increase from four to eight beats per minute may result. In slow walking a pulse of sixty-eight per minute increases to about one hundred beats per minute, quick walking to about one hundred and forty, running to about one hundred and fifty beats per minute. Ingestion of food quickens the pulse, cold food less than hot. Slight variations normally occur during the twenty-four hours, independent of external excitation.

§ 45. *Variations of the pulse rhythm.*—As the individual passes through life there are two periods when he is liable to pulse irregularities. These are: first, when the heart rate begins



notably to diminish in the young, from about the third year of life to puberty, most markedly between the ages of eight and fifteen years; and, second, towards the end of life. In regard to the pulse rate of the young, the table just given does not represent accurately enough the slowing of the pulse in single individuals. Although the difference between the maximum and minimum of frequency is very marked, such observations apply to separate individuals. If frequent observations be made on a child's pulse, it will be found that its rate occasionally varies in a striking manner. When kept quiet in bed, or after the subsidence of a febrile attack, the pulse will sometimes sink much lower than usual. At such times it tends to become irregular. The beats are each full and complete, the variations being only in the diastolic periods of the cardiac cycle. Very often the irregularity may have a respiratory rhythm. Occasionally this form persists in adults, and it may occur in an adult as in childhood, after a febrile attack. But the adult irregularity is usually of a different type. The long pause is usually preceded by an incomplete pulse wave, or there has been an imperfect ventricular systole during the pause. (This difference is more fully discussed in Chapter IX. § 75.) In some the irregularity may appear before middle age, but the great majority of cases occur in advanced years. It usually begins by a single irregularity occurring at rare intervals. Thus in a man about sixty years of age we may detect a single irregularity while the heart is excited during the first examination. It may be a few years before another irregularity is detected, then it may be found on occasional visits. Finally, it may occur at irregular intervals during every visit. Only very general rules can be laid down as to its occurrence, but the fact that irregularity does occur as a natural phenomenon should be borne in mind.

§ 46. *Changes in the artery.*—The infant's radial artery is naturally very small. We are not conscious of its presence, being unable to differentiate it from the surrounding structures, and we only recognise its pulse when the finger compresses the artery against the bone. This inability to feel the artery as a distinct structure is due not only to the smallness of the vessel, but to the fact that very often the padding of subcutaneous fat is relatively great in the very young. With advance in age the artery gradually increases in size, for two reasons. The hand to

which it is distributed increases in size, and hence needs more blood. But the artery increases at a greater ratio than the size of the hand. This is due to the fact that the heart in slowing throws more blood with each systole into the arterial system, and therefore the storage capacity of the whole arterial system has to be increased. Hence the radial with the other arteries increase in diameter with the natural slowing of the heart. After middle life the arteries insidiously begin to change by reason of the occurrence of degenerative changes, mostly in the elastic coat. The arteries become more dilated and tortuous, so that in the old and feeble the radial artery may be of considerable size. The degenerative process may go so far that bead-like thickenings are detected in the coats, or the artery may become hard and pipe-like from calcareous deposits in the arterial walls.

§ 47. *Changes in the pulse wave and arterial pressure.*—The pulse wave from birth onwards to puberty increases in strength and volume. The quantity of blood thrown out with each systole increases until the pulse rate reaches its lowest limit. This implies a change in the arterial pressure, for, whereas the arterial pressure was wont to be maintained by a series of quick ventricular contractions throwing out a small quantity of blood, it is now maintained by a slow acting ventricle throwing out a larger quantity of blood. In the former case the arterial pressure is the more uniform, in the latter the difference of pressure between the end of ventricular diastole and during ventricular systole is greatly increased. This difference becomes still more marked with the diminished resiliency of the artery in later life. To maintain a mean pressure in the artery of such extent that the functions of life can be properly carried on, the heart has to contract with more vigour, the helpful effects of the elastic coat having diminished. With more vigorous ventricular contraction there is increased arterial pressure during the ventricular systole. With their loss of resiliency the arteries approximate the character of rigid tubes, and hence the arterial pressure is not efficiently maintained during the ventricular diastole. The result is a greater fall of pressure towards the end of diastole. These changes give the character to the pulse of advanced life—a pulse wave forcible during ventricular systole, with the artery compressible after the wave is past. In sphygmograms the tracing has a high upstroke, the lever maintained high during the ventricular systole, and a rapid and deep fall during diastole.

While this is a common character to most pulses in advanced life, many variations occur dependent on circumstances not always easy of explanation.

§ 48. *Diminution of the capillary field and of the quantity of blood in the old.*—However healthy the individual may be, after a period he begins to diminish in bulk. This is apparent in the first instance by the disappearance of the subcutaneous fat. The face becomes gray and wrinkled. The scalp, if he be bald, is white and glistening, and seems plastered tight upon the bones. The radial artery stands out visible like a tendon, and can be rolled about by the finger like a thick cord. The skin in some becomes thin and attenuated, and crinkles like tissue paper. The cause of all this is evidently due to diminished blood supply. This is very evident in operating upon elderly people. The bleeding that follows the incision is scant, unless an artery of some size be cut. The general oozing of the cut surface that takes place so freely in the young and virile is replaced by bleeding from a few separate points, where a small vein or artery has been cut. The healing of the wound in the old is a more tedious process, and much more liable to be interrupted by the formation of pus in the wound. This is evidently due to the tissues being impoverished by the diminished blood supply. Not only is there a diminished capillary field, but there is actually a diminished amount of blood in the system. In my researches on the venous pulse I had expected that in the failing heart of the old there would be great liability to fulness and distension of the veins near the heart. On the contrary, I found that these were the people who rarely presented this symptom. The fact that the arterial system is demonstrably deficient in the quantity of blood, and the fact that there is a complete absence of engorgement in the venous system, undoubtedly point to the conclusion that the total amount of blood diminishes in old age.



## CHAPTER VII

### EXAMINATION OF THE PERIPHERAL CIRCULATION

- § 49. Inspection of the capillary circulation.
- 50. Inspection of the minute cutaneous veins.
- 51. Inspection of the larger veins.
- 52. What is the pulse?
- 53. Inspection of the arteries.
- 54. Digital examination of the arterial pulse.

§ 49. *Inspection of the capillary circulation.*—The condition of the capillary circulation at once attracts attention, for the aspect of the face first claims one's consideration. We associate certain conditions with different periods of life. Although the face of the healthy infant is pale it is, however, associated with a plumpness and fulness of countenance in striking contrast to the pallor and shrunken appearance around the orbits and mouth of the child dying from an exhausted heart. The flushed countenance of fever is distinct from "the blush that mantles the cheek" of healthy youth. As years advance this blush disappears or gives place to a colour no longer diffuse, but showing the lines and streaks of injected blood vessels. Yet even in advanced age a certain tinge indicates the countenance of health, and separates it sharply from the gray and shrunken countenance of empty capillaries due to failing heart; from the pale contracted face, caused by the impoverished blood in malignant disease; and from the livid swollen face due to distension of the capillaries by non-oxygenated blood. These points are too numerous and too subtle to describe or to classify, yet the observing physician is helped much in his examination by the recognition, almost instinctive, of the aspect of the face due to the condition of the capillary circulation.

There are other conditions the recognition of whose signifi-

cance is beyond our powers to explain. The impression left on the skin in using the stethoscope varies much in individuals. In some there is no capillary reaction whatever. In others there is a distinct blush within the pale ring-like impression. Very rarely there occur tiny hæmorrhages within the ring. The scratching of the skin with a pin-head gives rise to a variety of appearances due to stimulation of the vasomotor nerves. These may vary from a white line surrounded by a red blush of varying extent up to the livid and swollen streak characteristic of factitious urticaria. Not only do different individuals react differently, but different areas in the same individual may give different reactions. No satisfactory explanation of these phenomena has yet been given. The influence of the vasomotor nerves in affecting the capillary circulation is observed in many other ways. The blushing of the face from some mental emotion, and the extreme flushing of the face and body in certain neurotic complaints, particularly in women about the menopause, is due to some reflex stimulation of the vaso-dilators. The pallor of limited portions of the skin, as seen in such diseases as migraine and Raynaud's disease, is in all probability due to stimulation of the vaso-constrictors. Normally the stream of blood through the capillaries is continuous, but in aortic regurgitation the stream may be demonstrated to be more or less intermittent. Thus if a small area on the forehead be rendered red by gentle rubbing of the skin, this area will be observed to redden and to pale with each systole and diastole of the ventricle.

§ 50. *Inspection of the minute cutaneous veins.*—Fulness of the minute cutaneous veins in various parts of the body is not an uncommon circumstance. The most striking instance is when a series of these small veins extends like an arch across the front of the chest. The arch begins on either side at the level of the sixth, seventh, and eighth ribs, and passes across the upper part of the epigastrium. This arch of veins is far more common in men than in women. It is seldom seen before puberty. It is more frequently observed in the consulting-room than in the wards of the hospital, because lying in bed favours the flow in the veins. Its causation is obscure. It is evidently situated at the watershed between the blood flowing upwards to the superior vena cava, and the blood flowing downwards to return by the inferior vena cava. These full and visible veinlets are at the

origin of the superior vena cava system. It is possible that being at the extreme limit of the ventricular force, the vis a tergo is here very slight. Each little veinlet ends abruptly, and, it may be, joins a large veinlet at such an angle that a slight obstruction is favoured. Any mechanical obstruction to the flow of blood in the superior vena cava from the chest-wall, such as an aneurysm or mediastinal tumour, may cause these veins to increase markedly. Under such conditions they may become tortuous and swollen as large as a crow-quill. When a well-marked arch of veinlets persists in a patient who is kept in bed, some intra-thoracic obstruction to the flow may be suspected. Usually at the same time the abdominal cutaneous veins are distended, because a quantity of blood is diverted to them from the chest. Otherwise this arch of veinlets does not appear to possess any pathognomonic significance. Individuals exhibiting this arch in a characteristic manner may be in the enjoyment of the best of health, and capable of undergoing great bodily exertion, with no sign of cardiac or other weakness. These veinlets may be seen in other situations, as across the back at the level of the scapular spine, and at the level of the top of the sacrum, in the cheeks, in the ears, and in the thighs.

§ 51. *Inspection of the larger veins.*—Distension of the larger veins indicates obstruction to the flow. This may be due to some defect in the valves of the veins, as in the varicose veins of the legs. In rare cases one meets with an absence of the valves at the top of the femoral vein. In such case the femoral vein is seen large and prominent coursing down the inside of the thigh.

Distension of the abdominal superficial veins, with the blood flowing upwards, indicates some obstruction to the inferior vena cava. Fulness of the veins of the neck and arms may be due to mechanical obstruction to the flow, or to distension of the right side of the heart. In the veins of the neck, when they are full, distinct movements can usually be detected. These may vary from mere dancing vibrations to large rhythmical movements, visible from a distance of several yards. The interpretation of these is difficult as a rule from mere observation, and can only be done when these movements are graphically recorded along with some standard movement, such as the arterial pulse or apex beat. It is often difficult to recognise whether the pulsation is in the veins or in the carotid. The description in the text-



books is far from being sufficient for this purpose, and mainly applies to the superficial veins. Superficial veins are often not visible, and the internal jugulars, when the pulsation is most marked, are often masked by their coverings. Further consideration of this subject is continued in the chapters dealing with the venous pulse.

§ 52. *What is the pulse?*—In order fully to appreciate the study of the arterial pulse, it is essential to have a proper conception of the true nature of what it is we perceive when we examine the pulse with the finger. Broadbent<sup>11</sup> very properly calls attention to a universal misconception of what the pulse really is. He points out that it is not an expansion of the artery due to the blood discharged into the aorta. Marey<sup>12</sup> says that the expansion is so slight that many physiologists have denied its existence, and he states that Poiseuille has demonstrated that in the larger arteries a slight expansion with each systole does take place. No doubt the aorta and its primary branches are somewhat dilated by the injected blood, but whatever the expansion may be in them, in the carotid and radial it must be very minute. To feel the pulse or to take a tracing it is necessary that the artery should be flattened against the bone. It is for this reason that surgeons operating in close proximity to a large artery may be utterly unconscious of its neighbourhood unless they inadvertently wound it or recognise its pulsation by having compressed it against some resistant structure. The visible movements of the artery are extremely deceptive. They often give the appearance of contracting and expanding, but if the movement be critically examined, it will be found to be, in reality, a displacement of the artery. A straight artery like the carotid resembles somewhat a cord that is periodically tightened and slightly relaxed. During the systole of the ventricle, the carotid is straightened and tightened, and it becomes slightly relaxed during the ventricular diastole. In persons with thin necks this movement can be studied. If we place one receiver over the carotid and one alongside it, and have the movements properly registered, the one tracing will be found to be the exact reverse of the other (Fig. 43). If the artery expanded during the ventricular systole, it would naturally thrust out all the tissues surrounding it, and the tracing from the side would then be an exact duplicate of the one taken from the front of the artery. The movement, then, of the beating carotid is one of

displacement of the whole vessel, not a dilatation and contraction of the vessel.

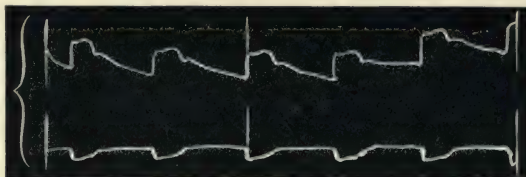


FIG. 43.—The upper tracing was taken with the receiver over the carotid artery, at the same time as the lower one was taken with the receiver placed by the side of the carotid artery. The lower tracing is the inverse of the upper.

A similar confusion arises in studying an artery when it is tortuous. In looking at the radial when it is tortuous one can readily imagine that the rising and falling of the artery is really a distension and contraction of the artery. But if a suitable case be taken where in the course of the tortuous artery there is a short lateral bend, the movement can be demonstrated to be due to the displacement of the artery and not due to expansion and contraction of the artery. If the pad of the sphygmograph spring be placed close to the artery on the concave side of a bend, and a tracing taken, it will be found that during the ventricular systole the bend is exaggerated, the artery being pushed further away from the straight course, and during ventricular diastole the bend diminishes. If tracings be taken of the pulse in such a radial artery at the same time as the carotid pulse (Fig. 44),

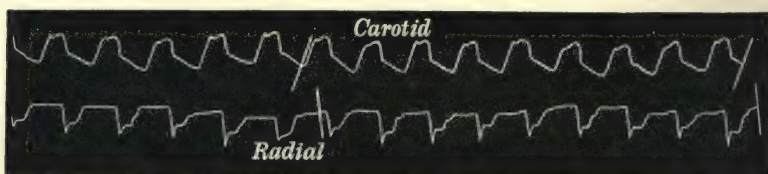


FIG. 44.—Simultaneous tracings of the carotid and radial pulses. The radial tracing was taken by placing the pad of the sphygmograph by the concave side of a bend of the tortuous radial artery. During systole the artery receded from the sphygmograph and returned during diastole, and hence the tracing obtained is an "inverted sphygmogram."

it will be found that the radial gives an inverted tracing comparable to that in the preceding figure. If the visible movement were due to the expansion and contraction of the artery, the lever would, on the contrary, rise during systole and fall during diastole, as in an ordinary sphygmogram.

What we recognise then as the pulse is the sudden increase

of pressure within the artery pressing against our finger. With the cessation of the ventricular systole the resistance to our finger steadily diminishes until the next ventricular systole suddenly rises. Broadbent uses the following apposite illustration: "Such a pulsation can be felt on a large scale by placing the foot on the inelastic leather hose of a fire-engine in action, in which there can be no expansion."

To speak of the pulse as being the expansion and contraction of the arterial walls, or "the swinging backwards and forwards of the arterial walls," is not only to use language of exaggeration, but to convey a totally erroneous conception of what the pulse really is.

While the pulse is due to the increased arterial pressure arising from the injection of blood into the arterial system by the ventricular systole, it is not the progress of the blood thrown in by each ventricular systole that we feel when palpating the artery. There is a continuously flowing stream in the arteries, and if the stream were open the pulse would be visible as a wave passing down the current with greater rapidity than the current itself. Being in a closed tube, which is incapable of expanding, the wave at the moment it passes represents increased flow of the contents of the artery. This is shown by the fact that more fluid escapes from an open tube when the pressure is high than when it is low, as in the intermittent flow from a wounded artery, each jet corresponding to a pulse wave.

§ 53. *Inspection of the arteries.*—Inspection of the arteries reveals in health but little movement. Conditions giving rise to forcible action of the left ventricle may render the pulse visible in some of the superficial arteries. Exertion, excitement, or the febrile state may induce visible beating of the carotids, while this is a marked feature when the arteries are tortuous and atheromatous, and in such a disease as exophthalmic goitre. In free aortic regurgitation not only is there marked pulsation of the carotids, but pulsation is visible in numerous superficial arteries in various situations.

§ 54. *Digital examination of the arterial pulse.*—It is usual in the routine examination of the pulse to place two or three finger tips on the radial artery near the wrist. The fingers are laid on the artery and moved upwards and downwards and across the artery, at first gently and then with more pressure. By this procedure a knowledge of the size of the artery and the



conditions of its walls is acquired. Steady pressure being applied in order to obliterate the pulse, the force required to attain this gives an idea of the arterial pressure, and of the character of each individual pulse wave. The various points connected with this method of examination of the pulse will be fully dealt with when describing the sphygmographic character of the various forms of the pulse. In this place only a short reference to the terms usually employed and the points to be noted will be made.

*The condition of the walls.*—We recognise the yielding nature of the arterial coats in healthy arteries. In degeneration of the coats the arterial walls may be universally thickened or contain bead-like patches of induration as in atheroma, or the artery may have become a rigid tube as in calcareous degeneration.

*The size of the artery.*—The variations in size depend entirely upon the degree of relaxation of the muscular coat of the artery. A large artery is not necessarily significant of a strong pulse, nor a small artery of a weak pulse. An increase in the size of the artery frequently implies diminished opposition to the work of the heart. The size of the artery can sometimes be readily appreciated by lightly rolling it under the fingers. At other times it can only be detected when the pulse is elicited by firm pressure at the place where we expect to find it. This difficulty may occur where there is a good-sized artery embedded in a fat, well-padded wrist, or where the artery is small and contracted. On the subsidence of a fever a notable diminution in the size of the artery can often readily be recognised.

*The arterial pressure.*—The trained finger is as yet the best guide we have in judging the pressure within an artery. The knowledge necessary to determine what is normal and what is abnormal can only be acquired by the constant study of the pulse. The finger tips become so educated in course of time that we readily appreciate the sensation conveyed in compressing an artery. We distinguish an increase of the normal pressure as the hard and incompressible pulse (*pulsus durus*), and a diminution of the normal pressure as the soft compressible pulse (*pulsus mollis*).

*The pulse rate.*—The reckoning of the pulse rate should be made at a late stage of the examination. When abnormally quick it should be again counted when the patient has regained his composure. It is best enumerated in two separate half minutes to ascertain if the heart is acting quite steadily. In

children, unless asleep, abnormal frequency is often very unreliable as a guide, as the presence of the doctor often keeps up a continued excitation of the heart. While the rate of the pulse indicates the number of the contractions of the left ventricle, it sometimes happens that the ventricular contractions are so weak that the pulse wave is not perceptible to the fingers. In such cases the pulse is usually slow or irregular in rhythm. To appreciate the significance of the pulse rate due regard should be paid to the age and idiosyncrasies of the patient, and the ailment from which he suffers.

*The size of the pulse wave.*—The trained finger can recognise a great variety in the apparent volume of the wave itself. Some waves seem to roll up under the finger, passing gradually away, while others pass quickly, giving a mere flick to the finger.

*The impact of the pulse wave on the finger.*—This may be quick and abrupt and the pulse wave quickly disappear (*pulsus celer*), or the impact may approach the finger gradually and gradually subside (*pulsus tardus*). Although the pulse wave occupies such a short space of time, yet the sensitive finger readily recognises these different features.

*The rhythm of the pulse.*—The beats should follow one another at regular intervals, and should be of equal strength. The divergences from the normal rhythm are numerous, and the usual terms employed to distinguish them are, in my opinion, both unsatisfactory and misleading. This subject is fully entered into later. In estimating the rhythm of the pulse, one's whole attention should be concentrated upon the observation. If one does not exclude other thoughts from the mind a variation in the pulse rate and strength may apparently be felt. This is due to a failure to appreciate the pulse during a remission of one's attention. I have not only been conscious of this myself, but in cases where it was important to note the fact, as in pneumonia, I have found my colleagues describing irregularity as being present, when careful examination revealed a perfectly regular pulse.

*The two radial pulses compared.*—Finally, the two radial pulses should be compared, and any difference in the character of the beats noted. A difference in the strength of the two pulses may be due either to an abnormal distribution of the arteries on one side, or to an interference with the lumen of a vessel on one side after the innominate has sprung from the

aorta. A difference in the character of the pulse usually occurs only in the latter case. The two most frequent conditions altering the character of the pulse on one side are the presence of an aneurysm or of an atheromatous plate, diminishing the lumen of the vessel.



## CHAPTER VIII

### ARTERIAL PRESSURE

- § 55. The causes of the arterial pressure.
- 56. The standard of arterial pressure.
- 57. The character of the pulse in increased arterial pressure.
- 58. Conditions giving rise to increased arterial pressure.
- 59. Recurrent high arterial pressure.
- 60. Symptoms associated with increased arterial pressure.
- 61. Recurrent high arterial pressure as a cause of angina pectoris.
- 62. Vasomotor angina pectoris.
- 63. Low arterial pressure.
- 64. Character of the pulse in low arterial pressure.
- 65. Conditions giving rise to low arterial pressure.
- 66. Symptoms associated with low arterial pressure.
- 67. The pulse in syncope.

§ 55. *The causes of arterial pressure.*—With each recurring systole as much blood is thrown by the ventricle into the arterial system as has escaped during the preceding cardiac cycle. During the ventricular systole, therefore, the pressure within the arteries is greatly increased, inasmuch as the arteries receive during that period as much blood as they lost during the whole cardiac cycle. The escape of the blood from the arterial system is mainly regulated by the contraction or relaxation of the muscular fibres of the arterioles, and in all probability by the contraction and dilatation of the capillaries. The arterioles are always contracted to a certain degree, yielding a little or contracting a little as circumstances demand. Their resistance to the onward flow always retains a certain amount of blood within the arterial system, so that it is never empty between the ventricular systoles. Hence it is that during the ventricular diastole the arteries are always perceptible, and their contents offer resistance to the compressing finger. It is the resistance to compression that we recognise as arterial pressure. Its degree

depends on the amount of resistance to the outflow offered by the arteries and capillaries. One may express it thus: the call, by the tissues, for more blood is responded to by a dilatation of the arterioles and capillaries, the heart in like manner increasing its work either by the greater energy of its contraction or by increasing its rapidity. When at any time the action of the heart does not supply the blood as fast as is demanded, then the arterial pressure begins to fall, and the heart is no longer able to accomplish its work properly. The tissues are not nourished to their proper standard, and the consequences of heart failure gradually impair the functional activity of the various organs. On the other hand, if the tissues do not receive their proper supply of blood in consequence of restriction of the outflow offered by the contraction of the arterioles and capillaries, the heart responds to the call of the tissues by increasing the strength of its systole. If now the heart is exerting greater force and there is not a corresponding increased outflow, the excess of energy will be stored up in the elastic coat of the arteries. These, contracting strongly on the arterial column of blood, increase the pressure within the artery. We recognise this by the greater resistance the artery offers to the compressing finger. This is what we term increased arterial pressure.

§ 56. *The standard of arterial pressure.\**—If we possessed instruments delicate enough we might be able to determine what the normal arterial pressure of a given individual was, and to note any variation from it. But so far all our instru-

\* During late years several instruments have been invented for the purpose of accurately measuring the arterial pressure. Those that I have used (Oliver's and Hill and Barnard's) are so constructed that the maximum movement of a lever shows the mean pressure within the arteries. On considering what it is that these instruments show, it has seemed to me that the pressure necessary to attain this maximum movement is that which, while sufficient to compress the artery when the pressure is at its highest, is still not sufficient to obliterate the arterial lumen when the arterial pressure is at its lowest. As the maximum movement may be exhibited through a considerable range of pressure, and as it is approached and departed from very gradually, no point exists where one can say with certainty that the mean pressure is attained. At all events, after numerous attempts with these instruments, I was never able to note the exact period of maximum movement with that precision necessary for accurate observation. I consider that the movement of the levers in these instruments is exactly the same kind of movement obtained by the ordinary sphygmograph, and that the same unreliability in regard to the estimation of the pressure by the sphygmograph attaches to the results obtained by all such instruments.

ments are incapable of doing this with that precision and certainty which is necessary to be useful. We are therefore driven to depend upon that most treacherous of all methods, the impressions conveyed to our minds through the sensory nerves of the fingers. With careful tuition the trained finger can undoubtedly become a most sensitive instrument. By constant practice and study each physician makes for himself a standard of arterial pressure which he recognises as normal. It is therefore left entirely to his experience to say whether there is any departure from the normal. As minds differ, and the power of perception in different individuals varies, it follows there can be no recognised standard of arterial pressure. Then again another factor arises, viz., the arterial pressure normal to one individual may not be normal to another. Hence it follows that it is impossible to indicate with any approach to definiteness what may be the normal arterial pressure. Yet within certain limits there is an accepted recognition of what constitutes a standard in arterial pressure, and with practice one can recognise variations in pressure with a certain degree of confidence.

§ 57. *The character of the pulse in increased arterial pressure.*

—The size of an artery does not necessarily correspond with the variation in arterial pressure. Sometimes the radial artery is small and at other times it is large, and small arteries that are usually scarcely perceptible may become readily recognisable during a period of temporary increased arterial pressure. The radial artery, on the other hand, particularly in the young, may be very small, and at first the strength of the pulse may not be apparent. There is little variation in pressure on compressing the artery, and the difference between the arterial pressure at the end of diastole and during systole being relatively slight, the significance of the increased pressure is apt to be neglected. If, however, the artery be steadily and persistently compressed, it will be found to be hard and cord-like even between the beats.

The impact of the oncoming wave may be somewhat gradual in attaining its maximum force, and sometimes the tracing obtained presents a sloping upstroke, or may even be anacrotic (Fig. 45). If the heart be strong and contracting vigorously the pulse wave may strike abruptly, as in certain cases of Bright's disease (Fig. 46), or in slow pulse with fever, where the arterioles have not relaxed (Fig. 11). After attaining its maximum force the pressure does not fall suddenly away during the diastolic



period. In this particular the pulse of increased arterial pressure under discussion differs from that where there is great increase in the arterial pressure during systole, and a great fall in pressure during diastole, as occurs most typically in aortic regurgitation, and in large atheromatous arteries during febrile excitation of the heart. In the pulse of continuous high pressure the dicrotic wave is not perceptible to the finger as a distinct wave, but is merged in the resistance offered to the compressing finger, as in Figs. 45 and 46. The aortic notch is high above



FIG. 45.—Anacrotic pulse of high arterial pressure, from a small radial pulse.

the level to which the tracing falls at the end of diastole—in striking contrast to what occurs in aortic regurgitation. The shock of the oncoming wave in the arteries may be felt by the patient over his whole body when the heart is acting with great vigour. Although the pulse rate may become slower with increase of pressure, it is far from being the rule that a high pressure pulse is a slow pulse. In many cases the pulse rate may




FIG. 46.—Pulse of high arterial pressure, from a case of Bright's disease with a large radial pulse.

continually be ninety and over, with chronic Bright's disease, and yet the pulse retain its peculiar resistant cord-like quality. In cases of recurrent high arterial pressure the pulse rate generally becomes slower.

§ 58. *Conditions giving rise to increased arterial pressure.*—Normally there is a balance maintained between the strength and rapidity of the heart's action, the state of activity of the arterioles, and the demands of the body tissues. An increased demand for more blood by the tissues is equally responded to by a dilatation of the arteries and increased action of the heart. When, however, the intermediary between the heart and the tissues is abnormally narrowed, so that the arterioles offer to the

outflowing blood a greater resistance, the heart increases in vigour in order to overcome this resistance. This increased resistance to the flow may arise from peripheral stimulation of the vasoconstrictors, or from central stimulation. The peripheral stimulation seems to be due to certain irritating materials in the blood which stimulate the muscular fibres of the arterioles to increased resistance. It has been repeatedly demonstrated by experiments that certain substances do act thus directly in causing arterial and capillary contraction, and this view seems to be the most reasonable explanation of the symptoms as they appear in man. We find evidence of the central stimulation best illustrated in certain febrile cases with mental symptoms. Where the heart and blood vessels do not respond in the usual manner to febrile stimulation the heart acts slowly and with great vigour. The pulse in such cases is hard and resistant (Fig. 11).

§ 59. *Recurrent high arterial pressure.*—The increase in arterial pressure is rarely maintained at a continuous height, but varies from time to time even in those in whom a marked increase is a permanent symptom.

This recurrent high arterial pressure may be present in a great variety of conditions, and it is during a period of recurrent increase of arterial pressure that most of the characteristic symptoms are evoked. Thus, during the course of such diseases as chronic Bright's disease and gout the pulse may become extremely hard and resistant for considerable periods. Associated with this one often finds other distressing symptoms. The reduction of increased pressure by purgation arising either spontaneously or by means of drugs is usually accompanied by disappearance of the associated symptoms. Besides the diseases mentioned there are a great number of other conditions in which increased arterial pressure with its associated symptoms occur. It may take place normally with the recurrence of the menstrual period or in pregnancy. In the former case the evidence is most obvious immediately before the discharge begins, and relief usually follows once the discharge is freely established. Clifford Allbutt<sup>13</sup> has written a very suggestive paper pointing out the similarity of certain symptoms in pregnancy to those in diseases in which some toxic material circulates in the blood. The increased arterial pressure cannot be readily demonstrated in every case, as the change may not be of sufficient strength to be recognised by the ordinary means of observation. Yet, that it does occur

one can readily demonstrate in exceptional cases. Thus Fig. 47 is from a patient four months pregnant. The radial pulse is fifty-two per minute. Usually the pulse is about eighty. It is of good size, firm, and resistant to the finger. I had the patient under observation for many years, yet, except during pregnancy, I never detected the pulse so slow and so hard. The slow pulse in such cases is not constant, but becomes so for varying periods, as it does in Bright's disease and gout. In favour of Clifford Allbutt's view that the high pulse pressure in pregnancy is due

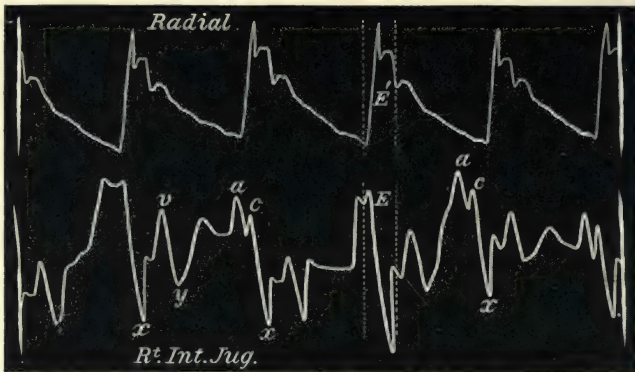


FIG. 47.—Slow pulse of high arterial pressure during pregnancy. There was also marked pulsation in the internal jugular vein.

to the circulation of some noxious material, may be mentioned the fact that the high arterial pressure is not the evidence of a compensatory cardiac hypertrophy, as is usually assumed. The increase that takes place in the heart's strength during pregnancy does not enable the patient to exert herself with the freedom she possessed before conception. The increased arterial pressure is almost invariably accompanied by other evidences distinctly pointing to a limitation of the field of cardiac response—breathlessness on exertion, easily-acquired fatigue, and œdema of the legs and lungs. In addition a distinct dilatation of the right heart with increased pulsation in the veins (as in Fig. 47) can often be demonstrated.

In some people after middle life there are occasionally found periods during which the pulse is harder than usual. In them no distinct evidence of any particular disease may exist. It not uncommonly manifests itself with some degree of constipation, or after some prolonged course of overfeeding, or want of sufficient



muscular exercise. It is likely also that it is commonly present in commencing atheroma. In some cases of chronic poisoning, as in plumbism, increased arterial pressure may occur.

§ 60. *Symptoms associated with increased arterial pressure.*— Besides the sensations afforded by the compressing finger there are other evidences of arterial pressure, some of these directly due to the high pressure, others either due to it or caused by the same morbid material that stimulates the arterioles to increased contraction. The continual resistance offered by the arterioles to the work of the heart stimulates the heart to increased effort. As a rule the result of long continued high arterial pressure is hypertrophy of the left ventricle. So long as this hypertrophy is able to overcome the resistance, the size of the organ may not assume a very large bulk. But if a patient with high arterial pressure live long enough, a period is reached when the ventricle is no longer capable of emptying itself in face of the obstructing arteries, and as a consequence dilatation of the organ ensues. With dilatation of the ventricle incompetence of the mitral valve takes place, and gradually the usual results of backward pressure are established. The heart under these circumstances may assume an enormous size, and the apex beat may be felt in the eighth interspace and in the mid-axillary line.

Attacks of difficult breathing are found in the elderly, or in those suffering from chronic Bright's disease, associated with periods of increased arterial pressure. These attacks may be so severe as to resemble asthma,—in fact the asthmatical attacks of the elderly are often of this nature. In others the attacks are of the nature of bronchitis, accompanied by great breathlessness on exertion. In these the pulse is usually small and hard. Other symptoms are often present. The contracted arterial system prevents the complete evacuation of the contents of the heart. In consequence of this the heart dilates. This may not always be recognised by percussion, but frequently it is shown by marked pulsation in the jugular veins (§ 238). The patient also may complain of severe præcordial distress, amounting at times to the pain resembling that of angina pectoris. Treatment devoted to the lowering of the arterial pressure, as by the administration of a mercurial purge, or by the use of iodide of potassium, has often a speedy and beneficial effect.

Hæmorrhage may occur during temporary increased pressure when the walls are otherwise healthy, but where some changes

near the vessels have lessened their power of resistance. Thus when menstruation is impending a tendency to hæmorrhage is manifested elsewhere than from the uterine vessels. Bleeding at the nose is sometimes observed occurring at regular monthly periods. I have seen a few cases of ulceration of the nasal mucous membrane, where on the day preceding the menstrual flow a few drops of blood would flow from the nose. Surgeons have observed that occasionally in sinuses from which there was usually a sero-purulent discharge, that this discharge becomes bloody about the menstrual period. I have at present under observation a woman with chronic phthisis, who for some years has had to rest in bed during her menstrual period, because hæmorrhage from the lung frequently occurred at that time. Doubtless in these cases the blood vessels supplying the granulations lining the sinus or phthisical cavities are not supported by healthy tissues, and are less able to resist the increase of arterial pressure that occurs at the menstrual period. Continued high arterial pressure, as occurs in Bright's disease and in gout, leads eventually to such changes in the arteries that they are unable to bear the strain, and thus become liable to rupture. The time when cerebral hæmorrhages are apt to occur is during one of the recurrent attacks of high pressure. This can often be recognised not only by the hardness of the pulse itself, but also by the association of other symptoms, such as a scantiness in the urine and an increase of the amount of albumin. In a gouty patient under my care I have witnessed the occurrence of four distinct attacks of bleeding during periods of high arterial pressure. The first was eight years ago, when there was a slight hæmorrhage into the conjunctiva of the right eye. The next was five years ago, when he had a most persistent attack of bleeding from the nose. During my attendance on him at this time I made a curious observation. The bleeding came on in irregular attacks, there being sometimes a couple of days between two. While compressing the nose during an attack of bleeding from the right nostril, I felt an artery beating strongly by the side of the nose. By exerting pressure with the finger upon the artery, the bleeding invariably ceased. During the intervals between the attacks the artery could not be felt. This patient had had repeated attacks of gout, but there was never any albumin in the urine. I did not attend the patient again till four years later, when I was summoned to see him. He had now an attack of cerebral



hæmorrhage with right-sided paralysis. The pulse was extremely hard and tense, the urine scanty, and containing a large quantity of albumin. Since then I have often found the urine nearly free from albumin, and again I have found it containing a considerable quantity, in the latter case with the pulse always hard and resistant. Lately he has had another prolonged attack of epistaxis. In another case an elderly man, who has been under my care for slight albuminuria for a number of years, had an attack of cerebral hæmorrhage a year ago. From this he partially recovered. His urine at the time of the attack contained a considerable quantity of albumin. After treatment, the amount of albumin was greatly diminished. A few days ago I was again called to see him. He was suffering from a dull headache, loss of appetite, inability to move his legs, and his back was too weak to allow him to sit up. His urine was scanty (fourteen ounces in the twenty-four hours) and contained a large quantity of albumin. His pulse was slow, large, hard, firm, and resistant. There was a small hæmorrhage under the conjunctiva of the right eye. With free evacuation of the bowel, free perspiration, and increased discharge of urine, the symptoms quickly subsided. It is well to remember that repeated pulmonary hæmorrhages may occur in the course of Bright's disease, and patients may live many years after such attacks. I have seen such cases mistaken for tuberculosis.

Although the hæmorrhage arising from this recurrent increase in the arterial pressure may not be preceded or accompanied by any other noteworthy symptom, yet other symptoms of a distressing character are not infrequent. These may vary from the slightest feeling of discomfort to extreme prostration, convulsions, loss of consciousness, and at times to attacks of angina pectoris of a most dangerous form. Many people suffering from gout and Bright's disease, and even others—elderly people in whom symptoms of these diseases can never be detected—have periods of depression, accompanied by a variety of symptoms. Thus a gouty man may have his hands or feet aching, with some digestive trouble and general discomfort—a feeling as if an attack of gout were impending. An attack may even then occur. The pulse in these cases can almost invariably be recognised as increased in pressure. In patients with Bright's disease somewhat similar periods of recurring discomfort occur. They may be accompanied by symptoms of varying severity, viz. sickness



and retching, muscular twitchings, intense headache, convulsions and loss of consciousness. The patient, a medical man, from whom Fig. 46 was taken, frequently suffered in this way. The pulse at these times became slow and hard, so much so indeed, that he stated that he felt each beat of the heart throbbing all over his body. Several times he had convulsions, followed by unconsciousness. Violent diarrhœa set in spontaneously, after which he regained consciousness, and for a period felt intellectually bright and free from bodily discomfort.

§ 61. *Recurrent high arterial pressure as a cause of angina pectoris.*—The causes of the attacks of angina pectoris in the vast majority of cases are due to temporary increased effort by an impaired heart. It is beyond the scope of my subject to discuss the condition of heart in which pain arises as a symptom. It may, however, be pointed out that hearts damaged evidently in the same way evince symptoms very diverse. This is particularly seen in regard to the symptom of pain. Not only in various forms of cardiac disease does pain appear as a symptom, but hearts similarly affected may or may not give rise to pain, and so far we are utterly at a loss to account for this difference. Still, when it does arise, it is usually on account of a diseased heart being stimulated to increased effort. This may arise in various ways, as from bodily exertion, mental excitement, recurrent increase of arterial pressure, contraction of the cutaneous vessels by exposure to cold. The study of the pulse during attacks of angina pectoris is not always satisfactory, nor is the condition of the pulse constant. One may find the pulse regular or irregular, soft, slow, or increased in rapidity or in hardness. The condition of the pulse during the attack may be modified by the intensity of the pain itself, or by the changes in the heart's action resulting from the stimulus that provoked the attack.

I have already referred to some symptoms evoked by temporary high pressure. This recurring high arterial pressure does induce attacks of angina pectoris in predisposed subjects, by offering increased resistance to the heart's work. I attended an elderly lady five years ago with attacks of fainting, accompanied with a sense of impending death, in whom the pulse was hard, tense, and at times irregular. There was the merest trace of albumin in the urine. With softening of the pulse she gradually recovered. Latterly these attacks occurred with

seizures of intense pain in the chest, lasting for many hours, and always associated with irregularity and slowing of the pulse,




FIG. 48.—Pulse of high arterial pressure from a case of chronic albuminuria.

and by increased arterial pressure (Figs. 48, 49, and 50), and

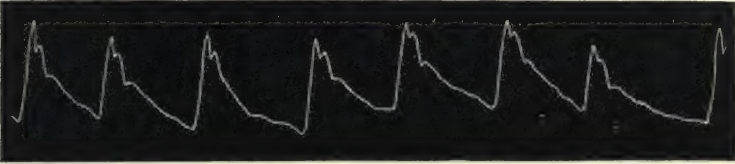


FIG. 49.—Irregular pulse of high arterial pressure during an attack of angina pectoris.

always relieved by lowering of the pressure. She died during an attack of angina pectoris.

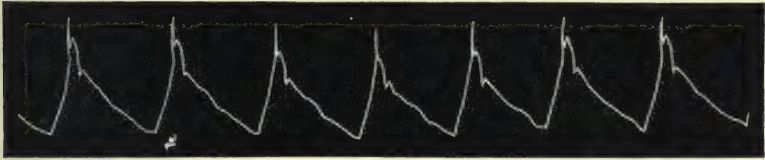


FIG. 50.—Pulse of the same patient after the subsidence of an attack of angina pectoris. The pulse is here regular and felt much softer.

Another case, a female aged seventy-one, who died quite recently, I have found suffering from prolonged attacks of heart pain at irregular intervals during the last five years of her life. The pulse at these times was always hard and irregular. The last attack I saw her in yielded at once on the inhalation of a few drops of nitrite of amyl, the pulse becoming soft and quite regular. Three days later the pain returned, and she died suddenly.

In a few other cases, some with and some without chronic Bright's disease, I have been able to satisfy myself that the attacks of angina pectoris occurred during periods of recurrent high pressure. I have noticed that the attacks then are more gradual in the onset and last for a much longer period than in attacks of angina pectoris from other causes. But more extended observation is needed before I can positively assert this difference.

§ 62. *Vasomotor angina pectoris*.—This form of so-called angina pectoris is yet shrouded in mystery. The term was at first somewhat loosely applied by Cahen<sup>14</sup> and Landois.<sup>15</sup> Nothnagel<sup>16</sup> was supposed, in 1866, to give it precision when he described a series of cases. The symptoms in these cases indicated a period lasting usually some hours, during which the patient was cold and chilly, with lividity of the extremities, and this symptom was attributed to a spasm of the arterioles, such as occurs in Raynaud's disease. After a time this arterial spasm was followed by an attack of angina pectoris. On this evidence the vasomotor group of cases of angina pectoris was supposed to be established. I am of opinion that such cases must be extremely rare. At all events, with a considerable experience of this symptom, I have never seen any one approaching this type, and in a fairly extensive reading of the subject I have never come across the record of a case that could be included in the group. But I am confirmed in this opinion by the fact that many of the so-called cases of vasomotor angina pectoris bear no relation whatever to those cases described by Nothnagel, and the term is now evidently as vaguely applied as before Nothnagel's description. As an illustration I would refer to Powell's article in Allbutt's *System of Medicine*,<sup>17</sup> where he gives cases supposed to be illustrative of this group. Yet one cannot discern any likeness between his description and that of Nothnagel. In one sense the angina pectoris I have referred to as occurring in recurrent increase of arterial pressure may be said to be due to vasomotor spasm. But the symptoms in these cases bear no resemblance to those in the cases described by Nothnagel.

§ 63. *Low arterial pressure*.—A marked difference may be detected in the strength of the pulse of persons of the same age, and evidently in good health. While, on the one hand, a firm resisting pulse may be the characteristic of one individual, and a soft dirotic pulse the characteristic of another, in neither case may it be due to any abnormal condition of the heart or blood. In all likelihood the difference arises from the nature of their development, and each peculiarity is normal to the individual. Nevertheless some difference will be displayed in regard to the reaction of the heart and blood vessels to stimuli, as during exertion. The field of response, speaking generally, will be more extensive in the persons with a normally high arterial pressure than it is in persons with a normally low arterial pressure. As softening of



the pulse with increasing dirotism is the symptom of increasing exhaustion, the normally soft dirotic pulse is, so to speak, already on the way to exhaustion as compared with the pulse of high pressure. In other words, the owner of the soft dirotic pulse is, in running, short-winded. For a few hundred yards he may run as quickly as the owner of the high pulse pressure, but he cannot last half a mile with equal comfort. But a person with a pulse soft and dirotic, though short-winded on violent exertion, yet may endure moderate exertion for as long a period as his equals in age.

§ 64. *Character of the pulse in low arterial pressure.*—The size of the radial artery may vary. It is often large and full, especially when the fall in pressure is not extreme. When the arterial pressure is very low, as in Fig. 52, then the artery is extremely small. The pulse rate is always quickened. The lessened resistance offered to the ventricular contraction invariably reacts on the ventricle, which increases its rate of contraction. I am not concerned in the discussion by what mechanism this is




FIG. 51.—Low arterial pressure during diastolic period (fever and atheroma).

brought about. The fact itself is the main point. But there is no correspondence in the pressure with any given rate, and we find that quick pulses of the same rate have a very wide range of difference in their arterial pressure. The character of the pulse wave as it impinges against the finger is invariably sharp and sudden. The force may vary from the merest flick to a sharp stroke of fair strength. In the latter case, when the pressure is only moderately lowered the pulse wave may be felt for an appreciable interval—slight, but still recognisable. The artery in such cases during the diastolic period still offers some resistance to the compressing finger, and frequently the dirotic wave is well recognised. The prognostic significance of the pulse wave often depends upon the presence of the dirotic wave, or the continued resistance to the compressing finger during the diastolic period, inasmuch as these demonstrate the retention of a certain amount of arterial pressure. The arterial

pressure may fall so low that no resistance is offered to the compressing finger after the wave has passed, and there is a total absence of diastole (Figs. 19 and 51). In extreme weakness of the pulse the wave may simply give a passing flick to the finger, vanishing as suddenly as it appeared. This last



FIG. 52.—Pulse of extremely low arterial pressure from a youth dying of pneumonia.

condition is most typically seen before death from an exhausting illness (Fig. 52), or during the unconsciousness of an attack of syncope (Fig. 20).

§ 65. *Conditions giving rise to low arterial pressure.*—Apart from the conditions in which there is a diminution of the quantity of blood in the system, the abnormal decrease in arterial pressure is almost invariably due to a failure of the muscular wall of the heart to maintain a sufficient distension of the arterial system. This may be due to an inability of the left ventricle to respond to the calls made upon it, or it may be due to inefficiency of the left auricle and right chambers to send a sufficient supply of blood into the left ventricle, as in some cases of mitral stenosis. The original cause of the low pressure in the arteries may be very varied. It may result from valvular disease, or disease of the myocardium, or from other ailments that induce enfeeblement of the myocardium. The heart muscle may strive for a very long time to do its work efficiently, but ultimately its power of response to increased demand becomes impaired, and the arteries relax and, to a certain extent, ease the ventricular efforts, and with this relaxation the fall in the arterial pressure takes place. For a time the heart may keep the circulation going when no great effort is made, but the field of response is greatly contracted. The further developments depend on the cause of the enfeeblement of the heart's muscle. If due to an acute disease, as pneumonia, it may speedily end in dilatation of the chamber and failure of the heart. If due to some valvular defect, with rest and appropriate treatment a certain amount of strength may be restored to the failing organ. Other causes, such as muscle failure from alcoholism, from overwork, from sexual excess, from long-continued struggle

against high arterial pressure, finally induces diminished arterial pressure. For the recognition of the cause of the diminished pressure, the previous history of the patient will have to be relied upon. It is possible that a form of vasomotor paralysis may induce a lowering of the arterial pressure, but my experience does not include the recognition of such an instance.

§ 66. *Symptoms associated with low arterial pressure.*—These symptoms may be summed up in the statement that there is a limitation of the field of cardiac response. This not only applies to the conscious efforts of the individual, but also to performance of the functions of the various organs. When the pressure is much reduced bodily effort is early restricted by the occurrence of breathlessness or the sensation of fatigue. Free perspiration and a sense of bodily warmth are sometimes present. Mental effort is similarly restricted by the sense of fatigue, and there is febleness of the memory for retaining new facts and inability to evolve fresh ideas. The functions of other organs are sluggishly performed, the urine becomes scantier, and the digestion is distinctly impaired. Not only is this directly due to a deficiency in the supply of fresh arterial blood to the organ, but it may be in a measure due to the stagnation of the current of venous blood. This may again be due either to the inefficiency of the heart to propel the blood with due energy through the organ, or it may be due to the distended right heart forcing a portion of the blood back into the venous system. Thus one often detects in cardiac failure a noted increase in the size of the liver, which may even pulsate as each wave is sent back from the heart.

In regard to the heart itself the fall in pressure is an evidence of its failing power, and but marks the degree to which the heart failure has reached. The enfeeblement of the muscle which causes the low pressure in the artery steadily proceeds, and dilatation of the various cavities gradually follows. The dilating walls no longer completely empty the chambers, the amount of residual blood increases, and embarrassment of the contracting muscle follows. If the condition is an unrecoverable one, as in valvular disease, the ultimate result is over distension of the organ, to such a degree indeed that the thin walled auricles may be so distended that they become mere membranous bags with ineffective muscular fibres scattered over them.

§ 67. *The pulse in syncope.*—I have had several opportunities



of observing the pulse during attacks of fainting. Usually there is extreme lowering of the blood pressure, the heart beating with great feebleness, as is shown in the tracings, Figs. 20 and 21. In rare cases I have found the pulse become very slow, the individual beats being large and full. Fig. 53 shows the pulse

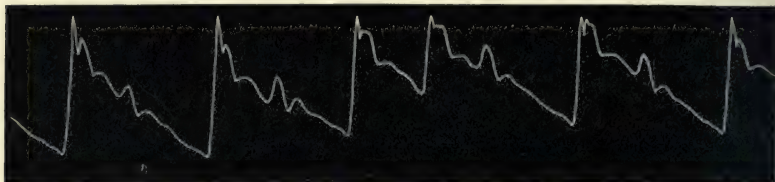


FIG. 53.—Slow irregular pulse during an attack of syncope. The patient was barely conscious when the tracing was taken.

of a man who had barely recovered consciousness. During unconsciousness the pulse felt slower than is shown in this tracing. Here the slow pulse is due to the fact that imperfect systoles of the ventricle occurred, and the resultant pulse wave, though very evident in the tracing, was too small for the finger to perceive. With returning consciousness the beats increased in force and the pulse gradually became more regular (Fig. 54).




FIG. 54.—As the patient regained consciousness the pulse tracing became more regular, as in this tracing.

## CHAPTER IX

### PULSE IRREGULARITY

§ 68. Classification of irregularities.

(A) The youthful type of irregularity :

69. Relation of rate to rhythm.
70. Irregularity with natural slowing of the pulse.
71. Irregularity after fever.
72. Conditions in which the youthful type of irregularity occurs.

(B) The adult type of irregularity :

73. The features characteristic of the adult type of irregularity.
74. Experimental evidence of pulse irregularity.
75. Distinction between the youthful and adult type of irregularity.
76. Descriptive terms.
77. The effect of the premature systole on the apex beat.
78. Auscultation of the heart during an irregular period.
79. Rhythmical irregularities of the pulse.
80. The strong pulse beat after the irregularity.
81. The dropped beat.
82. The dropped beat causing an infrequent pulse.
83. What is the right side of the heart doing during these irregularities ?
84. The premature systole occurring in groups.
85. The factors determining the presence of the premature pulse beat.
86. Some exceptional forms of irregularity.
87. Mixed irregularities.

§ 68. *Classification of irregularities.*—There are no deviations from the normal characters of the pulse so easy to recognise as irregularities in the rhythm, and yet there are no other abnormalities whose symptoms are so surrounded by mystery, whose description in medical literature is so hopelessly confused, and whose diagnostic significance is so completely misunderstood.

When a collection is made of a great number of tracings of pulse irregularities, one finds a great variety of forms, and there are several ways in which they can be classified—none of them quite satisfactory. The classification I adopt here is far from ideal, but it seems to me the most convenient with our present

knowledge of the subject. When a more thorough knowledge is acquired of the causes of the irregularity and the participation of the various chambers of the heart in the irregularity, a new arrangement will be necessary. For this latter purpose the study of the venous pulse will be of great value, and I have entered somewhat fully into this aspect of the question in a later chapter. Extensive as my observations have been, yet many more are required before a final arrangement can be adopted. In this chapter the subject will be mainly studied from the point of view of what the left ventricle reveals.

The following classification has the justification that it recognises not only certain well-marked differences, but tends to indicate the significance of the different forms. The manner in which I arrived at it was by carefully measuring the duration of the ventricular systole, or rather that period of the ventricular systole when the aortic valves are open, and the ventricular outflow directly affects the pulse. It is evident that most irregularities resolve themselves into variations in the duration of the period of ventricular diastole. The question arose in my mind, Did the duration of the ventricular systole afford any help in understanding this subject? I found that the vast majority of cases could be divided into two groups, namely—those where the duration of the systole was regular, and those where it was of variable duration. Pursuing my inquiries into the conditions of the patients in whom it occurred, I found that the great majority of patients belonging to the first group occurred in the young before puberty, while with rare exceptions those belonging to the second group were adults.

I therefore divide the irregular pulse into two groups: (A) the youthful type of irregularity, where the irregularity occurs through variation in the duration of the diastolic period of the cardiac cycle; and (B), the adult type of irregularity, where there is a variation in the duration of the systolic period as well as in the diastolic period of the cardiac cycle.

#### (A) THE YOUTHFUL TYPE OF IRREGULARITY

§ 69. *Relation of rate to rhythm.*—There is a much greater constancy in the duration of the systolic period of the ventricular action than there is of the diastolic. With quickening of the pulse rate the shortening of the period of the cardiac cycle takes



place almost entirely at the expense of the diastolic period. In the youthful form of irregularity it is variations in the duration of the diastolic period that is the chief characteristic. In the quickened pulse we find the duration of the diastole reduced to a minimum, so that we do not find the youthful type of irregularity to occur. But it is when the heart gradually slows in its action that the tendency to this irregularity is manifested. There are two conditions in which this form of irregularity is very prone to arise—namely, when the pulse is slowing after infancy, and when the pulse is slowing after a febrile attack.

§ 70. *Irregularity with natural slowing of the pulse.*—During infancy the pulse beats are very rapid. At birth they run about one hundred and twenty per minute. As years advance the pulse-rate becomes slower, till about eight or nine years, often earlier, the pulse-rate falls to eighty or ninety per minute,




FIG. 55.—Youthful type of irregularity, showing the regular duration of the systolic period, *E*, and marked variation in the diastolic period, *G*, from a girl aged eleven years.

occasionally falling even to seventy. When this last condition arises there is a marked tendency for the diastolic period of the pulse to vary. If, for instance, Fig. 55 be considered, it will be found that the systolic period (*E*) presents great uniformity in character and in duration, while the duration of the diastolic period (*G*) is extremely variable. This lengthening of the diastolic period *G* is sometimes so great that the suspicion arises that a ventricular beat has failed to reach the wrist,—a missed beat. But examination of the heart sounds and apex beat at such a period shows that such a thing does not occur. In

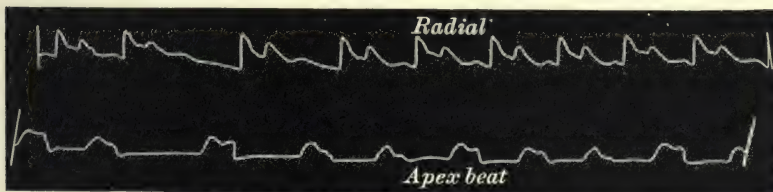


FIG. 56.—Simultaneous tracings of the radial pulse and of the apex beat, showing their agreement in rhythm, and the absence of an imperfect systole during the long pause in the radial pulse.

Fig. 56 the apex beat is taken at the same time as the radial pulse, and the irregular rhythm of the pulse corresponds exactly



§ 72. *Conditions in which the youthful type of irregularity occurs.*—I have examined a large number of children and watched a certain number for considerable periods, and I have come to the conclusion that all children at some time or other present this form of irregularity. It is not only frequent in them in the slowing pulse after fever, but it may be looked upon as a natural result of the slowing pulse in advancing years. It seems to be most frequent from eight to fifteen years, becoming rarer towards puberty. I have found it persist in after life in only a very few cases. In children the least excitement quickens the pulse, with, as a consequence, a disappearance of the irregularity. I have often found it take on a respiratory rhythm, and no doubt some cases are due to respiration. This will be illustrated when dealing with the pulse and respiration (§ 137, Fig. 166). It is well known that the pulse becomes irregular in tuberculous meningitis. I have not been successful in getting a tracing of an irregular pulse in a child in this disease, nor have I been able to find one in such medical literature that I have examined. I am therefore unable to say if the irregular pulse in tuberculous meningitis is of this type. In an adult dying from tuberculous meningitis I found the irregular pulse to be of the youthful type (Fig. 137).

In a well-marked case of tetany the pulse was very irregular, and I got a tracing which is of this characteristic type, Fig. 60.



FIG. 60.—Irregular pulse of the youthful type from a child aged four suffering from tetany.

In a very extensive examination of children's pulses I have only found two or three instances where the pulse irregularity was of the adult type. When the irregularity did occur it was only for one beat at long intervals. In none of these exceptions could the individual be considered healthy. In advanced heart disease the pulse of children is often irregular, and it then assumes the same character as it does in adults.

#### (B) THE ADULT TYPE OF IRREGULARITY

§ 73. *The features characteristic of the adult type of irregularity.*—The essential feature of this form of irregularity is the



early occurrence of a ventricular systole followed by a prolonged diastolic period. Thus if we take Fig 61 we find that after the



FIG. 61.—Irregular pulse of the adult type, showing a small pulse wave due to the early occurrence of a ventricular systole, followed by a diastolic period longer than usual.

third beat in the tracing the diastolic period is very short, being interrupted by a small triangular wave. This wave in the pulse tracing represents an early occurring systole producing an evidently imperfect pulse wave. This small imperfect beat is followed by a diastolic period much longer than usual.

§ 74. *Experimental evidence of pulse irregularity.*—In order fully to appreciate the significance of the imperfect pulse beat it will be better if, before examining the clinical evidence as to the nature of the adult irregular pulse, the evidence of experi-

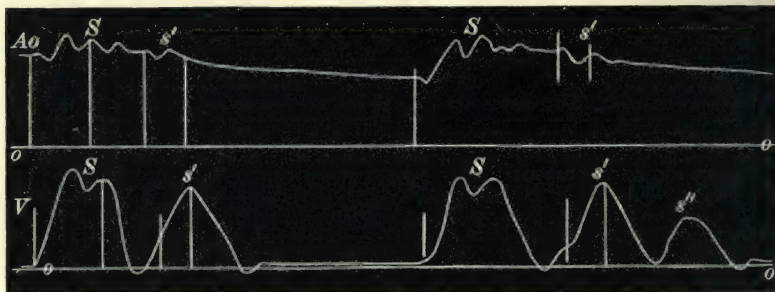


FIG. 62.—Simultaneous tracings of the pressure within the aorta and within the ventricle, showing the slight increase of pressure  $s'$  in the aorta due to the early occurrence of an imperfect systole of the ventricle  $s'$ , and the absence of any effect on the aortic tracing corresponding to the imperfect ventricular systole  $s''$  (Hürthle).<sup>18</sup>

mental observation is first considered. In Fig. 62 there is a record of the pressure within the aorta and of the pressure within the ventricle taken at the same time. The pressure within the aorta is always maintained high above the base line  $o$ , that within the ventricle falling below it at the end of diastole. At  $S$  and  $S'$  we have complete ventricular systoles giving rise to complete pulse waves in the aorta, and the character of the pulse wave in the aorta agrees with the character of the pressure within the ventricles during the period that the aortic valves are open. After the first full ventricular systole  $S$

a smaller systolic wave  $s'$  occurs in the tracing of the ventricular pressure. This wave is not so forcible, and causes only a slight wave  $s'$  in the aortic tracing. Following this imperfect wave there is a long pause terminated by the appearance of another full systolic beat. Following the second full ventricular systole is another early occurring imperfect beat  $s'$ , which makes but a slight impression  $s'$  on the aortic tracing. This imperfect systole is followed by another imperfect systole  $s''$ , but so weak is it that it does not affect the aortic pressure. From such a tracing as this it can be inferred that in the pulse tracing, Fig. 61, the small pulse wave was due to an early occurring systole, so weak that it was unable to propagate a full pulse wave. When the ventricular systole is so weak that it fails to raise the aortic valves, as in the case of the wave  $s''$ , Fig 62, we have a missed beat. The occurrence of an ineffective ventricular systole is well seen in Fig. 63. Here also the ventricular and aortic pressures were




FIG. 63.—Simultaneous tracings of the ventricular and aortic pressures, showing early weak ventricular systoles. The dotted line represents the height the ventricular pressure has to reach before the aortic valves can be opened (Marey).<sup>19</sup>

registered simultaneously. The dotted line shows the height the ventricular pressure has to reach before the aortic valves can be opened. Every second beat of the ventricle is so slight that it fails to reach the height necessary to open the aortic valves, and consequently there is no sign of its presence in the aortic tracings.

From these two figures it is seen that the small imperfect beat of an irregular pulse is due to an incomplete ventricular systole, and that when there is a missed beat it is due to the inability of the imperfect ventricular systole to overcome the aortic pressure.

§ 75. *Distinction between the youthful and adult type of irregularity.*—I have already defined the youthful form of irregular pulse as showing variations in the duration of the diastolic period, the long pauses being always preceded by a full and complete pulse wave. I may now go further and state that there is never an incomplete ventricular systole as shown in Figs 62 and 63. On the other hand, the adult form is characterised by the occurrence of early imperfect systoles followed by long pauses. If these early occurring imperfect systoles are of sufficient strength to open the aortic valves, then we have an irregular pulse where the long pause is preceded by a small imperfect pulse wave. If these imperfect systoles have not sufficient strength to open the aortic valves, then we have the pulse irregularity characterised by a dropped beat. The vast majority of pulse irregularities in adults correspond to these two conditions. Other irregularities are mostly due to these early imperfect systoles occurring in groups, or to their being of varying strength. But however various the combinations may be, the adult form of pulse irregularity is due to the earlier occurrence of a ventricular systole usually imperfect.

§ 76. *Descriptive terms.*—For the purpose of description I had employed in my earlier papers the term “early occurring imperfect systole,” to describe the action of the ventricle at this irregular period, inasmuch as the ventricle contracts sooner, and the pulse wave is rarely so full as after a regular ventricular systole. In describing this systole, Wenckebach<sup>20</sup> had used the term “extra systole,” following Marey. Cushny<sup>21</sup> has used the term “premature systole.” In order to avoid the multiplication of names I shall in future employ Cushny’s term and refer to this systole of the ventricle as “the premature systole,” and to the resulting pulse wave as the “premature pulse beat.” When a premature systole occurs after a full beat it is generally followed by a pause longer than usual before the occurrence of the next full beat. The imperfect pulse wave with its preceding full beat are spoken of sometimes as linked beats, or as the pulsus bigeminus, the latter term first used by Traube.<sup>22</sup> When reference therefore is made to the bigeminal irregularity this form will be meant.

§ 77. *The effect of the premature systole on the apex beat.*—That this imperfect pulse wave is due to the systole of the ventricle can be demonstrated by examining the heart at the



time that the irregularity occurs. If there be a well marked apex beat present the finger laid on it perceives the earlier occurrence of a slight beat followed by a long pause at the time that the irregularity occurs in the pulse. Fig. 64 is a tracing




FIG. 64.—Simultaneous tracings of the apex beat and of the radial pulse. The waves *s'* are the effects of the premature ventricular systole on the apex beat and radial pulse.

of the radial pulse where a premature beat *s'* occurs at regular intervals after every second full beat. In Fig. 65 the imperfect pulse beat occurs with one exception after every single full beat. At the same time that the radial pulse was registered, a tracing




FIG. 65.—Simultaneous tracings of the apex beat and of the radial pulse, showing the occurrence of a well-marked premature apex beat *s'*, with a very small premature wave *s'* in the radial pulse.

of the apex beat was taken in both these cases. It will be observed that the apex tracing presents exactly the same irregularity as the radial pulse. This point is of importance, for it has been suggested that the small premature beat of the pulsus




FIG. 66.—Tracing of a radial pulse with a dicrotic wave *d*, so large as to resemble a premature pulse beat.

bigeminus was but an exaggerated dicrotic wave. Thus in Fig. 66 there is a dicrotic wave, *d*, so large that the suspicion might arise that it might be a premature pulse beat, being of the same nature as the small waves in Figs. 71 and 72. Apart from the fact that in these last two tracings the wave occurs some

distance from the aortic notch, while in Fig. 66 it follows immediately, the study of the heart sounds and of the apex beat showed that there was no premature systole. Thus Fig. 56 was taken from the same patient and at the same examination that Fig. 66 was obtained, and though in the tracing the dicrotic wave is not so big, the harmony of the apex beat and the radial pulse further demonstrates the true significance of the dicrotic wave in Fig. 66.

§ 78. *Auscultation of the heart during an irregular period.*—If one carefully auscultates the heart during this period of irregularity one can recognise a correspondence between the



FIG. 67.—Diagrammatic representation of the sounds heard during the occasional irregularity of the pulse. 1 and 2 represent the first and second sounds of the heart.

heart sounds and the irregular pulse. The heart sounds at first seem to occur so rapidly that one gets the impression that the heart is “tumbling,” and it has

been described in this and other equally indefinite ways. But if one carefully listens, particularly when the heart is beating slowly, the various sounds of the heart can be readily differentiated. As a matter of fact the “tumbling” sounds are nothing more nor less than the first and second sounds of the heart occurring very shortly after the preceding second sound. Thus one might represent them diagrammatically as in Fig. 67.

If cases with either a systolic or diastolic murmur be carefully auscultated, the occurrence of the murmur, with the short rapidly occurring sounds of the bigeminal beat, can often




FIG. 68.—Diagrammatic representation of the sounds heard during a premature systole of the ventricle when there was a systolic mitral murmur present.

be recognised. With a systolic murmur we can make out the sounds as in Fig. 68.

Such were the sounds heard in the case from whom the tracing Fig. 61 was taken. Fig. 69 is from a patient with aortic regurgitation. The diastolic murmur heard in this case could be readily detected following the second of the two short beats, as in Fig. 70.

In many cases the sounds are so faint that it is difficult to differentiate them, and they may even be absent when the premature systole is exceptionally feeble.




FIG. 69.—Shows occasional premature beats.



FIG. 70.—Diagrammatic representation of the sounds heard during a premature systole when there was a diastolic aortic murmur.

§ 79. *Rhythmical irregularities of the pulse.*—In a certain number of cases there is a tendency for the heart to take on a




FIG. 71.—Tracing of a bigeminal pulse.

rhythm with the early occurring systole appearing at regular intervals. Thus in Figs. 71 and 72 there is a premature systole

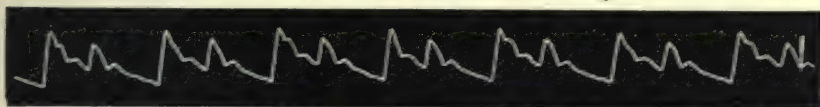


FIG. 72.—Tracing of a bigeminal pulse.

after each full beat, so that to the touch the small beat appeared like an echo of the preceding full beat. The heart sounds in



FIG. 73.—Diagrammatic representation of the sounds of the heart in a case of such rhythmical irregularity as is represented in Figs. 72 and 73.

such a case can be made out to follow the same irregularity (Fig. 73).



Rarely one may feel the second beat nearly as large as the full beat. In such a case the two beats seem linked together, being separated from the preceding and succeeding two beats by a longer pause. Such a pulse has been called the pulsus alternans. It is essentially of the same nature as the pulsus bigeminus, and sometimes can be found to alternate with it in the same individual. In Fig. 74 the pulsus alternans is repre-




FIG. 74.—Simultaneous tracings of the apex beat and radial pulse, showing the rhythmical irregularity when the two beats of nearly the same size are linked together (pulsus alternans).

sented with a tracing of the apex beat. The absence of a dicrotic wave might have given rise to the suspicion that the smaller of the two beats was but an exaggerated dicrotic wave. The presence, however, of a distinct apex beat determines its true nature.

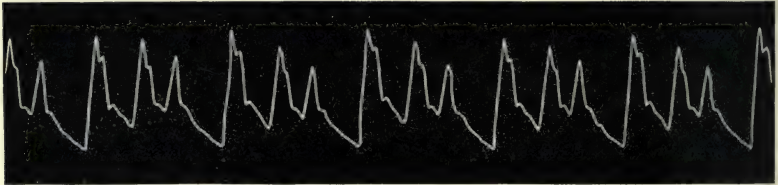


FIG. 75.—Rhythmical irregularity with the premature pulse wave after every second full pulse wave.

A considerable variety of other rhythmical irregularities which occur can be demonstrated. Thus in Fig. 75 the early systole occurs after every second beat. In Fig. 76 it occurs

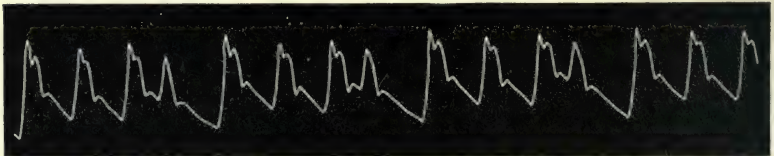


FIG. 76.—The premature beat occurs after every third full beat.

after every third beat, and in Fig. 77 after every fourth beat. In Fig. 78 there is a curious variation. Here there are

two beats linked together alternating with three beats linked together. This is well made out in examining the apex tracing.

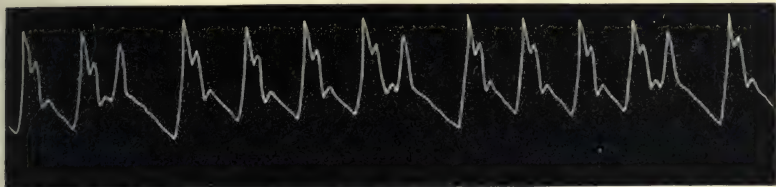


FIG. 77.—The premature beat occurs after every fourth full beat.

When the three beats occur together, the last of the three beats scarcely makes a perceptible rise in the pulse tracing, and might be overlooked were it not that the accompanying apex tracing shows the true meaning. It bears a striking resemblance to the irregularity in Fig. 62, obtained in experimental stimulation of the heart.

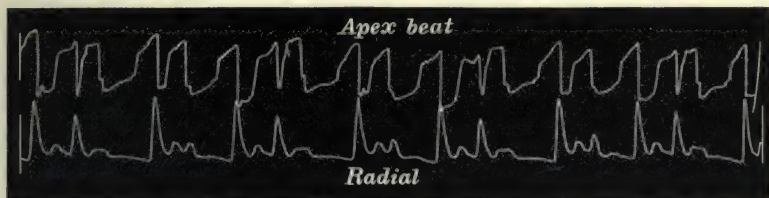


FIG. 78.—Simultaneous tracings of the apex beat and of the radial pulse, showing the alternate occurrence of two and three linked beats. The last of the three linked beats can scarcely be perceived in the radial tracing.

§ 80. *The strong pulse beat after the irregularity.*—In many of these tracings the first beat after an irregularity seems larger than the other full beats, on account of the fact that during the long pause the arterial pressure has sunk very low, as is well seen in Fig. 61, and the next oncoming wave meeting with less resistance causes then a high upstroke. Sometimes the wave is actually larger and fuller, and here evidently the ventricle has accumulated more blood and regained sufficient vigour during the long pause to send a larger wave into the arteries. In occasional irregularities patients are often conscious of the beat, as the ventricle gives a strong shock to the chest wall.

§ 81. *The dropped beat.*—In many cases the finger fails to recognise the small pulse beat due to an early occurring systole. In such cases it is usual to assume that either the heart has missed a beat, or that it has sent on a wave too small to be

recognised. What usually happens is that the ventricle has made a premature systole, but the force has been so small that it has not been able to overcome the pressure in the aorta and open the aortic valves, or that having done so, the wave of blood sent forth has not been of sufficient strength to be felt by the finger. The duration of the period including the long pause and the preceding beat will often be found to correspond accurately to two cardiac cycles, as represented by two beats of the pulse. In the tracing, Fig. 79, there are two dropped beats, the radial pulse showing no sign whatever of a beat when examined by the finger. In the tracing there is a slight prolongation of the diastolic wave at the irregular period, which may be assumed to be due to a minute premature beat occurring at that period. If the apex tracing taken at the same time be examined, it will be

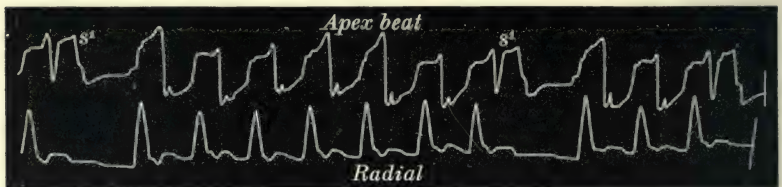


FIG. 79.—Simultaneous tracings of the apex beat and of the radial pulse, showing the occurrence of a premature apex beat ( $s'$ ) during a pause in the radial pulse.

found that the ventricle did make a contraction at that period ( $s'$ ). If the heart be auscultated there will be heard the two short, sharp sounds, as already described, occurring at the beginning of the long pause, and caused by the rapid premature systole of the ventricle. When the apex beat is absent the presence of these sounds will often reveal the true nature of the delay in the pulse. Occasionally, however, it happens that the ventricular systole has not sufficient strength to raise the aortic valves, and then only the faint, muffled sound may be detected corresponding to the first sound. Sometimes even this may be absent.

§ 82. *The dropped beat causing an infrequent pulse.*—In a pulse becoming periodically irregular after each beat, the ventricular contraction may be so ineffective that the pulse may be no longer recognisable either by the finger or by the sphygmograph. Here, doubtless, during the long pauses the ventricle contracts, but so feebly that little or no effect is made upon the arterial pressure. In cases where the apex beat is perceptible



a double beat is obtained when only one pulse beat is felt. Thus in Fig. 80 the pulse counted thirty to the minute, the

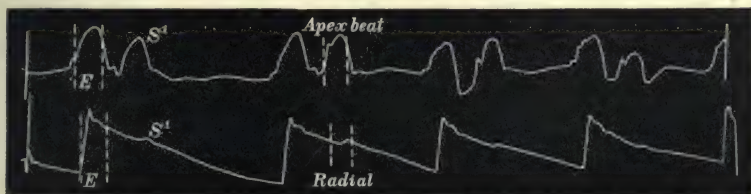


FIG. 80.—Simultaneous tracings of the apex beat and radial pulse. While the two linked beats are distinct in the apex tracing, the pulse wave corresponding to the premature systole is imperceptible to the finger, but a slight rise  $S'$  indicates its presence in the tracing.

finger being incapable of recognising the slight pulse wave evident in the tracing. But when the apex beat was examined two distinct beats could be felt occurring between each long pause. These beats are very well marked in the tracing. Here there is no doubt the left ventricle contracted prematurely after a very short pause, but the contraction was so slight that it failed to send a wave of blood of such strength that the finger could recognise, so that instead of a rate of thirty per minute the

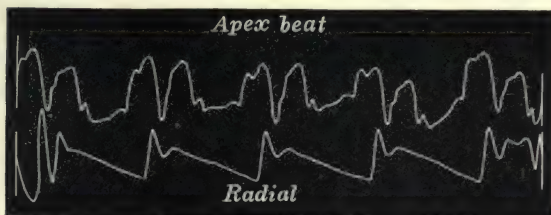


FIG. 81.—Simultaneous tracings of the apex beat and of the radial pulse. There are two beats of the apex to one radial pulse.

heart was actually contracting at double that speed. Fig. 81 represents another instance of the infrequent pulse. Here the pulse rate varied from thirty to thirty-six. Neither the finger nor the sphygmograph revealed the slightest evidence of a second beat. There was in this case a well-marked apex beat, and here again two apex beats were found to occur for each pulse beat. Several other instances of this form of irregularity are given in § 224, showing the participation of the right ventricle in the irregularity.

From these instances it may confidently be asserted that during the period when a beat is missed from the pulse, there

has taken place in the left ventricle an early contraction, but the corresponding pulse wave has failed to reach the wrist; further, that the infrequent pulse in numerous cases arises from the fact that every second contraction of the left ventricle occurs early, and is too feeble to cause a variation in the arterial pressure of sufficient strength to be perceptible by the finger in the radial artery.

§ 83. *What is the right side of the heart doing during these irregularities?*—We have had evidence of the participation of the left ventricle, but so far we have had no evidence of what the other chambers of the heart are doing. I may say at once we possess no direct evidence of what the left auricle does under these circumstances, but from certain observations we may infer that it acts in a manner similar to the right auricle (§ 222). In suitable cases we can distinctly recognise movements due to the right auricle and right ventricle. An inquiry into this aspect of cardiac irregularity is not only interesting and instructive in itself, but it helps to explain much that has been obscure in the movements of the heart. Many observers have imagined that the left heart stood still while the right continued to act, because they have detected a missed beat in the pulse, and at the same time have felt a diminished impulse of the heart. The study of the foregoing tracings demonstrates this idea of a hemisystole to be erroneous. The tracings of the apex beat show that the left ventricle really did act during the pause in the pulse. The diminished movement of the heart was in reality an imperfect systole of the left ventricle. It is rarely possible to demonstrate the movements of the right ventricle from the movements of the chest wall. Just as the arterial pulse is a guide to the rate and rhythm of the left ventricle, so, in suitable cases, the jugular and liver pulses are good guides to the rate and rhythm of the right ventricle and right auricle. I shall here anticipate a discussion carried out in more detail later on, where the evidence offered by the liver and jugular pulses in heart irregularity is dealt with, by stating that in the great majority of instances the ventricles can be demonstrated to act in harmony, and that the auricles may retain their regularity during irregular action of the ventricle, or they may participate in the irregularity.

§ 84. *The premature systole occurring in groups.*—So far the consideration of the irregular pulse of the adult type has been devoted to that form where the premature systole of the ventricle

occurs singly. It has been demonstrated that when the experimental stimulation of the heart is continuous and of sufficient strength, there is then evoked a series of small ventricular contractions following one another with great rapidity. In many cases the pulse irregularity in man is characterised by the




FIG. 82.—Rhythmical irregularity, showing two premature beats following each full beat.

occurrence of these small premature beats running together in groups. In Fig. 82 these occur regularly in groups of two small beats after each full beat. This is sometimes called the *pulsus trigeminus*. It is to be noted that this form of pulse differs from Figs. 64 and 75, inasmuch as in these tracings the

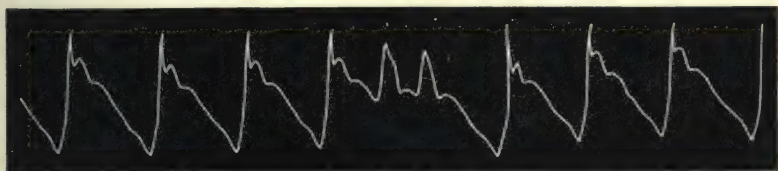


FIG. 83.—Showing a group of two premature pulse beats.

premature systoles are single and occur regularly after every second full systole, whereas here there are two premature systoles occurring after every full systole. Fig. 83 shows the occasional occurrence of two premature systoles together. The following series of five tracings from the same patient illustrate




FIG. 84.—This and the following four tracings are from the same patient. This tracing was taken during a period when the heart was beating regularly. The jugular pulse is analysed in § 237.

the passage of occasional premature systoles into a long series of premature systoles. For the present the jugular pulse is not considered. In Fig. 84 the pulse is quite regular. In Fig. 85 there is shown an occasional intermission of the pulse. The four regular beats in the middle of the tracing are full beats.



In Fig. 86 the intermission occurs after every second beat. This tracing has the deceptive appearance of a pulsus bigeminus,




FIG. 85.—The radial tracing shows occasional missed beats. The four beats in the centre are full and regular beats.

but the two beats are full beats, and during the pause a ventricular systole took place which is only represented by the notch  $n'$ .

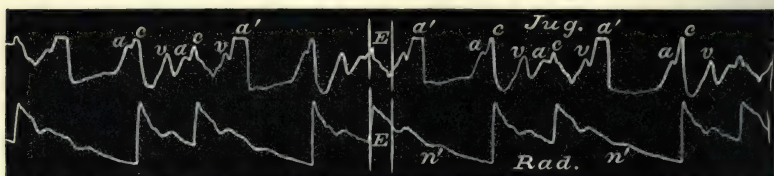


FIG. 86.—The radial tracing shows that every third beat is missed, being represented only by the notch  $n'$ .

In Fig. 87 there are two full beats in the centre of the tracing, while all the others are premature systoles. The premature

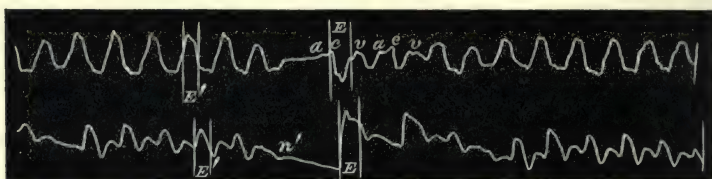


FIG. 87.—The radial tracing shows two full beats in the centre of the tracing, all the others being premature beats. The beat preceding the full beat  $E$  is represented only by the notch  $n'$ .

systole preceding the full beats is represented only by the notch  $n'$ , as in Fig. 86. In Fig. 88 there is one full beat  $E$ , followed

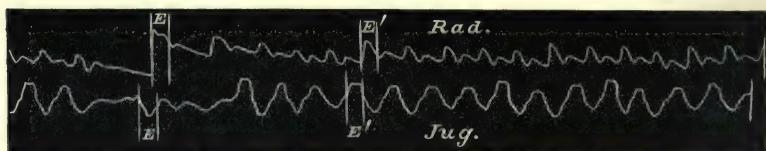


FIG. 88.—The radial tracing shows only one full beat  $E$ . The other beats are due to premature systoles.

by a long series of premature systoles. This series of premature systoles I shall later suggest show the nature of paroxysmal

tachycardia. Fig. 89 shows a group of three premature systoles after the first full beat. In the remainder of the tracing a premature systole has evidently occurred after each full beat,

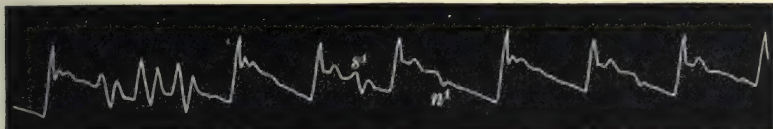


FIG. 89.—The premature beats occur in one group of three, and singly  $s'$ , at times scarcely making an impression in the tracing beyond the notch  $n'$ .

but it is only occasionally represented in the tracing by a slight wave  $s'$ , or by a slight depression  $n'$ . In Fig. 90 similar irregularities, occurring with great rapidity, present a pulse of the most extreme type of irregularity. The apex tracings taken at the same time reveal the true nature of the long pauses, and one can recognise that the irregularities are due entirely to premature systoles occurring singly and in groups, the systoles interrupting the diastoles at different periods in the cardiac cycle, so that at times no pulse wave is perceptible.

From the study of these tracings it will be seen that the adult type of irregularity is made up of the occurrence of premature systoles singly (giving rise to the pulsus bigeminus or to the dropped beat) in groups or in a mixture of these different forms. An irregular pulse, therefore, is due to stimulation of the heart before the termination of the normal diastole, such stimulation being either momentary (pulsus bigeminus and pulsus intermittens) or lasting for a longer period (groups of premature beats).

§ 85. *The factors determining the presence of the premature pulse beat.*—In many cases there is absolutely no indication of the premature systoles in the radial tracing (Fig. 81). At times it is represented only by the notch  $n'$  in Figs. 86 and 89. It would seem that in the latter cases the ventricular systole has not had sufficient strength to send on a positive wave, but by the relaxation of the ventricular muscle, as already explained (§ 13, *b*), a negative wave is propagated, causing the depression  $n'$  in Figs. 86 and 89. At other times the ventricular systole has been of sufficient strength to send forth a small wave, as in Fig. 80. It is interesting to note the relationship of the pulse beat to the apex beat in such cases. It will be found, for instance, in Fig. 80, that the premature apex beat occurs before its pulse beat earlier than

## PULSE IRREGULARITY

the normal full beat occurs before its corresponding pulse beat *E*. On the other hand, the cessation of the pulse wave bears the same relationship to the apex beat in both cases. Manifestly the reason is that the premature systole, occurring earlier, is not so strong as the full-timed systole, and has, besides, to overcome a higher aortic pressure; hence, the premature systole is unable to raise the aortic valves till near the end of its systole, and thus a delay in the appearance of the pulse ensues. This relationship of a small pulse wave to a premature apex beat is also well seen in Figs. 65 and 78. On the other hand, where there is a fair-sized premature pulse beat it will be found to present the usual relationship to the apex beat (Figs. 64 and 74). It can therefore be assumed that the presence of a pulse wave corresponding to a premature systole of the ventricle depends on three conditions—viz. the strength of the ventricular contraction, the quantity of blood in the ventricle, and the blood pressure in the aorta. These factors again depend on the period in diastole at which the ventricle is stimulated to contract.

§ 86. *Some exceptional forms of irregularity.*—The irregularities included in the adult group have been shown to be caused by a premature systole of the left ventricle, occurring singly or in groups, and the pulse wave resulting from such premature contractions may or may not have been perceptible at the wrist. In nearly every instance given, there has been shown a pause after the premature beat when it occurs singly, as long or more often longer than the pause following a full beat. This prolonged pause after the premature beat is well seen also in the experimental instances given in Figs. 62 and 63, and will be shown later in Figs. 316 and 317. In rare cases we find that the pause after the premature beat is shorter than normal. Such an instance is shown in Fig. 54. Here there are premature beats after the first



FIG. 90.—Simultaneous tracings of the apex beat and of the radial pulse, showing premature systoles occurring singly and in groups, some of the beats failing to reach the radial.



and third full beats in the tracing. The pause after these is distinctly shorter than the pause after the other full beats.

In Fig. 91 there is a smaller beat  $s'$  after every full beat  $s$ , and the tracing resembles an ordinary bigeminal pulse, with the

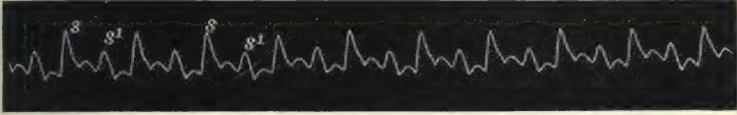


FIG. 91.—Shows the occurrence of an imperfect pulse wave  $s'$  regularly after each full beat  $s$ , with a shortening of the diastolic period after the imperfect beat  $s'$  (from a patient with paroxysmal tachycardia after an attack had lasted 66 hours. Case 7, § 108).

exception that there is no prolonged pause after the smaller beat  $s'$ . Such pulses as these, however, are extremely rare, and I cannot tell what the significance may be. They form exceptions to the rule formulated by physiologists, that when the heart is stimulated to premature contraction the diastolic period following is prolonged. Another form of exceptional irregularity is when a smaller ventricular systole occurs, followed by a correspondingly shorter diastolic period, as in Fig. 92.

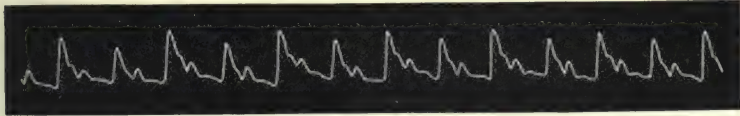


FIG. 92.—Rhythmical irregularity with every second pulse wave smaller but complete, and followed by a shorter diastolic period.

This may be of the same nature as Fig. 91, but I give it separately, as the lesser beat shows as complete a wave as the larger beat. It differs also from the tracing Fig. 74, inasmuch as there the pause is longer after the small beat. Occasionally, one finds a small beat occurring at the usual interval. I have found this occur most commonly in the irregularity consequent upon advanced mitral disease, as in Fig. 296. But as the irregularity in this condition presents a variety of unusual forms, I deal with it separately (Chapter XXVIII). Occasionally I have found a small pulse wave occurring at the regular interval in febrile cases, and then it has been of very ominous significance (Fig. 100). While the study of the pulse tracing will generally give us accurate information of what is happening in the heart, it is not always safe to assume that what we expect is really happening. Thus in Fig. 93 the pulse tracing shows long pauses, and in one case a premature pulse wave  $s'$ , with a corre-

sponding apex beat. During the preceding long pause there is no pulse wave, while there is a distinct apex beat. Here no doubt the ventricular systole was not of sufficient strength to propagate




FIG. 93.—Simultaneous tracings of the apex beat and of the radial pulse, showing a pause in the apex beat with a pause in the radial (*x*), a premature beat of the apex with no corresponding pulse beat, and a premature beat of the apex with a premature pulse beat *s*.

a pulse wave to the radial artery. But in the long pause *x* preceding this, there is no beat either of the apex or of the pulse. Had one to interpret only from the pulse tracing, no reliable conclusions could have been arrived at as to what was happening to the left ventricle.

While taking tracings at different times from the patient with the bigeminal pulse (Fig. 72), the pulse would sometimes alter, becoming infrequent, like the tracing Fig. 94. In studying




FIG. 94.—Tracing of an infrequent pulse. The long pause is occasionally interrupted by a premature beat.

this tracing, one finds that there is a long pause interrupted occasionally by a small premature beat. It would seem reasonable to argue that here a premature systole occurred during the long pauses, but it was not of sufficient strength to propagate a wave to the radial. This would seem all the more reasonable when one finds that the time occupied by the full pulse beat and long pause agrees exactly with the period occupied by the full pulse beat and the premature beat and their pauses, in this tracing and in Fig. 72. As a matter of fact, the heart did not contract during this pause, and all the chambers of the heart had the same rhythm as is shown in this tracing. This will be more fully explained after describing the venous pulse (see § 217).

Some other forms of irregularity dependent upon the movements of respirations are given in Chapter XV.

§ 87. *Mixed irregularities.*—In some patients, where the heart is apt to exhibit the irregularities so frequent in advanced life, the youthful type may occasionally be detected for a few beats. Generally there occurs an imperfect systole, as in the last beat of Fig. 95. This tracing is from an elderly woman with




FIG. 95.—Irregular pulse, presenting the features characteristic of the youthful type of irregularity except the last beat, which shows a short imperfect systolic period. From a female aged sixty-five, with atheromatous arteries and suffering from angina pectoris.

atheromatous arteries and suffering from angina pectoris. The rhythm exhibits great instability, and the imperfect beat at the end of the tracing evidently differs from the other beats in size, mainly on account of its earlier appearance after the preceding beat. This tracing is given merely to illustrate the fact that when a pulse presenting irregularities of the youthful type occurs in elderly people, it is almost invariably of a mixed character.



## CHAPTER X

### THE CLINICAL SIGNIFICANCE OF PULSE IRREGULARITIES

- § 88. Misconception of the symptoms of pulse irregularity.
- 89. Irregularity not necessarily a bad sign.
- 90. Pregnancy and pulse irregularity.
- 91. Pulse irregularity and hard work.
- 92. Pulse irregularity common after middle age.
- 93. Pulse irregularity and a failing heart.
- 94. Predisposition to irregularity.
- 95. Pulse irregularity and mental affections.
- 96. Pulse irregularity and fever.
- 97. Pulse irregularity in pneumonia.
- 98. Pulse irregularity and chloroform.
- 99. Estimation of the value of pulse irregularity.

§ 88. *Misconception of the symptoms of pulse irregularity.*— There seems to be an almost universal idea in the medical mind that something is very much amiss with the heart that presents an irregular rhythm. As to what this something is no one has any clear idea. But the mystery in which this indefinite something is shrouded has a peculiar fascination, and only adds to the dread with which an intermittent pulse is regarded. One not infrequently meets with patients who have been nearly terrified out of their lives by the vague hints of impending calamity, thrown out by some injudicious practitioner, and their lives have been rendered a burden by following instructions given to avoid the foretold calamity. This prevalent misconception of the significance of the irregular pulse cannot be wondered at, when one reads of the grave importance attached to it by writers of repute and experience. Thus Traube,<sup>22</sup> who was the first to call attention to the character of the pulsus bigeminus, considered it to be a sign of fatal significance, whilst Tripier<sup>23</sup> considered it, when not due to digitalis or to valvular disease, to be associated with epilepsy. In like manner Richardson<sup>24</sup> thought that the

missed beat was a sign of impending dissolution. It may be observed here that nearly all writers assume that there is a difference in the nature of the irregularities presenting a missed beat and the small beat of the *pulsus bigeminus*. As I have shown, they are in reality of the same nature, the only difference being, that in the missed beat the premature systole of the ventricle has failed to send a wave of strength sufficient to be perceptible in the radial artery. In the instances given above by Traube, Tripier, and Richardson, these authors quote cases verifying the opinions given by them. But there can be no doubt that they committed the old-standing and ever-recurring mistake of generalising from insufficient data. While these authors employ certain definiteness and limitation in their assertions, and their assertions are given with a show of evidence, other writers indulge in the vague, mysterious, and indefinite statements that tend to impress the receptive mind with the extreme gravity of the symptom. Thus one writer says, "It can be stated broadly that intermittence is usually of grave import." Then again, "Whenever the pulse of a sufferer from chronic nephritis beats regularly for several strokes, quickly followed by several imperfect strokes, a slight halt, and then a full contraction, you may safely say that the curtain in the last act of the drama of life is about to be rung down." In all the most recent text-books the subject is dealt with in the same vague and confused manner.

§ 89. *Irregularity not necessarily a bad sign.*—For a great number of years I have carefully followed the history of a very large number of people with pulse irregularity, and I have come to the conclusion that its significance has been to a great extent misunderstood. It seems necessary to insist that the distinction between an irregular pulse and an intermittent pulse is purely artificial, and that the more deadly significance of the latter is a pure fiction. Irregularities of all forms are perfectly consistent with good health, and, for all practical purposes, with a sound heart. That people with irregular hearts may go through life undergoing great physical exertion, and may pass through illnesses of great severity without their hearts showing any sign of failure, is a statement for which I have abundant evidence to vouch.

My attention was drawn to this subject early in my medical life. Twenty years ago I was asked by my colleague,

an elderly, experienced, and shrewd physician, to examine with him a clergyman from a neighbouring country parish. This clergyman had come to get a medical certificate testifying to his physical fitness to undertake hard mission work in a district in the east end of London. I was struck by his remarkable virility and energy. His heart was extremely irregular in action and also slightly dilated. We refused to give him a certificate, although no other abnormality could be detected. He defiantly remarked that all the doctors he had seen had made too much fuss about his heart, but for his part he was determined to undertake this hard work, preferring to die of hard work rather than mope away in a country parish. He left the neighbourhood for his mission. I lost sight of him entirely, till twelve years after he walked into my consulting room. Careful examination of his heart and pulse failed to reveal the slightest abnormality, and till he died two years ago, from cancer of the bowels, his heart never exhibited any sign of weakness.

§ 90. *Pregnancy and pulse irregularity.*—I think it will be admitted that few things entail such work upon the heart, or afford better proof of a heart's soundness, than constant child-bearing. One has only to consider how extremely dangerous pregnancy is to patients in whom there is valvular disease with failing compensation, to realise how severe is the stress entailed on the heart during pregnancy. Pulse irregularity is extremely common in pregnancy. It is more often found in multiparous women, and does not usually appear during the earlier pregnancies. It may thus be inferred that it is only after a certain degree of exhaustion that it is developed. But still, the following instances show that the heart cannot be materially damaged in consequence of these pregnancies, nor can the irregular pulse be taken as evidence of a damaged heart.

Fig. 71 was taken from a female in 1891. She was at that time thirty years of age, and I had attended her frequently during the previous ten years. In this year she was pregnant with her seventh child when I first detected an irregularity of the pulse. At first it was an occasional irregularity, but shortly after confinement it became frequent, as in the tracing. The pulse was not always irregular, but the irregularity would appear and disappear without any apparent reason. She again conceived, and was confined fifteen months after the previous



confinement, and during this pregnancy the same irregularity could occasionally be detected. Of late years I have frequently detected it, and as she has had no more children, the heart is not exposed to so heavy a strain. During all her married life she has worked hard, attending to the wants of her numerous progeny, as well as her husband and two lodgers, and nursing her children when sick. Only those who are intimate with the life of our working classes can have any idea what a strain such a life is upon a woman. The work is almost ceaseless, and the few hours spent in bed are scarcely sufficient to restore exhausted nature. The bodily exertion is at times very heavy, for the baking of bread and the washing for the family are almost invariably done by the mother. Yet to-day she is as bright and active as ever, and her heart shows no sign of giving way under the strain.

Fig. 72 is a very similar tracing, and was taken from a woman in 1891, shortly after her fourth confinement. From that time until now her pulse has been irregular, and very like that in Fig. 72. This would, I suppose, by some writers be considered an irregular pulse as distinguished from an intermittent pulse, and therefore not so dangerous. But occasionally this woman's pulse was distinctly intermittent—that is, there were long pauses during which no premature beat could be detected, either by the finger or by the sphygmograph, as in Fig. 94. This patient has borne three children since the irregularity was observed in 1891, and she works quite as hard as the last-mentioned patient.

The series of tracings, Figs. 84-88, were from a woman thirty-three years of age and seven months pregnant. These tracings show missed beats and premature beats occurring in long series. Her confinement was easy, and her recovery free from any drawback. These are not exceptional cases by any means. I should not be far out in stating that probably one half the number of multiparous women present cardiac irregularities during their child-bearing periods. When making observations on the condition of the heart in pregnancy, it was my custom to keep a list of pregnant women and visit them at regular intervals in order to make observations on the heart. In many cases I would find a pulse occasionally irregular during one visit, and never again be able to detect it. On the other hand, I have seen cases start with an occasional irregularity, in

whom the irregular pulse became a lifelong characteristic, and all these without any symptoms of serious cardiac mischief.

§ 91. *Pulse irregularity and hard work.*—I have detected the irregular pulse in many men too, and they have for years pursued a laborious life without any cardiac inconvenience. As an instance of this, I may mention the case of the man from whom Fig. 96 was taken. He was sixty-two years of age when I took this tracing, and was at the time and for some years after following his occupation of "tackler" in a cotton-weaving shed. A tackler's duties are of a very trying nature to the heart, the tackler having to lift and carry heavy beams for the weaver. This old tackler had this irregular heart for years, and when he ended his days of hard work (and, it must be added, of hard




FIG. 96.—Irregular pulse from a man aged sixty-two, whose work entailed severe bodily labour.

drinking) it could not be said with any show of reason that his heart irregularity was the cause of his death. Yet a study of the tracing in Fig. 96 will show undoubted evidence of an irregular and intermittent pulse.

§ 92. *Pulse irregularity common after middle age.*—Though I can offer no satisfactory explanation for its appearance, yet the occurrence of an irregular pulse in people after middle age is so common that I consider it but one of the many other symptoms that accompany advancing years. Its presence may not be constant, and it is curious how we may once detect a single irregularity in a patient's pulse, and then for years fail to find it again. It very often happens also that during the first few minutes the patient is under examination his excitement may cause not only rapid action of the heart, but also irregular action. There is no doubt the irregular pulse is often associated with atheromatous degeneration of the vessels and consequent changes in the heart muscle. But its presence does not add to the gravity of the situation. I have had elderly patients with pulse intermissions who have died suddenly. I have known many more expire in the same way whose pulse had never departed from the regular rhythm. The suspicion that such a thing would happen should never depend upon the irregular pulse alone.

§ 93. *Pulse irregularity and a failing heart.*—As an accompaniment of a failing heart an irregular pulse is frequently found, whatever the cause of failure may be—valvular disease of the heart, atheromatous arteries, Bright's disease, etc. But even then the irregular pulse is not the salient symptom in any case. A patient with valvular heart disease may live for many years with an irregular pulse always present. In the heart of the aged an irregular pulse is no serious sign. I took a tracing of an irregular pulse the other day from an old man aged eighty-six. To my certain knowledge his pulse has been irregular for the past sixteen years. Until two years ago he was wonderfully hale. Even in heart failure from chronic Bright's disease the irregular heart may be present for many years. In 1899 I lost an old patient at the age of sixty-nine who has suffered for many years from gouty kidney. In 1891 his heart became irregular and persisted so until his death. Eight years of an irregular failing heart is rather a lengthened period "for the last act of the drama of life" to occupy.

§ 94. *Predisposition to irregularity.*—There is a greater tendency in some people for the pulse to become irregular than in others. I have already referred to this tendency during excitement. Temporary attacks may arise from indigestion or some more obscure cause. Certain drugs, or substances that act as drugs, as tea, tobacco, digitalis, affect people with this tendency sometimes with extreme readiness. I know of one man who, after an attack of influenza, could not drink a cup of tea without his pulse intermitting every third or fourth beat for a short time. This tendency persisted for a few months. The susceptibility of some people to tobacco and digitalis is a matter of common experience. Certain diseases, as erysipelas and influenza, have a tendency to induce pulse irregularities. These are always characterised by the occurrence of premature beats at regular and irregular intervals, or sometimes groups of these premature beats.

§ 95. *Pulse irregularity and mental affections.*—The association of pulse irregularity with mental affections, so far as my experience goes, is in the majority of cases a casual one. I have never met with it in epilepsy. I have seen marked irregularity in puerperal insanity, but then, as I have stated, pulse irregularity is a very common incident in the puerperal state. The melancholy, depressed condition of elderly people with atheromatous arteries may be associated with occasional intermissions of the pulse, but



the same mental condition is often associated in other people with a perfectly regular pulse. I have under my care a family of three sisters and a brother who all at times have become extremely depressed mentally after sixty years of age. The three sisters all had occasional pulse intermittence, but the brother, though the most depressed of all, never had any pulse irregularity. In the case of a young woman an extreme melancholy was associated with a well-marked pulsus bigeminus. But whether there was any connection between the symptoms I could not determine. The irregular pulse in hysterical or extremely nervous people may be induced by the excitable condition of the nervous system. It is, however, of very little moment. I have at present such a patient under observation in whom twenty years ago I first felt the pulse irregular. Ever since then she has had frequent attacks of irregularity, lasting for weeks together.

§ 96. *Pulse irregularity and fever.*—Whenever anything quickens the action of an irregular heart, the irregularity usually disappears. The most common and marked instance is to be seen in fever. One may take this as a favourable sign. When a febrile condition is subsiding, the pulse becoming slow tends to become irregular in certain people, so that within certain limits the appearance of an irregular pulse may be a good symptom. When a pulse does not become regular with an increased rise in temperature, one should watch the case carefully. In an old clergyman who consulted me, the pulse was habitually irregular. He also suffered much from shortness of breath on exertion. He was seized with pneumonia, but the pulse did not become regular with the rise of the temperature, and he speedily died. The occurrence of an occasional irregularity with a high temperature should always be looked upon as a very grave symptom, particularly in the young. I had at one time formulated the rule, for my own guidance, that when a pulse is irregular with a temperature over 103, it is invariably a fatal sign. For some three years this held true, but then I had a series of patients suffering from diverse diseases, which did not support this rule. I found, however, that the exceptions were elderly people, in whom pulse irregularities were of frequent occurrence when they were free from fever (see Fig. 156).

§ 97. *Pulse irregularity in pneumonia.*—In all cases of acute lobar pneumonia that I have met, when the pulse showed

even an occasional irregularity before the crisis was reached, death supervened. I have not found a single exception to this rule for over ten years, and while extended experience may prove it fallacious, irregularity of pulse with pneumonia must, at all events, be looked upon as a most serious symptom.

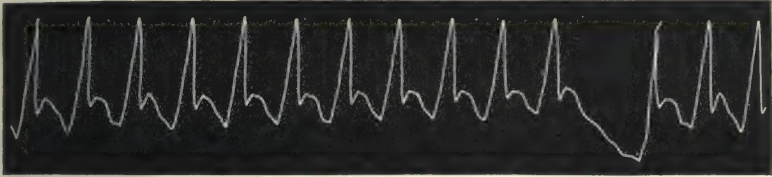


FIG. 97.—Irregular pulse in the course of a pneumonia. Male aged fifty-four, P. 104, T. 102, R. 28.

Figs. 97-100 are all from cases of acute lobar pneumonia that ended fatally. In each case, the irregularity consists of a

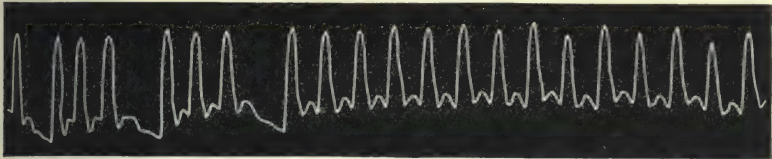


FIG. 98.—Irregular pulse in the course of a pneumonia. Female aged twenty-eight, P. 140, T. 105, R. 45.

heart beat that fails to send a wave of blood to the radial artery. At least one surmises this from the evidence already given

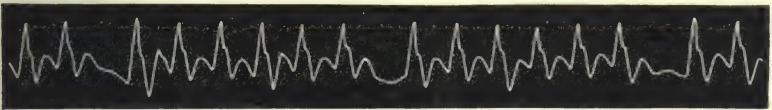


FIG. 99.—Irregular pulse in the course of a pneumonia. Female aged forty-three, P. 128, T. 103, R. 44.

regarding the nature of the dropped beat, and also from the fact that in Fig. 100 the dropped beat is preceded by two irregulari-




FIG. 100.—Tracing of the respiratory curve and of the irregular pulse in the course of a pneumonia. Male aged fifty-six, P. 120, T. 103, R. 35.

ties due to an incomplete ventricular systole. It may, however, be pointed out that in some of these tracings we do not find the

usual harmony in time between the irregular beats and the other beats. In Figs. 97 and 98 the time occupied by the long pause and the preceding pulse corresponds fairly accurately with two regular pulse beats and their pauses. In Fig. 99 the duration of the pause is relatively shorter. In Fig. 100 the small beat  $s'$  does not cut short the preceding diastole, but occurs at its normal time, and it is not followed by a prolonged pause. The long pause, however, of the last irregularity is preceded by a small beat, but even this small beat does not cut short the preceding diastole. It is likely that a premature ventricular systole occurred during this long pause, too weak to send a pulse beat to the radial. In a large number of tracings taken from this patient, these features were continually present. I have met with a somewhat similar condition in a patient with a mild attack of rheumatic fever, and in whom this irregularity seemed to herald the syncopal attack from which he suddenly died,

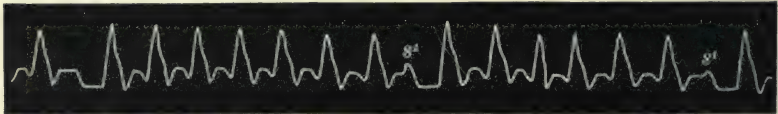


FIG. 101.—Irregular pulse in the course of rheumatic fever. Male aged forty-six, P. 120, T. 101, R. 20.

Fig. 101. This tracing shows the occurrence of a small premature systolic wave  $s'$ , which is not followed by the usual prolonged pause, so that the period occupied by the preceding pulse beat and this short one does not correspond to two ordinary pulse beats. I do not rightly comprehend the true significance of these irregularities, but point them out as having been observed in hearts evidently dying and associated with a high temperature.

§ 98. *Pulse irregularity and chloroform.*—Broadbent<sup>25</sup> gives the following instructions to observe in the administration of chloroform in case of pulse intermittence: “I do not hesitate to authorise when consulted on the subject on condition that the pulse be carefully watched. The rule is that the chloroform suspends the intermission; should it have a contrary effect from the first, the pulse becoming weak and irregular, fatty degeneration of the heart may be suspected and the administration should be at once stopped.”

I could have wished that he had given us more fully the reasons for the faith that is in him. I have made many



observations on the pulse in patients under chloroform, but I found that there were so many factors concerned in modifying the circulation that my results are of no value. Thus the excitement often caused extreme palpitation. The struggles of the patient naturally have a marked effect upon the circulation, while in some patients the breathing would be abnormally slow for a time, or it might be much hurried,—factors that often materially modify the characters of the pulse.

Unless, therefore, I fear some cardiac mischief, pulse irregularity in the administration of chloroform never gives me concern. In midwifery I invariably employ chloroform without hesitation, even when there is present a certain amount of cardiac failure and valvular disease. Valvular disease itself is no objection, but if the lungs be water-logged or extensively cedematous, I might give it with fear and trembling. Pulse irregularity, if present either before or occurring during the




FIG. 102.—Irregular pulse occurring during deep chloroform anaesthesia.

administration of the chloroform, is no bar to its continuance. Fig. 102 is from a woman whose pulse became irregular while she was deeply under chloroform. She still lives and is in good health, and has had two other pregnancies since this tracing was taken. Great circumspection should be employed in cases of pulse irregularity where there is a suspicion of degeneration of the heart muscle, such as follows atheroma of the coronary arteries. The case of an elderly patient, with extreme shortness of breath or attacks of pain in the chest on exertion, however slight these pains may be, would render the administration of chloroform a risky procedure, whether the pulse is irregular or not. Richardson<sup>26</sup> calls attention to a factor present in human beings, that cannot be reckoned with in experimenting on animals—namely, the mental perturbation and fear induced in patients on the prospect of undergoing an operation and taking chloroform. That this is an element the following instructive instance will show. The patient, a man aged sixty-five, of pale and anxious countenance, suffered from shortness of breath and slight pain in the chest on exertion.

He also suffered much from piles and intolerable itching in the neighbourhood of the anus. Palliative measures failed to relieve him, and he pleaded with me to do something for his relief, as his suffering was intolerable, and he would rather die than live in such misery. After much hesitation I resolved to operate on the piles. When the patient was brought to the operating table he was much excited, and his heart was beating at a great rate. A few drops of chloroform were sprinkled over the towel and held over his mouth and nose. He had only taken a few breaths when he began to struggle. The towel was at once removed, and after a minute he became quiet. The towel was about to be replaced when a change in his countenance was observed. On his pulse being sought it was found to be absent. On listening over the heart no sound could be heard. Yet for nearly a whole minute after these facts were made out the patient continued to breathe heavily and somewhat noisily. The breathing ceased and the patient was dead. Here it is manifest that it was not the infinitesimal dose of chloroform that killed the patient, but the mental excitement acting on a damaged heart, just as happens in patients who die suddenly in excitement from other causes.

§ 99. *Estimation of the value of pulse irregularity.*—It must not be supposed that no significance is attached to an irregular pulse. It very often is present in people who are dangerously ill and who die from heart failure, but then it is only one of many symptoms that testify to weakness of the heart. An irregular pulse present, with brain symptoms, may help in guiding us to the seat of the mischief. When it accompanies other evidence of heart failure, it forms an additional link in the chain of evidence. It may indeed be the first herald of impending dissolution in such conditions as those to which I have referred. But it is when it is the only abnormal symptom present, or associated with the milder degrees of heart failure, that I maintain that it has none of those terrible consequences so vaguely hinted at. One can arrive at a more just conclusion in estimating the value of the pulse irregularity by employing the method described in § 3—namely, by ascertaining to what extent, if any, the field of cardiac response is contracted, and here again I would repeat, “Never depend upon the pulse alone in estimating the value of its abnormality.”

## CHAPTER XI

### INCREASED FREQUENCY OF THE PULSE

§ 100. Classification of cases.

101. Cases in which the heart responds to a call upon its energy by increased frequency.
102. Cases in which the pulse rate is continuously increased: (*a*) valvular diseases; (*b*) affections of the myocardium; (*c*) pregnancy; (*d*) alcohol; (*e*) neurotic cases; (*f*) exhausting diseases; (*g*) exophthalmic goitre.
103. Cases in which the increased frequency of the pulse occurs in irregular paroxysmal attacks: (*a*) palpitation; (*b*) paroxysmal tachycardia.

§ 100. *Classification of cases.*—It has already been shown that what may be considered the normal pulse rate may vary within very considerable limits. A certain increase in the rate also occurs normally under conditions calling forth increased work by the heart. What we are considering here is the abnormal increase of the pulse rate, and the conditions, other than febrile, which induce an undue increased rapidity of the pulse. This subject may fittingly be described by dividing the cases into three groups. First, those cases in which the heart responds to a call upon its energy by increased frequency. Second, those cases in which the pulse rate is continuously increased. Third, those cases in which periods of increased rapidity take place in irregular paroxysmal attacks.

§ 101. *Cases in which the heart responds to a call upon its energy by increased frequency.*—The first of these groups, where the heart responds to an increased call upon its energy by increased frequency, shows in reality but an exaggeration of what occurs normally. When we find that a patient is seized with palpitation or rapid heart action after mounting a few steps, we recognise as abnormal that which in an individual who had run half a mile at the top of his speed would have been recognised as normal. In other words, the field of the heart's response to



effort is greatly reduced. The increased frequency in such a case should always lead one to seek the cause from which it arises. The conditions giving rise to it are too numerous to mention, but they all in the end point to enfeeblement of the muscle of the heart. In all exhausting diseases, and after convalescence from such a wasting sickness as typhoid fever, the heart's rate can be greatly increased by even very moderate exertion. In the various anæmias (chlorosis, pernicious anæmia, malignant cachexia) it is very often the symptom to which the patient's attention is first called. In organic affections of the heart, as the various forms of myocarditis, in fatty degeneration of the myocardium, and in valvular disease where compensation is not fully established, increased frequency of the pulse on exertion is extremely common. Many of the patients whose ailments are included in the foregoing groups, when at rest have a pulse beating about or not much above the normal rate. The heart then seems to be capable of sustaining the demands of the circulation, but seems to be working near the top of its reserve energy. On exertion this reserve energy is speedily exhausted, and in order to make up for its inability to respond to the demand for more blood by giving stronger ventricular contractions, it responds by giving a greater number of feebler and less complete contractions. For a time the increased number of these beats may keep up the blood supply, but exhaustion of the heart muscle sooner or later sets in, and the contraction of the ventricle becomes less complete, so that the accumulation of blood in the chambers of the heart ultimately produces dilatation of the cavities. If a patient's heart be examined after a period of overstrain (understanding by overstrain a condition induced by making the heart attempt to do work beyond its power—whether it be the great effort of a healthy heart or the slight effort of a weak heart), the result is always the same—distinct evidence of dilatation of the heart, usually indicated by dulness on percussion beyond the border of the sternum on the right, and beyond the nipple on the left, and often marked by regurgitation of blood into the veins of the neck.

In addition to the increased rate of pulse there is usually hurried and laboured respiration, and this too occurs equally when a strong heart is overstrained by a great effort, or a weak heart by a slight effort. Not infrequently in elderly people,

before the interference with respiration can arise, the patient in making an effort is stopped by a feeling of weight or oppression within the chest, or even by pain striking across the chest, sometimes severe, sometimes slight, but in all cases imperiously demanding a cessation of the effort.

It is as impossible to indicate with any approach to accuracy when a pulse rate is abnormal on moderate exertion as it is to indicate what the pulse rate should be in health under similar circumstances. The increase is often so marked that its recognition is beyond dispute. Thus, in making a patient sit up or turn over in bed, a rise of five to ten beats a minute may not be worthy of much attention, but if the increase is fifteen to thirty beats then there is distinct evidence that we have to do with some condition that has exhausted the heart's reserve power. This increase of the pulse rate beyond the normal on moderate exertion does not give any clue as to the nature of the condition that has reduced the heart's reserve power. As already indicated, these conditions are so numerous that an examination for other symptoms must be undertaken to discover them. There is a class of neurotic patients whose hearts are easily excited to inordinate rapidity. They are mostly women, and the symptom may occur at all ages over puberty, but is less common in those over sixty. They are easily upset—a sudden movement, a sharp noise, or anything that startles them, is generally followed by a quick movement of the body and a very rapid action of the heart. This is often associated with a good deal of mental depression and numerous subjective sensations in various parts of the body. No trace of disease can be detected, and they are much benefited by treatment—bromide of ammonium acting like a specific remedy in many cases. These cases are again but exaggerations of what normally occurs in the healthy heart when stimulated by mental excitement.

§ 102. *Cases in which the pulse rate is continuously increased :*  
(a) *valvular diseases.*—The second division, where the heart maintains a frequency beyond what we recognise as within the limits of health, includes a great variety of heart conditions. Again we have the series of valvular diseases of the heart, with incomplete compensation. Not only do such hearts respond to effort with marked increase in frequency, but when at rest the heart may be beating with abnormal rapidity, regularly or irregularly. This forms one factor in arriving at an opinion of the strength

of the organ. The other symptoms of heart failure present will help in indicating the stage at which the patient has arrived.

(b) *Affections of the myocardium.*—Apart from cases of manifest valvular disease of the heart, there are many whose pulse is rapid, and in whom no disease of the heart can be detected by physical signs. The chest wall may be thick and fat, or the lungs so voluminous that the actual size of the organ cannot be satisfactorily defined. The sounds, though free from murmur, may be so slightly modified that no certain inference can be drawn from them. Yet that serious mischief is present, is but too often demonstrated by watching the after-history of the cases. If we exclude for the present the consideration of certain neurotic cases, the cause of the quickening in all cases is really due to want of strength of the muscular wall. In valvular disease this is usually spoken of as failure of compensation. In degeneration of the wall, fatty or fibrous, the weakening of the wall is directly due to this degeneration. In the great series of overstrained heart from excessive exertion, the weakness of the wall is the principal cause of the whole train of symptoms associated with the failure of the heart. In arriving, therefore, at an estimate of the value of the pulse quickening, a consideration of the other symptoms present will be necessary to recognise what form of affection is the cause of the increased pulse rate in each special case. The circumstances, age, and condition of the patient will help much in recognising the rapid pulse due to actual degeneration of the heart wall. But there is a series of cases in which it is difficult to account for the rapid pulse, especially when it occurs in the apparently strong in the prime of life. In these cases there is generally a history of hard work or periods of excessive muscular exertion. Sometimes the condition receives a special name, as "the soldier's heart." I expect that medical men, whose practice lies amongst workpeople subjected to much muscular exertion, are fairly familiar with the condition. In the neighbourhood in which I practise, though there are numerous industries entailing continuous laborious work, yet I find this condition more prevalent among a class of men whose labour is intermittently severe. In the cotton mills are a class of men called "tacklers," part of whose duty consists of detaching, lifting, and carrying the large heavy beams on which the cotton threads are wound. These men are very liable to suffer from the effects of great muscular effort, as hernias



and heart overstrain. The heart overstrain is most evident amongst those with a tendency to obesity and who indulge rather freely in alcohol. The symptoms are mainly a quickened pulse and shortness of breath on exertion. Examination of the chest is often fruitless, the chest being large and deep, and the lungs often voluminous. With care and rest and appropriate treatment, much improvement can result. But there is a stage which is reached when no treatment seems to be of any permanent value. That is when the heart wall is so weakened that free regurgitation of the blood takes place into the veins of the neck and chest wall. In such cases the radial pulse is invariably small, quick, and weak, while the pulsation in the neck may be very marked. I shall again refer to this subject more fully when dealing with the venous pulse (§ 201, cases 6 and 7).

(c) *Pregnancy*.—It may be noted that these symptoms are often present in pregnant women, but then the cause is but temporary, and when delivery takes place a certain amount of recovery follows. Usually the recovery is very considerable, but in my experience there is often left a certain amount of cardiac weakness, shown by a distinct limitation of the field of cardiac response.

(d) *Alcohol*.—Muscle failure from alcoholic excess is also accompanied by a quick pulse. While recovery in these cases often occurs, yet when the failure has gone so far as to produce those symptoms of extreme regurgitation into the veins, in my experience it is never recovered from, but the illness slowly progresses to a fatal termination (§ 201, cases 4 and 5).

(e) *Neurotic cases*.—There is a group of people who exhibit a rapid pulse in whom no heart lesion can be detected, and whose future history demonstrates that no serious cardiac lesion existed. These people exhibit other symptoms more prominently associated with the nervous system. Though this is more common among women, many male patients exhibit the same condition. The chief complaint and the one common to all is weakness. Numerous sensations are described, some being more prominent than others, according to the individual. Strange feelings in various parts of the body, numbness of a limb, aching in the back, peculiar trembling sensations in the abdomen, contraction of the throat, weight in the head, indefinite fears, sleeplessness, and mental depression are among the numerous

complaints one gets in these cases.\* These indeed are but the indications that complete the condition called neurasthenia. The quickened heart action is but one of the symptoms, and is, in all likelihood, produced by the same irritation that induced the other symptoms. The pulse is usually soft and compressible, often large in size with a quick, short impact. These symptoms point to a weak acting ventricular wall, and by long persistence the cause of these symptoms may lead to dilatation of the organ. In these cases the attempt to quiet the heart's action by bromide of ammonium is more successful than the employment of digitalis or other cardiac tonic.

(f) *Exhausting diseases.*—It is always well to bear in mind that a persistent quick pulse may be the earliest symptom of an attack of tuberculosis or of the onset of malignant disease. A patient may complain for months of weakness, with an absence of the sense of well-being, with no actual suffering. After a time the development of other symptoms demonstrates the cause of the abnormal pulse rate. In most exhausting diseases (malignant diseases, pernicious anæmia, tuberculosis) the pulse rate is continuously quickened.

(g) *Exophthalmic goitre.*—The essential features of the circulation in exophthalmic goitre, it seems to me, are the abnormal and

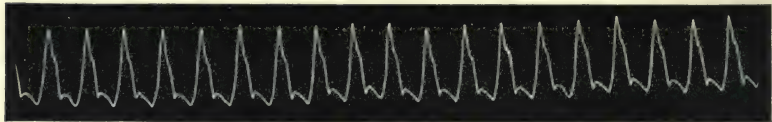


FIG. 103.—From a female aged forty, suffering from exophthalmic goitre.

persistent dilatation of the arterioles, and a heart acting with a force relatively great to the resistance opposed. This view explains the rapid and forcible pulse wave (Figs. 103 and 104),

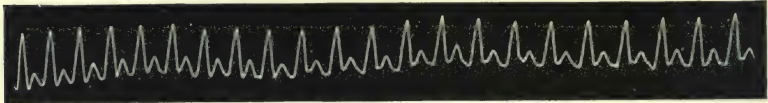


FIG. 104.—From a female aged twenty-two, suffering from exophthalmic goitre.

felt by the finger, and the visible pulsation of the superficial arteries like the carotid. The rate of the pulse may be greatly increased up to from one hundred and forty to one hundred

\* For a full and clear description of the subjective symptoms, see Jean Jacques Rousseau's description of his own sensations.<sup>27</sup>

and sixty per minute. The same factors, the forcible injection of the blood into arteries of low blood pressure, are present in aortic regurgitation. Though the beating of the carotid in both cases is due to similar causes, the causes of the low arterial pressure at the end of diastole is different. In exophthalmic goitre the dilatation of the arterioles is the sole cause, whereas in aortic regurgitation there is in addition the backward flow of blood into the ventricles through the incompetent valves. The condition of the circulation in exophthalmic goitre is also comparable to that of some forms of sthenic fever, where the heart beats forcibly and the arteries are relaxed.

Another evidence of the relaxation of the arterioles is to be found in the subjective sensation of warmth felt by many sufferers from exophthalmic goitre. They rarely complain of cold in winter, however lightly clad they are, and this is not infrequently the cause of matrimonial disputes, for while the ailing wife feels warm in bed during winter with few blankets, the healthy husband feels the cold keenly. This feeling of warmth has supplied me with the indications for the only treatment I have found both grateful and beneficial to the patient—namely, the periodic stimulation of the vasomotor nerves by cold baths. Whenever there has been the feeling of warmth, I have found these baths do good, and when there is nervousness and muscular tremor the administration of the bromide of ammonium has been of great service.

§ 103. *Cases in which the increased frequency of the pulse occurs in irregular paroxysmal attacks.*—The third class of cases where the frequent pulse occurs at occasional intervals includes two very distinct varieties—namely, palpitation and paroxysmal tachycardia.

(a) *Palpitation.*—This may occur in people suffering from a great variety of complaints. In cases of valvular disease with imperfect compensation, slight physical effort or mental excitement may readily induce an attack. Even in the healthy certain mental states may induce an attack, while when the system is weakened from disease the liability to attack is much increased. It is in certain neurotic subjects, particularly females, that one sees the complaint attain its most distinctive features. There is usually no organic affection of the heart, and though frequent attacks may ultimately induce cardiac dilatation, yet, as a rule, they do not appreciably shorten life. Anything that startles the



patient, whether a sudden noise or mental perturbation when awake, or uncomfortable dreams when asleep, readily induces an attack. But it may supervene from more obscure causes, evidently reflexly stimulated by affection of organs more or less remote (stomach, uterus). When the attack comes on the patient becomes painfully aware of the violent action of the heart. She prefers to sit upright, draws deep inspirations, and moves uneasily from side to side, with the hand pressed over the heart. It is accompanied by sensations of a distressing nature, such as a sense of suffocation and a fear of impending dissolution. When it subsides it leaves the patient exhausted.

During the attack the pulse is increased in frequency, the artery may be of fair size; sometimes, however, it is very small.

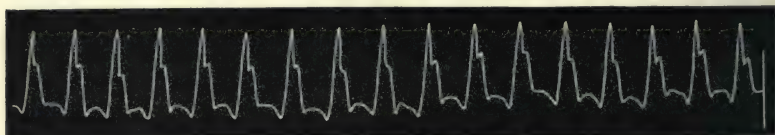


FIG. 105.—During an attack of palpitation.

The impact of the pulse wave on the finger is sudden and sharp and of extremely brief duration. The tracing Fig. 105 shows a high upstroke with a great fall, so that the arterial pressure at

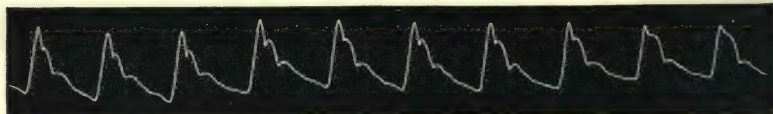


FIG. 106.—Tracing of the normal pulse of the patient from which Fig. 105 was obtained.

the bottom of the dicrotic notch is nearly as low as at the end of the diastolic period—an evidence that in addition to the excited heart there is great relaxation of the arterial wall. Fig. 106 is from the same patient when the heart was acting quietly.

(b) *Paroxysmal tachycardia*.—There is another group of cases where the heart's action is extremely rapid for varying periods, and where the symptoms are distinct from palpitation, inasmuch as the distressing mental symptoms usually associated with palpitation are absent; the attacks as a rule continue for a longer period, and the pulse attains a much greater rapidity than is found in attacks of palpitation. The condition to which the term paroxysmal tachycardia is applied is characterised by “an enormous quickening of the pulses of a heart not necessarily

the seat of static disease—a quickening which attacks the patient suddenly, which does not persist indefinitely, but for a variable space, rounded off by an equally sudden reversion to the normal state, less certain phenomena of exhaustion.”<sup>28</sup> An attempt has been made to limit the group to those patients who do not suffer from a demonstrable valvular lesion, but it is the general opinion that no sufficient reason exists to justify such a limitation. The attacks are of the most varied duration, lasting in the same patient at one time but for a few minutes, and again persisting for several days. I have several times had the opportunity of watching the changes that take place in the circulatory system during an attack of paroxysmal tachycardia. In these attacks the most notable thing is that the greatly increased rate of the heart is demonstrably associated with an actual diminished output from the heart. Thus the heart after a long attack is found distinctly increased in the transverse direction, the apex remaining in the fifth interspace, but displaced outward, and sometimes the apex beat is more pronounced. The dulness which, before the attack, did not extend to the right beyond the midsternum, can readily be demonstrated one inch beyond the right border of the sternum. The changes in the veins of the neck are still more evident. If the valves situated in the jugular vein immediately above its junction with the subclavian be intact and competent, the vein below is distended into a large pulsating swelling. If these valves are incompetent, there is marked pulsation of the jugular vein. In this latter case it is impossible by timing to distinguish whether it is jugular or carotid, but one may be certain that if the radial pulse is small, as it invariably is in these cases, the carotid pulse is also small, and hence this large pulsation in the neck is not a “beating of the carotid,” as some have wrongly inferred, but an actual regurgitation into the veins. In addition to the demonstration of the flow back into the veins, it occasionally happens that there can be detected a distinct enlargement and pulsation of the liver, with the sensory symptoms of pain in and tenderness of the tissues forming the external body wall covering the liver. The nature of the changes that take place in the heart and veins during an attack of paroxysmal tachycardia are discussed in the chapter on acute dilatation of the heart (Chapter XXIV.).

Two causes have been suggested for the production of this

curious phenomenon: first, that it is due to stimulation of the sympathetic; second, that it is due to suspension of the action of the vagus. The stimulation of the sympathetic cannot accelerate the heart's action to the extreme rapidity that occurs in paroxysmal tachycardia. In regard to the suspension of the vagus activity it is difficult to conceive a condition that would totally paralyse the vagus for one or more days. While I have no evidence as to what may be the proximate cause of the rapid action of the heart, or what portion of the sensory regulating apparatus is stimulated, I throw out a suggestion that has not yet received consideration. In dealing with pulse irregularities I pointed out (§ 84) how the heart at times would contract for a short period by a series of early occurring systoles, and how such a condition could be produced by direct electrical stimulation of the heart muscle. It has seemed to me a view worthy of consideration, that the attacks of paroxysmal tachycardia are really attacks consisting of a long continued series of premature systoles. My reasons for suggesting this view are: first, that it is the only one that can account for the long continued extraordinarily rapid action of the heart; second, in many cases the rapid pulse can be demonstrated to consist of series of groups of premature systoles; and third, the attacks present certain analogies to attacks of irregular heart action, when the heart does not acquire this excessive rapidity. In order to illustrate this view, and also to demonstrate the different conditions under which paroxysmal tachycardia may occur, I select a few illustrative examples from among those that have come under my own observation.

Case 1, male.—The patient visited me on January 29th, 1891, saying he had a curious "fluttering about the heart." I had known him well for many years, and he had always been a



Fig. 107.—Irregular pulse presenting two full beats (first and eighth)—full beats whose pauses are interrupted by premature systoles, and a series of premature systoles at the end.

man of sound constitution and of good health. He was then forty-three years of age. The pulse varied considerably in rate, as will be surmised from a consideration of the tracing (Fig. 107). The tracing consists of two full beats, with prolonged pauses



(first and eighth beats, in the tracing) of full beats, whose diastoles are interrupted by premature systoles, and of a series of premature systoles at the end of the tracing. The patient's pulse next day was quite regular, and for the past nine years he has never had another attack, and is to-day a healthy, active man.

The rate of this pulse (one hundred and twenty to one hundred and thirty per minute) was not sufficiently great as to warrant one in considering it a case of paroxysmal tachycardia, according to the usual acceptance of the term. Nevertheless, I am of opinion that it was of the same nature. In heart cases generally, one often gets a better insight into the nature of any given complaint, not by studying the most extreme and classical types, but by studying the mildest and scarcely recognisable groups. So for that reason I present this case, as it helps to interpret the following cases.

Case 2, male.—Had a mild attack of rheumatic fever in November 1892, being then aged nineteen. From this attack he made a good recovery without any recognisable cardiac complication. A month after the subsidence of the fever he called upon me, and although complaining of nothing but weakness, I found his pulse extremely rapid. The artery was large and full, but extremely soft, while the pulse was short, sharp, and feeble. I could only get a good tracing by holding the sphygmograph lightly on the artery with my hand, the slightest pressure compressing the artery. The pulse would sometimes consist of a long series of extremely rapid beats following one another at regular intervals, then would follow a series of slow beats (Fig. 24). In the tracing the series of rapid beats reaches nearly the rate of two hundred per minute. These are manifestly premature systoles interrupted by occasional full beats. This attack disappeared in a couple of days, and he has never had another. Like the preceding case, it is doubtful if this should be included in the group of cases of paroxysmal tachycardia, for there would be intervals when the pulse rate would fall to about one hundred and twenty per minute during the attack, while again it would reach two hundred beats per minute, all of them due to premature systoles.

Case 3, female.—Consulted me for weakness, shortness of breath, and fluttering about the heart. The pulse rate varied from one hundred and sixty to two hundred per minute. The

rapid pulse lasted for five days after this tracing (Fig. 108) was taken, and then suddenly became quite regular. She had occasional attacks of this rapid irregularity until she died, aged sixty-eight, four years after my first observation. There was no valvular disease, but marked dilatation of the heart, and she died with

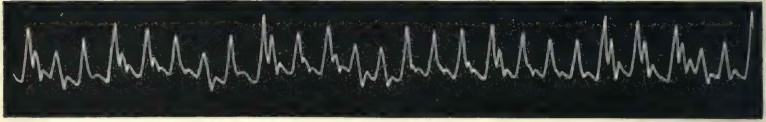


FIG. 108.—Premature beats of various sizes occurring in groups, and occasional full beats.

symptoms of heart failure, dropsy, and dyspnoea. Fig. 108 is an illustration of the occurrence of groups of premature systoles, and there can be little doubt this marked increase of the pulse rate was entirely due to them. During the period of quiet action of the heart an occasional irregularity due to the occurrence of a premature systole could be detected (Fig. 109).

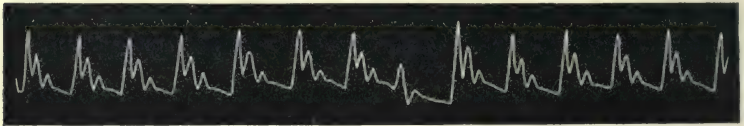


FIG. 109.—Shows an occasional premature beat. From the same patient as Fig. 108.

Case 4, female.—This patient presented the most extreme pulse rapidity of which I have a tracing. She was about fifty years of age, and was admitted to the Victoria Hospital the day before her death. The only account which I could glean was that there was no history of previous heart disease, but she

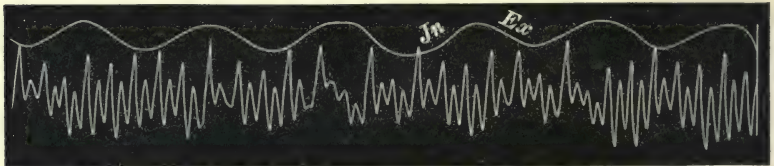


FIG. 110.—Tracings of an extremely rapid pulse due to a long series of premature systoles.

had suffered lately from great weakness and shortness of breath, and the pulse had assumed this great rapidity during the last few days. The pulse was, at the time of examination, uncountable, but was certainly more than two hundred and fifty beats per minute. It would be quite regular for long periods, but would

present occasional slowing, as in the tracing, Fig. 110. The slowing can be recognised as due to occasional full beats interrupting a long series of premature systoles. It will be observed that there are two waves to each pulse beat, the lesser wave being a large dicrotic wave, and the dicrotic wave is always larger after premature systoles than after the occasional full beat (for the reason explained in § 18). The wavy character of the tracing as a whole is due to the movement of the arm during laboured respiration, and from the tracing of the respiratory movement it can be seen that the pulse tracing falls during inspiration and rises during expiration. That this is purely an artificial condition will be shown in § 129. I am not prepared to say that this was a case of paroxysmal tachycardia, but I cite it as an illustration of how a long series of early systoles can undoubtedly produce a pulse of continuous and extreme rapidity.

Case 5, female, aged forty-six.—This patient was dying from




FIG. 111.—From a case of paroxysmal tachycardia (pulse two hundred per minute).

cancer of the lungs. For several months before she died she had attacks of rapid action of the heart, lasting for two or three days.




FIG. 112.—From a case of paroxysmal tachycardia, showing irregularity, probably due to a missed beat.

The pulse then was mostly quite regular (Fig. 111), but occasionally one could detect pauses and small beats in the pulse, as in

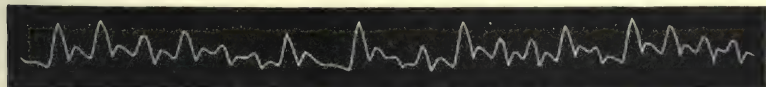


FIG. 113.—From the same patient as Figs. 111 and 112, showing an irregular pulse, due to premature systoles occurring singly and in groups.

Fig. 112. The pause is evidently due to a beat which has failed to reach the artery, and hence gives a clue to the character of the



other beats, which are presumably premature systoles. During the period of quiet heart action the pulse was usually regular, but it would be irregular for several hours, as in Fig. 113. Here there is exhibited the occurrence of premature systoles, singly and in groups.

Case 6, male, aged fifty-one.—This patient was under my care only for a short period. About the age of twenty-five he suffered from rheumatic fever, but I could not detect any valvular defect.




FIG. 114.—From a case of paroxysmal tachycardia (pulse two hundred per minute).

For nearly a week the pulse rate continued from one hundred and seventy to over two hundred beats per minute (Fig. 114). Then it suddenly quietened down (Fig. 115) for a couple of days, after which it resumed its rapid character for a few days, and then remained quiet for the few weeks he was under my observation. He died from heart failure six months later, but he was not then under my care. The pulse, during the quiet period of the heart's action, showed a distinct tendency to the occurrence of premature systoles. Thus the second and last

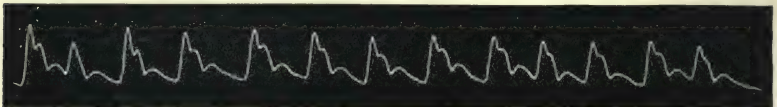


FIG. 115.—From the same case as Fig. 114; during quiet action of the heart the second and last beats are premature.

beats in Fig. 115 are of this character. Noting this I suggest that the whole of Fig. 114 represents a series of these premature systoles.

Case 7, male, aged forty.—This patient first consulted me in January 1900. He had an attack of rheumatic fever at fourteen years of age. Three and a half years ago, after walking for twenty minutes at a rapid pace, he felt extremely weak and exhausted. After this he was always short of breath on exertion. Two and a half years ago, immediately after throwing a cricket ball, he felt the heart flutter for a few seconds. Ten minutes after this the heart "fluttered and beat quickly for six or seven

hours." He has had an attack of this kind every two or three weeks since. These attacks last from a few minutes to thirty hours. At first he could sometimes stop the attack by bending down and taking a deep breath, but this does not act now. Sometimes he passes a large quantity of clear urine in the course of an attack. During an attack, if in bed, he feels exhausted and limp, if walking he is easily tired, and if he has to work for some hours he feels swollen round the waist and very sore over the upper part of his abdomen, and feels pain sometimes very severe across the back under the shoulder blades. During the night the sleep is disturbed. The pulse during these attacks has varied under my observation from one hundred and seventy to two hundred and twenty beats per minute (Figs. 12 and 23). The jugular and liver pulse from this patient are analysed in the chapter on acute dilatation of the heart. When the heart is acting quietly (Fig. 146) one can occasionally detect a short presystolic murmur, and sometimes also a soft diastolic murmur, over the middle of the sternum. It often happens that one is unable to detect these murmurs. On producing slight redness by rubbing the forehead, the capillary pulsation can be readily seen. Occasionally the pulse rate falls to forty-eight beats per minute. Towards the end of an attack, occasionally irregularity of the pulse has been detected. It is of that peculiar kind where the premature systole occurs after every second beat, but is not followed by a long pause (see Fig. 91). The patient (who is a very intelligent man) states that sometimes when the attack of rapid heart action ceases the heart gives three or four violent beats at intervals longer than the usual pulse rate. This, I surmise, is due to strong beats of the heart after premature contraction. The patient died on November 21st, 1900. During the last four months the pulse rate would continue rapid for days together, during which time he would lie prostrate and exhausted. Sleep could only be got by large doses of morphia. During the last two weeks of his life the heart acted slowly only at rare and brief intervals. Signs of heart failure quickly supervened—the face swollen and livid, and general œdema. The changes in the pulsation of the veins and liver are described elsewhere (§ 211). On *post-mortem* examination the right side of the heart was greatly distended. The cusps of the mitral valve were adherent and the orifice narrowed. The aortic valves were slightly thickened and incompetent.

Case 8, male, aged thirty-four.—This patient was admitted into the Victoria Hospital suffering from a hydatid cyst of the liver. I was about to operate upon him one day when I felt his pulse. It was beating at a rate of two hundred beats per minute. On inquiry I found that the patient was conscious of a change in his heart's action. The present attack had come on six hours previously when at the closet. During the last two years he had had several such attacks, lasting sometimes for a few hours, sometimes for a few minutes. I had the pulse watched, and the attack ceased suddenly two hours afterwards, and a tracing taken immediately after showed no signs of irregularity, nor was any irregularity detected during the few months I had him under observation. There was no sign of valvular disease, and the heart was not enlarged when the heart was beating quietly, but was distinctly increased transversely during the attack of tachycardia. There was at times slight pulsation in the veins, and it was from this patient that Figs. 257 and 258 were taken. This is the only case in which I have failed to detect an irregularity of the pulse. I only saw him during one attack, so the opportunity for detecting irregularities if they occurred was wanting.

The series of tracings (Figs. 84-88) show still more conclusively the view that the pulse beats in paroxysmal tachycardia may be due to premature systoles of the ventricle. In these tracings we can detect the premature systoles occurring singly, in groups, and in such a long-continued series that the pulse rate occasionally reached two hundred beats per minute. Since writing the above I have seen another patient sinking from a series of attacks of paroxysmal tachycardia. A tracing of his pulse also showed occasional full beats and premature beats, singly and in groups.

(The discussion of the heart changes in paroxysmal tachycardia is continued in §§ 211 and 237).



## CHAPTER XII

### DIMINISHED FREQUENCY OF THE PULSE (BRADYCARDIA)

- § 104. The normal slow pulse.
- 105. Occasional or recurrent bradycardia.
- 106. Symptoms associated with recurrent bradycardia.
- 107. Classification of cases.
- 108. The slow pulse, with rhythmical action of all the heart chambers.
- 109. The slow pulse due to missed beats.
- 110. The slow pulse due to inhibition of the ventricle.

§ 104. *The normal slow pulse.*—There are a number of people in the enjoyment of perfect health whose pulse beats regularly about fifty per minute. Those of whom I have kept records were mostly tall men. Undoubtedly the size of the body has an effect in modifying the rate of the pulse. Observing these cases under varying conditions, I have found the pulse rate vary considerably. In one man who had attacks of palpitation in the night, following on nightmare, the pulse in the day was sometimes as low as thirty-six per minute. In another case, in a mild attack of influenza the pulse rate fell to forty, with a temperature of  $100^{\circ}$  the first day. Although it quickened somewhat afterwards it never exceeded sixty, with a temperature of  $101^{\circ}$ . A son of this patient at fourteen years of age had a mild attack of diphtheria, and his pulse also fell under forty per minute. I have watched such patients for years leading vigorous and active lives, and their slow acting hearts have been of no appreciable disadvantage to them.

§ 105. *Occasional or recurrent bradycardia.*—There are certain toxæmic conditions which modify the rate of the pulse. Generally speaking, increase of arterial pressure retards the action of the heart. In such diseases as gout and Bright's disease, one frequently finds periods of increased arterial pressure associated with a certain amount of pulse slowing. In pregnancy a slow

pulse is occasionally met with. Such drugs as digitalis have often a decided effect in moderating the rate of the pulse, although digitalis has also a tendency to modify the rhythm of the heart chambers (§ 235). Jaundice is said to have a considerable power in slowing the pulse, but curiously, although I have examined many cases for this symptom, I have not detected it. I have found the pulse distinctly slower during the paroxysm of pain due to gall-stones, in cases where there was no jaundice. Pain has often a distinct effect both in increasing the arterial pressure and in lowering the rate of the pulse. Exhaustion, whether due to failing compensation in valvular disease or after severe bodily effort, as after labour, or after fever, is occasionally found associated with a slow pulse.

§ 106. *Symptoms associated with recurrent bradycardia.*— This occasional slowing of the pulse is sometimes associated with divers other symptoms. Just as in paroxysmal tachycardia, the accompanying symptoms vary much in severity. In describing paroxysmal tachycardia I mentioned a patient (case 7, § 103) where there was occasionally a pulse of forty-eight beats per minute, and during this period he was conscious of no disagreeable symptom. In other cases there may be phenomena referable either to the heart or the brain. Thus a tall spare man of fifty, whose pulse is usually about sixty, has had syncopal attacks, and during the period these attacks were occurring I found the pulse about forty per minute. For some years he has been quite free, and is still in fair health. Four years ago a young man, manager of an iron foundry, consulted me on several occasions for loss of memory, the attacks lasting for some weeks. He could not bear in mind his engagements. He would leave his office to give orders to his workmen, and by the time he was outside he would forget what he was about to do. Repeated examination of the patient during his attacks and when free from them revealed no abnormality, save that the pulse rate during the period when his memory was affected was always slower, sometimes falling below fifty per minute. After trying ineffectually cardiac stimulants, conceiving that some cerebral irritation might be causing the attacks, I put him on bromide of ammonium, with the result that it invariably cut short the attack. For the last two years he has been quite free from them and is otherwise in perfect health. Attacks of recurrent increase of arterial pressure (§ 59) are sometimes accompanied by a slow-

ing of the pulse, with symptoms due to the cause of the increased pressure (§ 60). There are cases on record of the pulse falling as low as five beats per minute, and these are generally associated with severe mental symptoms, as loss of consciousness and epileptic convulsions. Amongst the elderly, recurrent bradycardia may be found as one of the symptoms accompanying the degenerative changes in heart and blood vessels, but in some of these cases one often finds the bradycardia is more apparent than real, inasmuch as the slow pulse is really due to premature ventricular contractions too weak for the corresponding pulse beat to reach the radial.

§ 107. *Classification of cases.*—There are rare cases where the pulse is abnormally slow continuously, but where the cause is very obscure. In order to differentiate the different forms it is necessary to make observations on the movements of the various chambers of the heart. While one is not able to give a satisfactory explanation of the signs thus afforded, yet the noting of the different forms of arrhythmia helps towards a classification. So far, I find from this point of view that the slow pulses can be included under three classes: first, where all the chambers of the heart participate in the slow action; second, where the slow pulse is due to a missed beat, the ventricle having contracted, but the resulting pulse wave being too feeble to reach the wrist; and third, where there is evidently some inhibitory influence preventing the ventricle responding to the usual stimulus after the auricular systole.

§ 108. *The slow pulse with rhythmical action of all the heart chambers.*—The only way to demonstrate that three out of the four chambers participate in the slow action of the heart is by taking simultaneous records of the radial and jugular pulses,




FIG. 116.—A normal slow pulse, showing variations in the duration of the diastole.

if a jugular pulse be present. In the jugular pulse one can compare the time of the movements due to the right auricle and ventricle with the radial pulse, and examples will be given when the jugular pulse is described (see Fig. 199). All the instances included in paragraph § 104, on the normal slow



pulse, have been of this form. The pulse in such cases rarely falls below forty, and I doubt if the chambers ever contract rhythmically when the pulse falls below thirty. In all slow pulses there is usually a slight irregularity consisting in varying duration of the diastolic period. Thus in Fig. 116 the systolic periods are identical in duration, while there are distinct variations in the length of the diastolic period.

§ 109. *The slow pulse due to missed beats.*—In describing the irregularities of the pulse one phase of this subject was dealt with in discussing the cases where the alternate beat of the heart was of the nature of a premature systole, whose arterial wave could not be recognised at the radial artery (Figs. 80 and 81). The pulse in such cases is then often found to be extremely slow, sometimes falling to between twenty and thirty beats per minute. Most frequently this form of pulse is associated with advanced valvular disease of the heart (Figs. 218 and 219).

§ 110. *The slow pulse due to inhibition of the ventricle.*—There is another series of cases where the pulse frequently falls below thirty beats. The conditions giving rise to the infrequent pulse are obscure, but there seems good reason for surmise that the slow action of the ventricle is due to some inhibitory influence affecting the ventricles alone, for the right and left auricles can sometimes be demonstrated to be acting at regular and more frequent intervals. A typical instance will be described and illustrated later (Chapter XXVII). I am inclined to think that many of the extreme cases of bradycardia recorded in medical literature belong to this class.

## CHAPTER XIII

### THE PULSE IN FEBRILE CONDITIONS

- § 111. Response of the circulation to fever depends mainly on the nature of the poison.
- 112. The pulse in ague.
- 113. Response of the circulation to increased temperature.
- 114. The pulse in sthenic fever.
- 115. The pulse in asthenic fever.
- 116. Varied reaction to fever according to idiosyncrasy and nature of poison.
- 117. Increase of temperature without increase of pulse rate.
- 118. The pulse in pneumonia.
- 119. Summary.

§ 111. *Response of the circulation to fever depends mainly on the nature of the poison.*—The whole circulatory system is remarkably sensitive to alterations in temperature. The slightest change in temperature, whether arising from external sources or due to changes within the body, affects the whole circulatory apparatus. But while the mere rise of temperature does materially affect the circulation, it is not the main element that causes the changes in the pulse which we associate with the febrile state. In all morbid processes giving rise to increased temperature there are absorbed into the system certain materials that act as poisons or drugs on some portion of the nervous or muscular mechanism of the circulation. As these poisons are of infinite variety, we get as a result a great diversity of pulse. It is the effects of these poisons on the pulse that gives us often the most efficient means of recognising the course of the disease. We cannot always tell how these poisons act, but by numerous observations we acquire a knowledge whereby we can foretell the possible significance of certain manifestations.

§ 112. *The pulse in ague.*—No better illustration of the effects produced by agents other than the temperature in modifying the pulse can be observed than what occurs during

an attack of ague. In the course of twenty-four hours with a continuously high temperature we have a remarkable series of changes in the pulse. During the cold stage the pulse becomes small and scarcely perceptible on account of the contraction of the peripheral arteries. The blood driven from the surface and from the arterial system accumulates in the venous system and in the internal organs. Then the lips and fingers become blue, and the congestion of internal organs may reach such a degree that capillary hæmorrhages occur within them. Within a few hours, the temperature still being high, the arterioles relax, the arteries become larger, and the pulse itself is of considerable force.

§ 113. *Response of the circulation to increased temperature.*—While, then, the action of those poisons is the main cause in producing alterations in the pulse, there is no doubt that, as a rule, the accompanying increase of temperature has a decidedly modifying influence. If we simply increase the body heat, as by a warm bath, we produce marked alteration in the pulse. The arterioles dilate; less resistance being offered to the heart, it beats more rapidly, while the pulse becomes larger and softer. In most febrile conditions, when the poison does not materially affect the nervous system, the influence upon the circulation has much the same result. We note that there is an increase in the rate corresponding more or less accurately with the rise in temperature. Roughly speaking there is an increase of ten beats with each rise in temperature of one degree Fahrenheit. This does not hold exactly, but we come to associate the state of the temperature with a certain average pulse rate, and considerable departures from this correspondence should always excite extreme watchfulness. Similarly there is a certain correspondence in the character of the pulse. If we pass the finger lightly along and across the artery we notice that the artery itself is larger. On compression the beat is found to be of considerable size and strength. In the diastolic period the dicrotic wave may be felt quite distinctly, but even if not evident a certain amount of resistance is offered to the compressing finger. When these characters are present we feel assured that the tone of the heart is satisfactory.

§ 114. *The pulse in sthenic fever.*—Such may shortly be considered the condition in what is termed “sthenic fever,” when the cause of the increased temperature has no depressing effect



upon the heart or nervous system. The series of tracings from Figs. 117-121 illustrates a sthenic type of febrile pulse. The

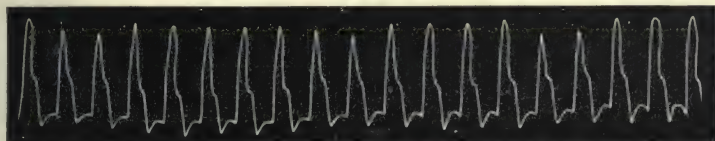


FIG. 117.—Rapid pulse with T. 104. This and the following four tracings illustrate the pulse in sthenic febrile condition.

fever may attain its highest degree very speedily. In Fig. 117 the temperature was  $104^{\circ}$ , the pulse one hundred and fifty, a rapid pulse with low arterial pressure, a condition of some gravity




FIG. 118.—Febrile pulse, T. 102.5. The pulse is slower, so that the descending limb of the diastolic wave falls nearly to the level of the aortic notch.

if it persists. Next day the temperature fell one degree (Fig. 118), and the pulse is materially altered, the chief feature being the marked diastolic wave. In Fig. 117 the rate of the pulse

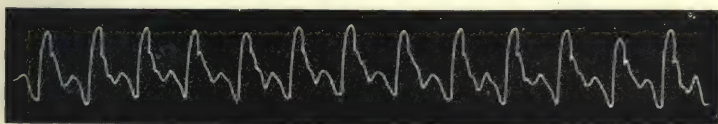


FIG. 119.—Febrile pulse, T. 101.5. The aortic notch is now at a higher level.

was so great that the diastolic wave was interrupted at its highest by the next pulse beat, while in Fig. 118, the pulse rate being slower, there is a fall in the tracing after the diastolic




FIG. 120.—Febrile pulse, T. 100.5, P. 100. It is now a well-marked diastolic pulse.

wave nearly as low as the bottom of the aortic notch. Hyperdiastolism, as has already been said (§ 19), is mainly due to the occurrence of a pulse beat interrupting the fall of the diastolic

wave before it falls as low as the aortic notch. The gradual increase in the rise of the aortic notch is the characteristic feature in the next three tracings, Figs. 119, 120, and 121,

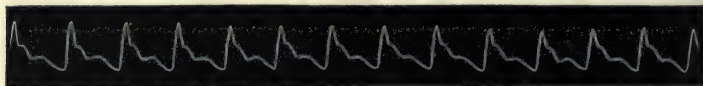


FIG. 121.—Temperature normal, P. 100. Though the rate is the same as in Fig. 120 the dicrotism is not so marked.

indicating a reduction of the rate of the pulse as well as an increase of the arterial pressure.

§ 115. *The pulse in asthenic fever.*—The ominous signifi-




FIG. 122.—Febrile pulse of low arterial pressure, T. 103, P. 116, R. 36. This was taken eight hours after the rigor at the beginning of a pneumonia. This and the four following tracings show a type of asthenic pulse.

cance of the absence of the dicrotic wave and of arterial pressure during the diastolic period is well illustrated in Figs. 122-126,




FIG. 123.—T. 101.5, P. 96, R. 28—second day.

which may be taken as characteristic of a form of “asthenic” pulse. This series was taken from a strong youth during an




FIG. 124.—Asthenic type of pulse with well-marked systolic wave *s*, and only a faint indication of the dicrotic wave *d*—third day.

attack of pneumonia. Fig. 122 was taken eight and a half hours after the rigor. The artery was large and full, but extremely soft and compressible between the beats. The pulse

beat itself was of little strength. Although the temperature was  $103^{\circ}$ , the rate—one hundred and sixteen—was not excessive. But the bad feature about the pulse was the slight resistance offered to the compressing finger, and the




FIG. 125.—T. 103, P. 124, R. 48—fourth day.

absence of any dicrotism. This is an invariably bad sign in a febrile pulse at the early stage, when the disease has to run a lengthened course. The tracings taken on successive days all too surely heralded the fatal termination. These are all

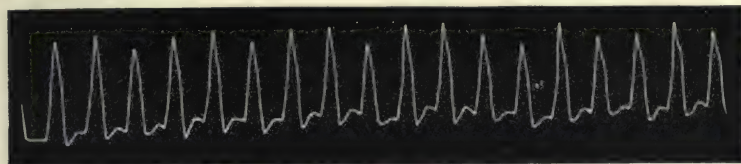


FIG. 126.—T. 102, P. 148, R. 52. The irregularity and rapidity of the pulse heralded the fatal end on the fifth day.

characterised by the extremely small degree of arterial pressure during the ventricular diastole. On the fifth day the pulse had reached the rate of one hundred and forty-eight, and he died that evening.

§ 116. *Varied reaction to fever according to idiosyncrasy and nature of poison.*—No law can be laid down for the response of patients to fever. Individuals react differently to the same stimuli. The normal pulse rate and the characters of the pulse have all some slight peculiarity, and when a stimulus altering a pulse rate is applied the difference is still marked in the response. As pulse rates quicken, however, there is a tendency to similarity in all individuals. Apart from the peculiarities of individual patients, the nature of the poison has a distinct effect upon the pulse. Although ague has been cited as evidence of this statement, yet there are numerous less marked instances occurring in general practice which merit more than a passing notice. The changes due to the nature of the poison may not be so strikingly demonstrated in studying different individuals as in studying



the effects on one individual. Thus Figs. 127-132 are from the same individual at different periods. He is a healthy man of middle age, with a slight tendency to obesity. Fig. 127 is a




FIG. 127.—Tracing from a pulse of low arterial pressure from a healthy man. The following five tracings from the same individual show a varied reaction in different febrile conditions.

tracing of his pulse when he is in good health—a regular pulse of rather low arterial pressure. He is subject to slight attacks of cold, with stuffiness of the nose. Figs. 128-131 are tracings of




FIG. 128.—T. 99·5, P. 92, slight coryza.

his pulse during these mild febrile attacks. In Fig. 128 (February 1891) the temperature is raised one degree, the pulse has quickened twenty beats over normal, and the character of

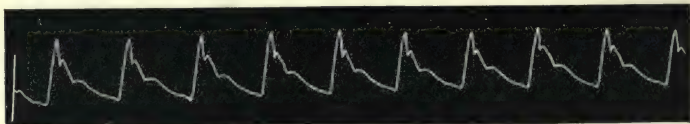


FIG. 129.—T. 99·5, P. 86, slight coryza.

the pulse is one of extremely low arterial pressure,—to the finger full, soft, and readily compressible. Fig. 129 was taken during a similar attack in January 1893. The temperature is again




FIG. 130.—T. 101·5, P. 96.

raised one degree, yet the pulse is six beats in the minute slower and the arterial pressure not perceptibly altered from normal. When the temperature is raised to 101°, as in another attack in

August 1892 (Fig. 130), there is a lowering of pressure similar to what occurred in tracing Fig. 128. In August 1894 this patient had another febrile attack for which no definite cause could be assigned, the only peculiarity being painful twitchings of many of the trunk muscles. The temperature is 102.5, the pulse only seventy-six, and the pulse beats strong and the pressure between also high,—in fact, a rather incompressible

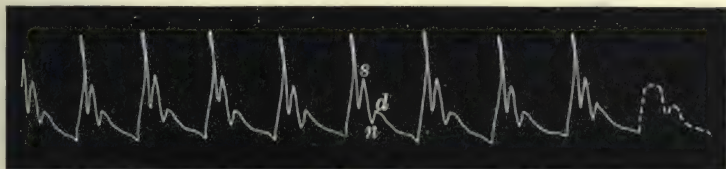


FIG. 131.—T. 102, P. 76.

pulse. The tracing (Fig. 131) shows these points,—the high upstroke due to the sudden propulsion of the lever above the systolic wave, and as the lever falls it rebounds again, giving rise to the second sharp wave. The dicrotic wave is distinct though not large, and the descent is gradual. All these characteristics point to a powerful heart acting against high arterial pressure. A similar tracing (Fig. 132) is seen again during a febrile attack in 1897. When the last two tracings were taken we can safely

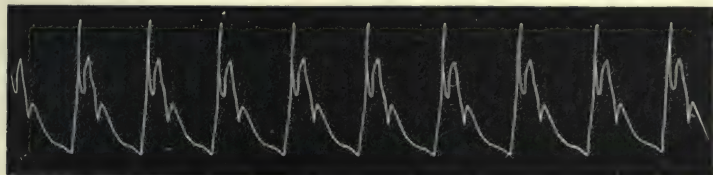


FIG. 132.—T. 100, P. 78.

surmise that the temperature had excited the heart to violent exertion, and yet some element was preventing the arterial relaxation that accompanies increased temperature.

§ 117. *Increase of temperature without increase of pulse rate.*—Increase of temperature without a corresponding increase of the pulse rate is by no means a rare occurrence. Its significance is of very varied importance. In the mild attacks of fever just alluded to, the absence of pulse quickening with increased temperature was neither accompanied nor followed by any disagreeable symptoms. A similar condition is occasionally

met with in the early stages of influenza. In typhoid fever a pulse of seventy to eighty per minute, with temperature of  $102^{\circ}$  or  $103^{\circ}$ , is sometimes met with. Fig. 133 is a tracing from such a case. The marked dirotism here is a striking contrast to the characters of the tracing in Figs. 131 and 132, where there was also a relatively slow pulse with an increased rise in temperature. The difference seems to be due to the fact that the arterial relaxation was much greater in the typhoid case (Fig. 133) than



FIG. 133.—Dirotic pulse from a patient with typhoid fever, P. 70, T.  $103^{\circ}$ .

in the others, so that less resistance was offered to a heart not acting with the same vigour. When the general condition of the patient presents no serious symptom the slow pulse in typhoid is rather a favourable sign than otherwise, indicating as it does a fair amount of reserve heart power. But when the slow pulse and high temperature are associated with such cerebral symptoms as delirium or unconsciousness, the condition is then a very grave one. I have only seen a few cases of rheumatic fever with these conditions, and they all ended fatally. Fig. 134 is from a man

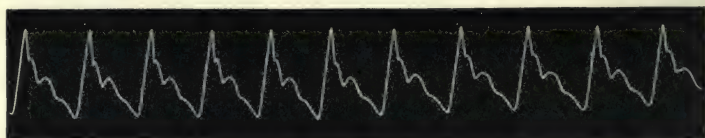


FIG. 134.—Slow pulse in rheumatic fever with cerebral symptoms, T.  $102.2$ , P. 96. This and the two following tracings are from the same patient.

aged thirty-five years suffering from rheumatic fever. The patient had just recovered from a mild attack when he was seized with a second, at first apparently of a mild and similar character, with the exception that the pulse did not quicken with the fever. The temperature gradually rose to  $102.5$ , and the pulse rate remained at ninety-six. Slight variations in temperature and pulse continued for a week, and delirium gradually supervened till the temperature rose to  $104^{\circ}$ , while the pulse fell to eighty beats per minute (Fig. 135). The pulse was firm and hard, and it is evident that the heart was acting



strongly against great arterial resistance. The same evening the temperature rose to  $105^{\circ}$ , and the pulse suddenly changed in its

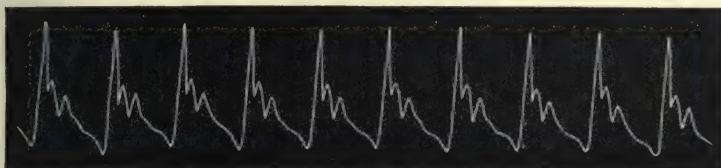


FIG. 135.—T. 104, P. 80.

character, became quick, soft, and irregular, as in Fig. 136—a change that heralded by a few hours the fatal termination.

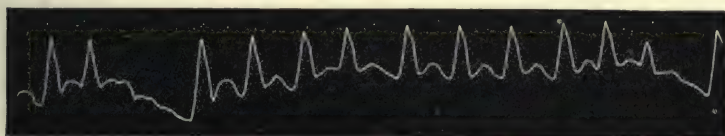


FIG. 136.—Quickened irregular pulse due to sudden failure of the heart, P. 116, T. 105.

In tuberculous meningitis the pulse, notwithstanding the temperature, is sometimes slow. Fig. 137 is from a young man

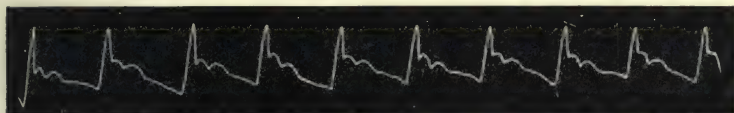


FIG. 137.—Slow irregular pulse in tuberculous meningitis, T. 102, P. 84.

two days before he died. He was unconscious, the temperature  $102^{\circ}$ , and the pulse eighty-four per minute. It presents the form of irregularity that I have referred to as the youthful type.

§ 118. *The pulse in pneumonia.*—On account of the differences in the action of the various poisons that cause the fever, it is difficult to make strict deductions. Nevertheless one gets into the habit of formulating certain definite ideas that guide one in estimating the severity of a febrile complaint. In pneumonia, for instance, the amount of arterial pressure, the rate of the pulse, and its rhythm, are each of them often among the most important indications we possess. Within a few hours after a rigor the fatal termination may be too plainly foretold by the character of the pulse. In the series of tracings Figs. 122-126 this is plainly discernible. The first of these, taken eight and a half hours after the rigor, presents such a soft pulse

that, taking into consideration the other symptoms which pointed to a commencing pneumonia, only the gravest issue could be apprehended. This is not an exceptional occurrence, for many of the fatal pneumonias that strike down healthy and vigorous youths present the same pulse peculiarity. The proximate cause of this softness of the pulse is, I suspect, to be found in an accompanying myocarditis. The specific germ has evidently attacked the myocardium as well, and pericarditis can sometimes be detected. The rate of the pulse is also sometimes of great significance. In adults a pulse of over one hundred and thirty-five per minute is a sign of serious danger. I have rarely seen an adult patient with a pulse over one hundred and forty recover. I have already pointed out that an irregularity, however rare, occurring in a pulse before the crisis is a very ominous sign (§ 97).

The pulse irregularities in fever have already been dealt with (§ 96).

§ 119. *Summary.*—It is impossible to give within reasonable limits anything like definite directions for the recognition of the significance of the febrile pulse, even if one were capable of doing so. Some points that are of value in putting to use one's experience in actual practice I give here for what they are worth.

Increased rate beyond what we would consider normal (to the degree of fever) is not of the same significance at the beginning of a febrile complaint as it is at the end. The pulse rate may be increased greatly at the beginning of an attack of scarlet fever, or follicular tonsillitis, and yet the subsequent course of the disease may be quite favourable. Persistent increased rate towards the end of such diseases as pneumonia and typhoid fever is of grave import, as it often implies serious exhaustion of the heart. Slowing of the pulse is of variable significance. It may be due to the nature of the poison causing the fever, or it may be due to the idiosyncrasy of the patient. In estimating the value of this symptom not only should these points be kept in view, but so far as my limited experience goes, the presence or absence of marked cerebral symptoms is of the greatest moment. If the patient's delirium comes on and increases with slowing of the pulse—and such slowing is often periodic—then one should consider it a very grave symptom. If mental symptoms are absent, then one should be watchful but not alarmed.

The strength of the pulse is perhaps of greater significance than the rate. This has been insisted upon in dealing with the asthenic febrile pulse. In other conditions than in pneumonia the nature of the poison has to be considered. Thus a pulse of one hundred and twenty with a temperature of  $102^{\circ}$  is not uncommon in the puerperium. But if at the same time the pulse is weak and soft and the patient sallow and exhausted, then the possibility of the presence of dangerous puerperal septicaemia must be considered. In all febrile cases, medical or surgical, when the course of the disease is prolonged, the condition of the arterial pressure should always be carefully observed.

Associated symptoms also help much in guiding one to a safe conclusion. The aspect of the face, whether full and tinged with the dilated capillaries in sthenic fever, or pale and drawn with the empty capillaries due to an exhausted heart, gives one a clue. The mental condition of the patient is also a fairly constant indication of the state of the heart's power. When the pulse is becoming dangerously weak, the patient's mind may wander, a drowsiness and indifference to his condition may supervene. On the other hand, the power of the brain to reason clearly, and to be interested in extraneous matters may indicate the retention of considerable cardiac power. The condition of the respiration, apart from pulmonary complaints, is important. The increase in the rate of the breathing, with the movements becoming shallower, is a sure indication that stasis is beginning at the bases of the lungs—a sign of heart exhaustion. The state of the tongue is always well worth careful scrutiny, the earliest signs of cleaning being often the first precursor of improvement in the patient's condition.



## CHAPTER XIV

### SOME CHARACTERISTIC PULSES

- § 120. Conditions giving rise to some characteristic pulses.
- 121. The pulse of aortic regurgitation.
- 122. The alleged delay of the pulse in aortic regurgitation.
- 123. The pulse in aortic stenosis.
- 124. The pulsus bisferiens.
- 125. The pulse in aortic aneurysm.
- 126. Blocking of the lumen of an artery.
- 127. Atheroma of the arteries.
- 128. The mitral pulse.

§ 120. *Conditions giving rise to some characteristic pulses.*—There are a few pulses so modified that their character indicates the diseased condition giving rise to their peculiarity, but these only occur where the defect exists in the channel conveying the pulse wave. The force producing the wave (contraction of the left ventricle) varies only in strength, rate, and rhythm, but no distinctive pulse is produced by any given modifications of the ventricular systole. But when the current of the blood stream is modified, a variety of pulses may be recognised, and the modifications can be referred to certain defects in the channel, at the aortic orifice, or in some part of the arterial wall.

§ 121. *The pulse of aortic regurgitation.*—The most striking modification of the pulse is that which we find in cases of incompetence of the aortic valves. Normally, arterial pressure during the diastolic period of the cardiac cycle is maintained by the contraction of the elastic coat of the arterial wall on the column of blood in the arteries, the elastic coat having been stretched by the forcible injection into the artery of the contents of the left ventricle. The column of blood is supported by the intact aortic valves, and the escape of the blood is gradual, being regulated by the muscular fibres in the walls of the arterioles. When the

aortic valves are incompetent the blood escapes back into the ventricle as well as through the capillaries. In consequence of this there is an abnormal fall of the arterial pressure during the diastolic period of the cardiac cycle. In order that the tissues should be properly nourished the maintenance of a certain degree of arterial pressure is necessary. The fall during the diastole being so great, the left ventricle endeavours to make good this deficiency by more powerful contraction and, with increased work;

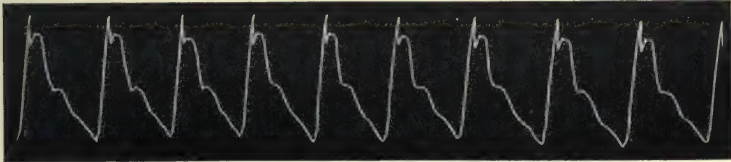


FIG. 138.—Pulse of slight aortic regurgitation with fair compensation.

hypertrophies, so that while the mean arterial pressure is made good the difference between the extremes of pressure is much exaggerated. Thus the pressure in the arteries at the end of diastole is far below normal, while during systole it is far above normal. The pulse is therefore characterised by a sudden strong impact quickly and suddenly falling away, leaving the impression of no resistance to the finger during the diastolic period,—the water-hammer pulse or Corrigan's pulse. The sphygmographic

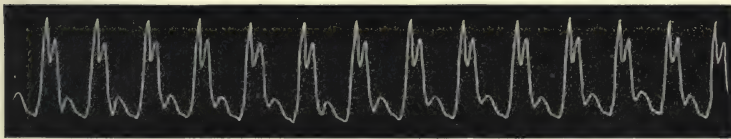


FIG. 139.—Pulse of slight aortic regurgitation with great cardiac failure.

tracings show these peculiarities, as in Fig. 138. There is the sudden upstroke due to a powerful ventricle operating against slight-resistance; the systolic wave due to the continuance of the ventricular outflow maintained for a short period; the sudden fall, interrupted low down by a temporary maintenance of the pressure rather than by a wave representing a dicrotic wave. The dicrotic wave may be well marked, but falls low down, as in Fig. 139. Such are the characters of a tracing when the regurgitation is not extreme, and where the aortic valves still offer a certain amount of resistance to the back flow. When

the shrunken aortic valves offer little or no obstruction to the regurgitating blood the tracing represents a fall nearly as abrupt as the rise (Fig. 140). There is here only an occasional trace of




FIG. 140.—Pulse of extreme aortic regurgitation.

the dicrotic wave *d*, while the pressure in the arterial system offers so slight a resistance that the character of the systolic wave is obscured by the height to which the lever is jerked.

Other peculiarities occur, due to the extreme and sudden changes in arterial pressure. The intermittent character of the blood flow may be continued through into the capillaries, and even into the smaller veins (§ 140). The arteries become distended and much more tortuous. The great and sudden changes of pressure induce degenerative changes in the arterial walls, and this again increases the work of the heart. Ultimately a point is reached when the hypertrophied heart is no longer able to maintain the blood supply in such quantity as to ensure the due functional ability of the tissues, and the field of response becomes gradually more and more restricted, till complete failure of the heart ends the struggle.

§ 122. *The alleged delay of the pulse in aortic regurgitation.*—An alleged characteristic supposed to belong to the pulse of aortic regurgitation is a marked delay in the transmission of the pulse wave from the heart to the carotid and radial arteries. This idea has been taught by the most expert clinical observers, and many curious explanations have been elaborated to account for the delay. The observer who first described it seems to have been Henderson<sup>29</sup> in 1837. His observation has been confirmed by such writers as Flint,<sup>30</sup> Balfour,<sup>31</sup> and Broadbent.<sup>32</sup> If confirmation was desired upon any point in clinical medicine, such names as these would at once command universal respect. So strong indeed is the value of their testimony that teachers of to-day who consider themselves men of independent judgment and untrammelled by precedent, are demonstrating this supposed delay to their students. For many years I fully believed this view, and although I could never myself discover it, I naturally



attributed this to a want of delicate perception on my part. About ten years ago I thought I would see by the simultaneous recording of the various movements to what an extent this delay occurred. But I could not get any evidence of delay, and fancied that it might occur in certain cases only, although Balfour says: "This delay in aortic reflux is invariable . . . the only apparent exceptions being those cases in which the delay is so great that the radial pulse coincides with the ventricular systole immediately succeeding that which has produced it."

I have therefore continued to examine a large number of cases, watching them until they died, and have had the diagnosis confirmed by *post-mortem* examination, and in no single instance have I been able to detect the slightest delay. After I had published the results of my observations in the *Edinburgh Medical Journal*<sup>33</sup> a few years ago, I found that the same method of investigation had previously been employed by two very competent observers, namely François Franck<sup>34</sup> and Keyt.<sup>35</sup> The results obtained by both these demonstrated that there was no delay whatever in the appearance of the carotid or radial pulses. I am not aware that any tracings have been taken demonstrating the delay, and as the observation depends upon the sensations of the observers alone we may justly conclude that this is an instance where even the most acute minds have been led astray by a preconceived idea.

In all probability, the reason for ascribing a delay in the propagation of the pulse wave has arisen through a misconception of what really occurs in the artery during the diastolic period. Some writers have imagined that the artery actually becomes empty, and that instead of a wave being sent along a column of blood, the wave is really the blood injected by the ventricular systole,—a wave of translation, not of transmission. As a matter of fact the artery is never empty, and the rate of the propagation of the wave of transmission is always the same. Thus in Fig. 141 there is a simultaneous tracing of the carotid and radial artery from a case of aortic regurgitation. I had this patient under my care for six years, and he died from heart failure, and at the *post-mortem* examination there was found a greatly hypertrophied left ventricle, and the aortic valves were extremely shrunken. In this tracing, taken with a von Jacquet sphygmograph, the first portion was taken while the paper was travelling at the more rapid rate, while the latter portion was taken when the paper was travelling slower. The time markings

represent one-fifth of a second. The space (*o*) within the dotted lines represents the loss of time between the appearance of the carotid pulse and the appearance of the radial, *i.e.* about  $\cdot 08$  a

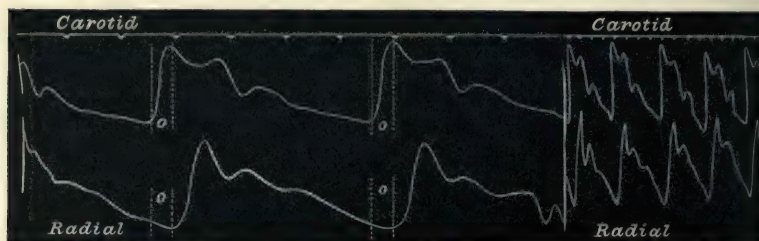


FIG. 141.—Simultaneous tracings of carotid and radial pulses, from a case of aortic regurgitation. The first portion of the tracing was taken when the paper was moving at the more rapid speed. The difference in time (*o*) between the carotid and radial pulses corresponds with that in Fig. 142.

second. In Fig. 142 simultaneous tracings of carotid and radial are taken with the same instrument from an individual with a healthy heart, and where the pulse rate was nearly the same as

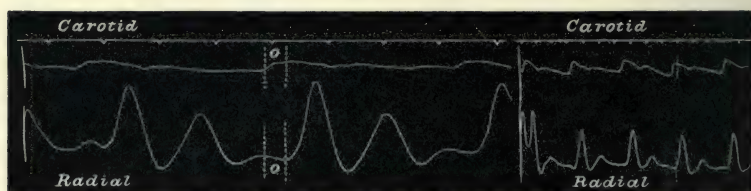


FIG. 142.—Simultaneous tracings of the carotid and radial pulses, from a case of phthisis with a healthy heart.

in the patient with aortic regurgitation. The space (*o*) representing the radial carotid interval is identical with that in Fig. 141, *viz.*  $\cdot 08$  of a second.

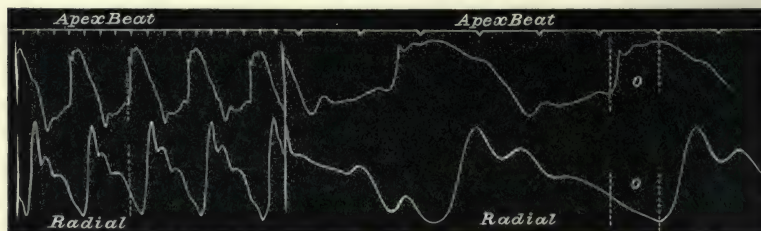


FIG. 143.—Simultaneous tracings of apex beat and radial pulse, from a case of aortic regurgitation. The interval (*o*) between apex beat and radial exactly corresponds to that in Fig. 144.

The heart radial interval shows the same correspondence (Figs. 143 and 144). The space (*o*) represents the period of time

between the beginning of the apex and the appearance of the radial pulse, and lasts  $\cdot 17$  of a second in both cases. These periods are in agreement with the periods given in physiological text-books. The essential fact, however, is that the intervals are




FIG. 144.—Simultaneous tracings of the apex beat and radial pulse, from a case of phthisis with a healthy heart.

practically identical both in healthy subjects and in patients suffering from free aortic regurgitation, and there is no evidence of the extreme loss of time in the appearance of the radial pulse that the writers referred to have thought they detected.

§ 123. *The pulse in aortic stenosis.*—Hürthle<sup>36</sup> and others have demonstrated that when the ventricle contracts against a high arterial pressure there is a gradual increase of the ventricular force towards the end of systole. When there is marked narrowing of the aortic orifice the full effect of the ventricular systole upon the arterial column is not at once developed, as the aortic stenosis offers an increased resistance. The contracting ventricle




FIG. 145.—Anaerotic pulse from a case of aortic stenosis.

raises the arterial pressure in a more gradual fashion. Hence the impact of the pulse wave on the finger is not sudden, but feels to push against the finger in a somewhat leisurely fashion. The tracing in such a case represents a slanting upstroke with an interruption near the top,—an anaerotic pulse tracing (Fig. 145). This is not due to any interruption in the contraction of the ventricle, but merely to the fact that the lever of the sphygmograph has been raised in the first instance slightly quicker than the following current of blood, and as the distending wave increases the returning lever is caught and carried along to the summit.



§ 124. *The pulsus bisferiens.*—It has been suggested that the ventricle contracts in two stages in certain cases of aortic stenosis, and that this is shown by the fact that the tidal wave is sometimes found split into two (Fig. 146)—the *pulsus bisferiens*




FIG. 146.—Pulsus bisferiens, from a case of aortic stenosis.

it has been called. I am somewhat doubtful whether after all the *pulsus bisferiens* may not to a great extent be artificial and due to instrumental defect. One might reason that a little more suddenness of the systolic wave might jerk the lever so as to change the interruption at (*b*) in Fig. 145 into a wave, as in Fig. 146. A split systolic wave can be demonstrated in many other cases where a strong heart is acting against a relatively low arterial pressure, as in atheroma, particularly if there is slight fever. Thus the first few beats in Fig. 147 might be said to

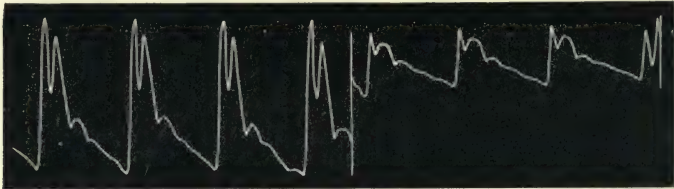


FIG. 147.—Showing the difference of the tracing got by changes of pressure applied to the artery.

represent a typical *pulsus bisferiens*. The full pressure of the instrument was applied here, and the strong acting heart jerked the lever higher than the pulse wave. The lever, falling with some force, is caught again on the full wave and jerked up, forming the second wave. When the pressure was diminished and the spring lay lightly upon the artery, the character of the tracing changed, as shown by the last three beats in Fig. 147. In the last three beats the lever does not rise so high and falls sooner, and follows the systolic wave more accurately. This was from a patient with atheromatous arteries, with a strong acting heart and free from valvular disease. I am disposed to distinguish the split tidal wave in this and similar instances from the true *pulsus bisferiens*, by the fact that in the true *pulsus bisferiens* the first of the two waves is always lower than the latter. But

this is a subject that requires more investigation than I have been able to give it (see Broadbent,<sup>37</sup> Graham Steell,<sup>38</sup> and J. Broadbent<sup>39</sup>).

§ 125. *The pulse in aortic aneurysm.*—Unless there be distinct narrowing of the lumen of the arteries, no evidence of the presence of the aneurysm is afforded by the examination of the radial pulse. When, however, a narrowing takes place, then a pulse similar in character to that of stenosis is found—a pulse wave whose extreme force is gradually attained, and this character is readily recognised by the finger. If the aneurysm or the narrowing of the lumen occurs in the aorta after the innominate artery has branched off and before the left subclavian has left the aorta, then a difference may arise in the character of the two radial pulses. The right radial pulse shall then have an impact more sudden than that of the left radial. The left radial is usually regarded in these cases as being delayed, and as appearing later than the right. I am inclined to believe that this is a false impression, due to the fact that the maximum

force of the impact in the case of the right radial pulse is felt suddenly and at the beginning of the pulse wave, whereas the maximum force in the left radial is reached gradually and towards the end of the ventricular systole.

In other words, the beginnings of the pulse waves are identical, but the maximum force of the pulse wave is delayed in the one case and not in the other. Thus one of my colleagues called my attention to the marked delay of the left radial pulse after the right in a case of aortic aneurysm in a female aged seventy-eight years. The first impression on comparing the pulse was certainly that the left radial followed the right, but on more carefully feeling the pulses, one could not be quite so sure that the beginning of the left pulse was behind that of the right. I took a series of tracings with apex beat and carotid as a standard, and found that there was no actual delay of the left pulse. Thus Fig. 148 shows the right radial pulse taken at the same time as the right carotid pulse. The upstroke of the right radial pulse is straight and reaches the maximum height at once. In Fig. 149 the

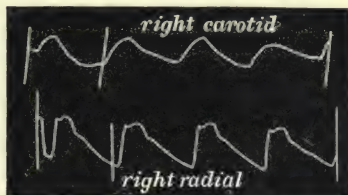


FIG. 148.—Simultaneous tracings of the right radial and right carotid from a case of aortic aneurysm.

left radial is taken at the same time as the right carotid. The upstroke of the left radial pulse is somewhat slanting and

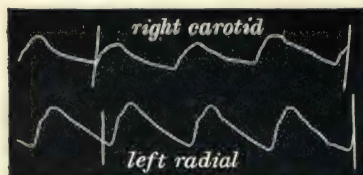

FIG. 149.—Simultaneous tracings of the right carotid and left radial, from the same patient as Fig. 148. The left radial is anacrotic, and seemed to the finger delayed behind the right radial, but the time of appearance of both radials behind the carotid is seen to be identical.

anacrotic, so that the maximum height of the wave is not reached till towards the end of ventricular systole, but the beginning of the radial pulse will be found to be exactly the same time behind the beginning of the carotid pulse as the beginning of the right radial.

I cannot see why there should be any delay of the pulse in case of aneurysm. The wall of the aneurysm is not contractible, but is always full and distended, and the heaving pulsation of

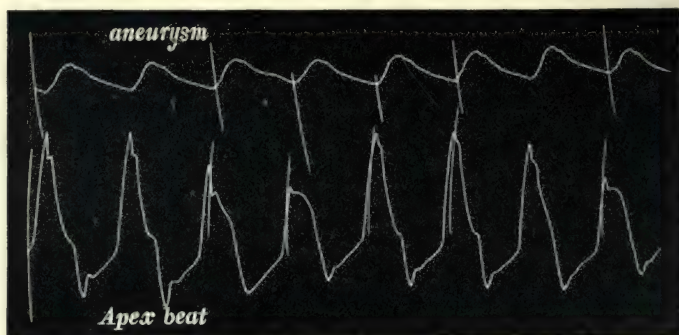


FIG. 150.—Simultaneous tracings from a large aneurysm pulsating in the second right intercostal space and from the apex beat.

the aneurysm is no more an evidence of contraction and expansion than is the beating of the carotid. In the most typical pulsating aneurysm of the aorta one finds no delay in the appearance of the radial pulse. Thus Fig. 150 was taken from a female with a large pulsating aneurysm of the aorta. The time of the appearance of the pulse in the aneurysm corresponds with the time of the appearance of the pulse in the pulmonary artery in Figs. 26 and 27. Fig. 151 is a tracing of the radial pulse simultaneously with the apex beat, from the same patient as Fig. 150. It will at once be seen that the radial pulse appears after the apex beat exactly at the same period of time as occurs in health and in patients free from aneurysm. (Compare with



Figs. 29 and 30.) In dealing with the venous pulse I shall have to demonstrate that when the right ventricle sends a wave of blood back into the veins, there is a distinct delay in the appearance of the wave when the auricle is active and capable of contracting. But in the case of the auricle we have to do with a muscular walled cavity, whose walls contract and in dilating naturally absorb the blood from the ventricle until the cavity is filled, and after that the wave is sent back into the veins. Hence a delay occurs before the wave due to the ventricular systole appears in the veins. Further, when the




FIG. 151.—Simultaneous tracings of the apex beat and radial pulse, from a case of aortic aneurysm.

auricle becomes paralysed from over distension, it no longer delays the blood coming from the right ventricle, but permits the wave at once to appear in the veins, just as the arterial pulse appears in passing through an aneurysmal dilatation of the artery. In other words, the ventricle, aneurysmal cavity, and arteries forming one continuous chamber, increase of pressure in the ventricle is reflected to all portions of the arterial system, according to the laws regulating fluid pressure. François Franck<sup>40</sup> goes so far as to say that there is a delay of the pulse in all arteries beyond an aneurysm. A critical examination of his tracings does not bear out his contention, in my opinion, and certainly my observations, as in Figs. 150 and 151, disprove it.

§ 126. *Blocking of the lumen of an artery.*—Other causes

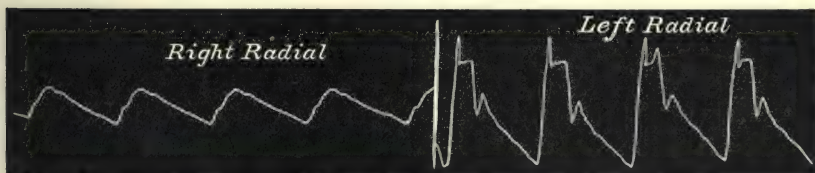


FIG. 152.—The right radial is anacrotic, due to the blocking of the lumen of the right subclavian artery by an atheromatous plate.

may interfere with the blood current in the arteries. Thus in Fig. 152 the right radial shows a slanting upstroke with an

anacrotic pulse wave, while the left radial shows a high upstroke and large pulse wave. The impressions conveyed to the finger exactly corresponded to what one would expect from the appearance of these two sphygmograms. The impact of the left radial was sharp and sudden, that of the right slow and gradual, and to the sense the impression was conveyed that the right radial pulse was delayed behind the left. But numerous observations demonstrated, as in the case of aneurysm, that the delay was but seeming, and that in reality the beginnings of the two pulses were identical in time. The patient was a man of fifty years of age with atheromatous arteries, and had had an attack of cerebral apoplexy. After death the cause of the small right radial pulse was found to be an atheromatous plate situated at the origin of the subclavian artery, and which projected so far into the lumen of the vessel that the lumen was narrowed to nearly one half.

§ 127. *Atheroma of the arteries*.—The progress of atheromatous degeneration in the arteries is practically the physical history of the individual after the zenith of his strength has been reached, accompanied by an imperceptible but progressive limitation of the field of his heart's response to effort. Although for long he may lead a vigorous life within this limitation, with no evident discomfort, yet during the fourth decade of life the ease with which violent efforts are made is gradually lessening, and violent exertions are as a rule carefully avoided. Running after trains is not to be done in comfort, and the ascent of hills is undertaken with more deliberation. All this proceeds *pari passu* with diminished resiliency of the arterial wall. So insidious is the progress of atheroma that it is usually well established before it is recognised. We may indeed suspect its presence before we can demonstrate it, because experience tells us it is a gradual process, and humanity in general is extremely liable to it. As the atheroma affects the elastic coat, the result is to diminish the elasticity of the wall of the arteries. These coats no longer efficiently store up the energy imparted to them by the ventricular systole, to liberate it during the ventricular diastole. The artery tends to become more or less of the nature of a rigid tube, and this is not so helpful in assisting the circulation of the blood nor in maintaining the equable flow through the capillaries. Hence the heart is stimulated to greater activity in order to maintain a mean pressure suitable to the due

supply of the tissues. Hypertrophy of the left ventricle results from this increased labour. Thus it is that during the systolic period the arterial pressure becomes raised, while it falls lower than the normal towards the end of diastole—similar to what happens in aortic regurgitation, but to a less degree.

The artery is usually of fair size, sometimes very large and tortuous, and can be rolled under the finger like a cord for a considerable extent up the arm. In extreme cases it has a beady feeling, as if little lumps of hard matter were embedded in the artery wall. The impact of the pulse wave is sudden and usually of considerable strength, and lasts for an appreciable interval. After the ventricular systole the arterial pressure quickly falls, and little resistance is felt during the diastolic period of the cardiac cycle.

The characters of the sphygmographic tracings sometimes resemble those of aortic regurgitation. Thus Fig. 153 is from an elderly man with large tortuous arteries. The upstroke is high and jerked beyond the systolic wave, the steep fall at the end

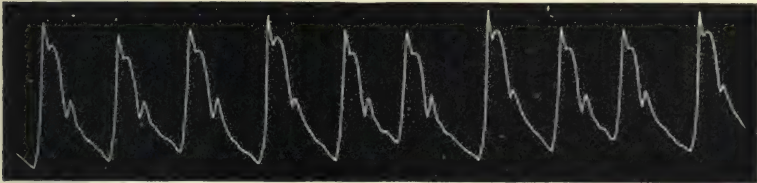


FIG. 153.—Tracing from a case with arteries large, tortuous, and atheromatous.

of systole is interrupted by a small dicrotic wave. These pulses often present a slight irregularity, scarcely perceptible to the finger, as in this tracing. When the artery is small these characters are not so marked, and little that is distinctive can




FIG. 154.—From a patient with small atheromatous arteries.

be made out save that the dicrotic wave is never large, as in Fig. 154. When, however, the heart is stimulated by febrile excitement the peculiar characters of the pulse in atheromatous arteries become apparent. Thus Fig. 155 is from the same patient with the temperature at  $100^{\circ}5$ . Here the upstroke is



jerked high, and in falling indents the systolic wave. The dirotic wave is quite at the foot of the tracing, and is much slighter than appears here, because the falling lever gives the notch an artificial depth. As a matter of fact, the small amount of dirotism is at all times a characteristic of the pulse in an

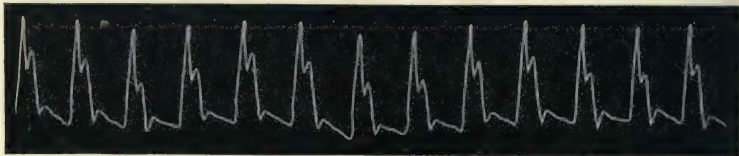


FIG. 155.—From the same patient as Fig. 154, during slight fever, T. 100°5.

atheromatous artery. When it seems large in the tracing it is partly artificial, on account of the jerking movement of the spring deepening the aortic notch. This is shown in Fig. 156, taken from the same patient from whom I got Fig. 153, during an attack of bronchitis with a temperature of 104°. The heart,

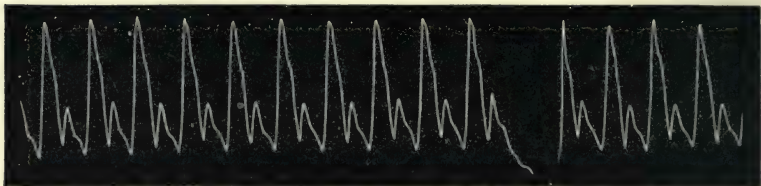


FIG. 156.—From the same patient as Fig. 153, during a febrile condition, T. 104.

stimulated by the fever, acts strongly, and as the resistance in the arteries is diminished the spring does not follow the extremes of pressure with accuracy, but is violently jerked with each variation in the pressure. Hence the various variations in pressure are not represented by rounded curves but by sharp angles.

For a time the hypertrophied heart may maintain the circulation at a fairly high level, but with increase of atheroma the heart's work not only becomes greater, but the heart becomes affected by the results of atheromatous degeneration. The arteries becoming atheromatous no longer supply sufficient nutriment to the overworked heart, and consequently degeneration of the muscle wall occurs, producing the varied symptoms of heart failure.

In many cases there is evidently a diminution of the quantity

of blood in the system. The veins are not so full, as one finds in early life, and there are distinctly fewer capillaries in the body wall. Thus in operating, while we may have more persistent bleeding from visible arteries, the general oozing from the cut surface is not nearly so free. This probably accounts for the attenuation of the skin and general shrivelling of the body noticeable in advanced age.

§ 128. *The mitral pulse.*—There is a pulse found so frequently in cases of advanced mitral regurgitation that the term mitral pulse has been applied to it. Although not coming within the category of pulses modified by defects of the channel, yet it deserves mention amongst the characteristic pulses. The mitral pulse is small and irregular. The irregularity may consist of the most diverse forms, full beats with small beats occurring sometimes at the regular intervals, sometimes prematurely. The premature beats again may be absent, or they may occur in groups. The pulse itself, though small, when carefully compressed reveals a fair amount of blood pressure. The features present in some mitral pulses are not absolutely distinctive, as similar features occur in irregular hearts without extreme regurgitation. But nevertheless these features are so common in advanced mitral disease as to give some justification for the term. Why does the pulse in advanced mitral disease so often assume this extreme form of irregularity? This question will be more fully considered later, but here I may point out that in these cases the regurgitation has become so great as to distend the auricle, so that it loses its power of independent contraction. When this happens it would seem that the faculty of contracting regularly had to a great extent been lost by the ventricle. I cannot satisfactorily explain why this should be so, but I have sufficient evidence to demonstrate that this irregularity does come on after the paralysis of the auricle (see Chapter XXVIII. and § 234).

## CHAPTER XV

### PULSE AND RESPIRATION

- § 129. Sources of error in making observations.
- 130. Variations in rhythm accompany variations in arterial pressure.
- 131. The influence of the respiratory movements on the circulation.
- 132. Effects of holding the breath on different pulses.
- 133. Respiration and blood pressure.
- 134. The pulse with slow respiration.
- 135. The pulse with laboured respiration.
- 136. The *pulsus paradoxus*.
- 137. Type of pulse irregularity due to respiration.

*Pulse and respiration.*—The subject of the relationship between the action of the heart and the respiratory movements is one of such extent and intricacy that I am incapable of dealing satisfactorily with it. I have indeed made numerous observations and have been able to draw a few limited conclusions, but there remains a large field for clinical research. The observations I make upon this subject are intended therefore more to excite consideration than to give a complete explanation of this subject.

§ 129. *Sources of error in making observations.*—Before entering upon this subject it is necessary to call attention to one or two ways by which fallacies are apt to creep into the observations. One of these is the noting of the variations of the pulse with the respiration from observation alone, without the simultaneous recording of both movements. It is impossible to tell with sufficient exactness the relationship of any given irregularity to a definite period in the respiratory movements. Irregularities in pulse rhythm may be wrongly associated with respiratory movements because of supposed agreement in rhythm, when it can be demonstrated that no such agreement exists. If, for example, one felt the pulse in such an instance as that represented in



Fig. 157, it would seem extremely probable that the rhythmical irregularity of this pulse corresponded with the rhythm of the respiratory movements. The duration of each of the pulse groups corresponds so nearly with the duration of a respiratory cycle, that relying on the senses alone one would be disposed to say that they agreed. Yet in the tracing it will be found that while there is a record of twelve groups of irregularities, there are eleven respiratory cycles (inspiration and expiration). The pulse is really of the type described before as the *pulsus trigeminus*, and the long pause will be found at one time or other to be coincident with every phase of the respiratory cycle.

In laboured breathing it is necessary to be very careful in taking a tracing. When the accessory muscles of respiration are called into play they may frequently cause slight movements of the arm. These movements, though scarcely perceptible to sight, are yet able to have a marked effect upon the sphygmographic tracing. Thus in Fig. 158, where the patient suffered from diabetic dyspnoea, the pulse tracing showed a marvellous excursion coincident with the respiratory movements. But when I laid hold of the condyles of the humerus, and steadied the arm, these excursions at once almost completely ceased, as in Fig. 159. In looking over pulse tracings by several writers, variations in the arterial pressure similar to those noted in Fig. 158 are depicted, and profound generalisations drawn from them. So far as I can see, they are entirely due to the movements of the arm, and have therefore no connection with variations of arterial pressure.




FIG. 157.—Simultaneous tracings of the respiratory movements and of the radial pulse, showing that there is no agreement between the pulse irregularity and the respiration.

§ 130. *Variations in rhythm accompany variations in arterial pressure.*—A very safe rule to be followed in doubtful tracings of this kind is to note if there be variations in the

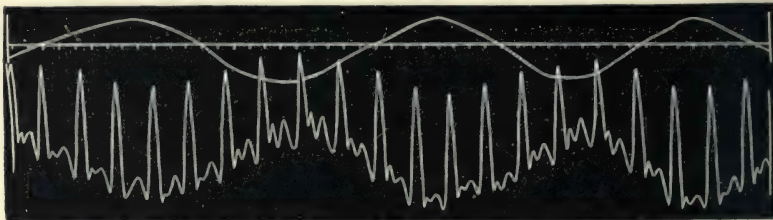


FIG. 158.—Simultaneous tracing of the respiratory movements and of the radial pulse, showing variations of the pulse corresponding with the respiratory movements, but actually due to the movements of the arm.

duration of the pulse beat. In nearly every instance where the arterial pressure varies (as it would do if Fig. 158 were really a simple tracing of the pulse alone), the duration of the

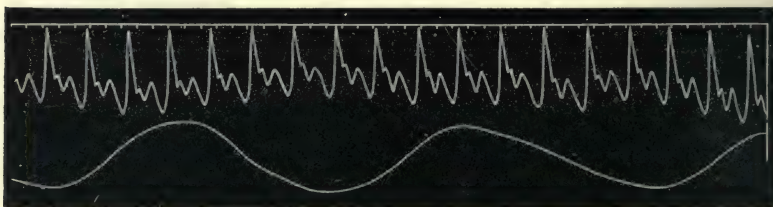


FIG. 159.—The same as Fig. 158, the arm being steadied.

cardiac cycle varies (Figs. 164, 165, and 166). Also when the pulse beat is evidently diminished in size through respiratory interference, its duration is likewise shortened (Figs. 173 and 174).

§ 131. *The influence of the respiratory movements on the circulation.*—The intrathoracic pressure, being below that of the atmosphere, favours the flow of blood into the chest. This influence is much greater during inspiration than during expiration. The flow of blood also through the lungs is greatly favoured by the movement of inspiration. It may also be inferred that these variations in intrathoracic pressure would have a distinct effect upon the thin relaxed walls of the auricle, particularly during inspiration. The pressure within the aorta is so great that the relatively slight variations probably have little effect upon it. It might reasonably have been assumed that this influence varying so much during inspiration and expiration would have given an intermittency to the blood current.

Of its effects upon the venous flow there can be little doubt, as in suitable cases the swelling of the neck veins during expiration and the emptying during inspiration is readily demonstrated. But the effects upon the arterial pulse are not so readily demonstrated. There may be variations which our methods of examination fail to make recognisable. As a matter of fact, in the vast majority of individuals, even in those in whom there is great stagnation of blood through cardiac failure, when the respiratory movements have a more pronounced effect upon the circulation than in health, not the slightest variation of the arterial pulse can be detected during ordinary respiration. Certain undoubted effects can be produced upon the pulse by making forced movements of inspiration and expiration, as in the well-known experiment of Valsalva.

§ 132. *Effect of holding the breath on different pulses.\**—Although in normal respiration no changes in the pulse can be detected, yet there are differences in the behaviour of the pulse when the normal respiratory rhythm is altered. Speaking generally, people with soft pulses show greater liability to variations than people with pulses of higher pressure. Thus in Fig. 160, when the breath is held at the end of a deep inspiration, with the exception of a slight slowing of the rate, there is not a greatly marked difference between the character of the pulse wave here and its character when the breath is held at the end of a full expiration, as in Fig. 161. These two tracings were taken from the same individual. Figs. 162 and 163 were taken from another individual, who has always a soft compressible pulse. When he held his breath at the end of expiration, little change could be detected in the character of his pulse, as in Fig. 162. But when he held his breath at the end of inspiration the pulse underwent a change of the most striking character, the pulse becoming extremely soft and markedly dicrotic, as in Fig. 163.

§ 133. *Respiration and blood pressure.*—I incline to think that the different reaction of the pulse in these two individuals is due to a difference in the arterial pressure. The former (Figs. 160 and 161) having a firm rather hard pulse, the latter (Fig. 162 and 163) having a soft, compressible pulse. In other ways we can sometimes demonstrate that low arterial pressure

\* In all these tracings the rise in the respiratory curve is due to inspiration and the fall to expiration.





FIG. 160.—Simultaneous tracings of the respiratory movements and of the radial pulse. Breath held at the end of inspiration.




FIG. 161.—Simultaneous tracings of the respiratory movements and of the radial pulse. Breath held at the end of full expiration.

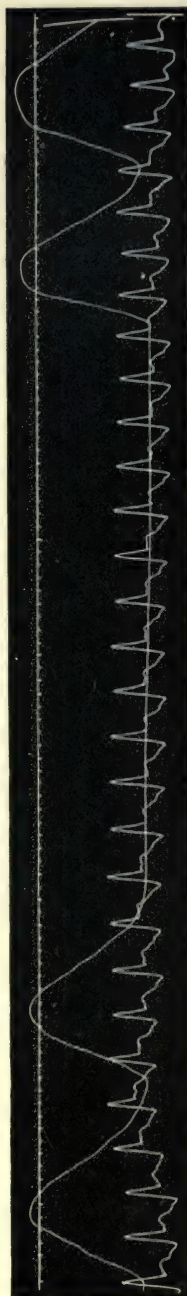


FIG. 162.—Simultaneous tracings of the respiratory movements and of the radial pulse. Breath held at the end of expiration.




FIG. 163.—Simultaneous tracings of the movements of respiration and of the radial pulse. Breath held at the end of inspiration.

appears to favour the influence of the respiratory movements upon the pulse. In Fig. 164 the variation in arterial pressure is well marked. During inspiration the pulse invariably becomes more dicrotic, while during expiration the aortic notch becomes raised. If the duration of each pulse beat be carefully measured there will also be found a distinct shortening of the beat with




FIG. 164.—Simultaneous tracings of a soft compressible radial pulse and of the respiratory movements, showing distinct increase of arterial pressure during expiration and diminution during inspiration. The pulse beats are also shorter during inspiration.

the increase in dicrotism. Although one but rarely meets with such distinct evidence of the variations of pressure as in this instance, lengthening of the beat during expiration is far from uncommon. A striking instance of this is seen in Fig. 165, where at the end of inspiration there is a distinct pause. A better illustration of what we may consider a normal respiratory irregularity is seen in Fig. 166. Here there is a periodic lengthening of the diastolic period every fourth or fifth beat.



FIG. 165.—Simultaneous tracings of the respiratory movements of a soft radial pulse, showing a long diastolic pause at the end of each inspiration.

The cause of these variations is far from clear. The mere alterations of intrathoracic pressure mechanically favouring the flow at one period and embarrassing it at another, as one observes in the veins of the neck during the respiratory movements, is not a sufficient explanation. In Fig. 166, for instance, although the irregular pulse is undoubtedly due to the respiratory movements, yet the irregularity does not exactly correspond to any definite period in the respiratory movement. This irregular movement seems due to the tendency of the heart to maintain an unusual rhythm when once it is stimulated thereto by some unknown



cause. We have already seen, as in Fig. 157, how it sometimes retains a rhythm even in its irregularities. Here the rhythm due to respiration is maintained even after the respiratory movement has ceased. Thus in Fig. 166, when the breathing was stopped, the lengthening of the beat occurred for one period as if the respiratory cycle had continued. The influence of the respiration upon the circulation therefore seems to be a somewhat complex problem. Some physiologists indeed make of it a very simple matter. Thus Waller<sup>41</sup> argues that when the arterial pressure increases the venous diminishes, and *vice versa*. During inspiration the venous pressure falls and the arterial rises, and during expiration the venous pressure rises and the arterial pressure falls. Fig. 164 would seem to show that, so far as the arterial pressure goes, the reverse of this is what really happens, while Fig. 166 would seem to indicate that some portion of the cardiac nervous mechanism is concerned. The three patients from whom these three last tracings were taken suffered from neither cardiac nor pulmonary complaints, and the breathing was quite normal at the time of the observation. The arterial pressure of Figs. 164 and 165 is markedly low, and, as already stated, I have found a greater tendency to this variation in people with normally low arterial pressure than in those in whom the pressure is high, just as the influence of deep respiration is more marked in the low pressure pulse than in the high.

§ 134. *The pulse with slow respiration.*—Before leaving the subject of normal respiration and the pulse, I would call attention to a peculiar rhythm of the pulse present when the respirations were abnormally slow. So far as I know, the question of increased or diminished rate of breathing as a normal condition has received little attention. It certainly does seem as if there were greater uniformity in the respiratory rate than in the cardiac. In one subject I found the normal rate of respiration to be seven per minute when he was lying down, his pulse rate then being fifty-eight, and eight per minute when he was standing, his pulse rate then being seventy. Nothing abnormal could be detected on physical examination, and he experienced no difficulty when undergoing exertion. In Fig. 167 his pulse and respiratory movements are given. Although the variations in the pulse rate are evidently cyclical, yet they bear no constant relation to the respiratory movement. When he held his breath at the end of full inspiration the pulse became at first markedly slow, then





FIG. 166.—Simultaneous tracing of the respiratory movements and of the radial pulse. The irregularities in the pulse correspond to the movements of respiration, and when the breath is held the irregularity persists for one period. The pulse irregularity is of the youthful type.



FIG. 167.—Simultaneous tracings of the respiratory movements of the radial pulse, from a case where the respirations were seven per minute. The pulse irregularities, though due to the respiration, have not a respiratory rhythm.




FIG. 168.—The breath is held at the end of inspiration.



FIG. 169.—The breath is held at the end of expiration.



FIG. 170.—At the end of the experiments the breathing quickened, and the irregular pulse corresponded to that of Fig. 166.

very dirotic (Fig. 168), while during cessation of breathing at the end of expiration no very marked change took place in the character of the pulse (Fig. 169). After making a series of observations, when the patient had held his breath several times for a considerable period, his breathing at first rose to the usual rate of sixteen per minute. A tracing (Fig. 170) taken at this time shows a variation in rhythm very similar to that in Fig. 166.

§ 135. *The pulse with laboured respiration.*—In cases where the breathing is laboured from any cause the pulse very frequently gives evidence of distinct variations with the respiratory movements. In Fig. 171, taken from a patient suffering from




FIG. 171.—From a case of bronchitis with laboured breathing. The respiratory movement was obtained by placing a receiver over the episternal notch, hence a fall in the tracing is due to inspiration, and a rise to expiration.

chronic bronchitis, there is a distinct fall in the tracing during inspiration, as if the laboured inspiratory effort had reduced the arterial pressure, either by sucking more venous blood into the chest, and thus expediting the flow from the arteries, or by embarrassing the outflow from the chest. There is a slight

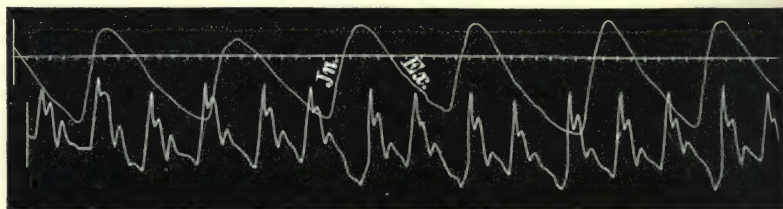


FIG. 172.—From a case of asthma. The rise in the respiratory tracing is due to inspiration, and the fall to expiration.

prolongation of the diastolic period of the pulse at the same time. In Fig. 172, taken from a patient during an attack of asthma, a very similar variation occurs. In Fig. 173, from a female, aged twenty, suffering from catarrhal pneumonia and capillary bronchitis, the temperature being  $105^{\circ}$ , the pulse has

a peculiar rhythm, the chief characteristic being a small short beat with each inspiratory movement, as if the inspiratory movement had modified the ventricular systole. A pulse very similar in character is seen in Fig. 174, but here the small beat




FIG. 173.—From a case of capillary bronchitis and catarrhal pneumonia.

is coincident with the beginning of expiration, while during inspiration there is invariably a large beat. This patient, a man aged fifty, had an aneurysm the size of a hen's egg on the aorta immediately above the aortic valves. This aneurysm had bulged against the right ventricle and pulmonary artery, so that




FIG. 174.—From a case of a small aneurysm of the aorta.

the latter could only admit a penholder. It is possible in this case that the movements of respiration caused the aneurysm mechanically to interfere with the flow of blood, and also modified the ventricular systole, at the end of inspiration or at the beginning of expiration.

§ 136. *The pulsus paradoxus.*—The best instances of mechanical interference with the blood flow are seen in adhesive mediastinitis. Unfortunately the few cases of this disease I have seen have not been under my own care, so I have had no opportunity of making observations of the pulse in these cases. None of the tracings from patients with this disease that I have seen published have had the respiratory curve taken at the same time, hence the exact relations of the different phases of the respiratory movements with the pulse variations are not capable of examination. The diminution or obliteration of the pulse during inspiration (*pulsus paradoxus*) is supposed to be character-



istic of this disease, but in the patient from whom I took the tracing Fig. 175 there was no adhesive mediastinitis. This tracing was taken from a youth in 1883, and at that time nothing abnormal could be detected, though his family history



FIG. 175.—Disappearance of the radial pulse in taking a deep inspiration.

was an extremely syphilitic one. Some few years later he developed a double aortic murmur, and at his death in 1894, with the exception of small shrunken aortic valves and an enlarged ventricle, no trace of disease could be found.

§ 137. *Type of pulse irregularity due to respiration.*—The question whether the irregular pulse of youth is not after all merely a variation dependent upon respiration has been raised in my mind. I made numerous observations, and found that the respiratory variations like Fig. 166 were common in the young, yet I have found the irregularity so frequently having no correspondence with the movements of respiration, that I have placed the two forms apart. It will be noted, however, that the character of the pulse when it is irregular with respiration in healthy people, is of the youthful type, the variation in rhythm mainly being during the diastolic period, and there being a total absence of premature beats.

## PART II

PULSATION IN THE VEINS AND LIVER





## CHAPTER XVI

### GENERAL INTRODUCTION

- § 138. What the venous pulse shows.
- 139. Movement of the blood in the veins.
- 140. Pulsation in the peripheral veins.
- 141. Movements in the veins due to respiration.
- 142. The Relation of the venæ cavæ to the venous flow.
- 143. Incompetence of the ostial veins.
- 144. Incompetence of the tricuspid valves.
- 145. Incompetence of the jugular valves.
- 146. Competence of the jugular valves.
- 147. Sounds produced by the stretching of the valves in the veins.
- 148. Inspection of the jugular pulse.

§ 138. *What the venous pulse shows.*—The consideration of the circulation has so far been mainly concerned with the effects of the contraction of the left ventricle. When the apex beat is studied or the characters of the arterial pulse analysed, our purview is limited almost entirely to the doings of the left ventricle. The arterial pulse indeed only gives us a direct knowledge of the left ventricle's action during but a portion of the cardiac cycle, namely, during the period when the aortic valves are open. When they are closed we are no longer directly cognisant of what is happening in the left ventricle. We come now to the study of a subject which gives us far more information of what is actually going on within the chambers of the heart. In the study of the venous pulse we have often the direct means of observing the effects of the systole and diastole of the right auricle, and of the systole and diastole of the right ventricle. The venous pulse presents therefore a greater variety of features, and is subject to influence so subtle that it may manifest variations due to the changing conditions of the patient, during which the arterial pulse reveals no appreciable alteration.

§ 139. *Movement of the blood in the veins.*—The main factor

concerned in the movement of the blood in the veins is the left ventricle. The force communicated to the arterial column is carried through the capillaries to the veins with sufficient strength to return the blood to the right heart. There are several subsidiary forces that help in causing the movement of the blood, such as the aspirating effect of the thoracic cavity, the movements of muscles in compressing the veins, gravity, etc. The various factors that cause the blood to move in the veins, though intermittent in their action, produce practically a steady stream through the greater part of the venous system.

§ 140. *Pulsation in the peripheral veins.*—At the two extremities of the venous system, however, there is a tendency, slight in health and exaggerated in certain forms of disease, to interference with this steady flow. The impulse of the left ventricle may still impress intermittency through the capillary circulation, and be manifested in the smaller peripheral veins, more particularly when there is great dilatation of the arterioles. This is shown in Bernard's<sup>42</sup> well-known experiment, where stimulation of the chorda tympani caused the arterioles of the salivary gland to become so dilated that the arterial pulse was transmitted to the veins. A similar pulsation had been previously demonstrated by Palmer<sup>43</sup> in the veins of a frog's leg, where, by compressing the vein, the pulsation of the arteries was transmitted through the capillaries to that portion of the distended veins distal to the point of compression. Clinically, it can sometimes be demonstrated in the veins on the back of the hand in aortic regurgitation, particularly during a febrile attack. But as the condition necessary to its production is merely great arterial relaxation, it may be found here in a slight form in a great variety of conditions, and is apparently without pathological significance, its presence often being quite consistent with perfect health.

§ 141. *Movements in the veins due to respiration.*—When the steady stream of venous blood approaches the heart, it is subjected to the intermittent influences of the respiratory and cardiac actions. There is no doubt that the rate of the venous flow into the chest is expedited during inspiration. In health there should be no visible stasis of blood, but, as will be shown later, the respiratory movements have a distinct influence on the curves produced by the pulsation in the veins. When a pulse is present in the veins there is of necessity distension of the vein,

and the distension varies with the movements of inspiration and expiration. But it is the movements communicated to the blood in the veins by the action of the right heart that form the subject of the present study.

§ 142. *The relation of the venæ cavæ to the venous flow.*—Although the flow of blood into the thoracic cavity is continuous, this can only occur while the venæ cavæ are capable of receiving the inflowing blood during the auricular systole. Naturally, during auricular systole the venous flow near the heart ceases. Usually the venæ cavæ are sufficiently capacious to receive the oncoming blood without distending the superficial veins. But when from any cause there is over distension of the veins, then this intermittency becomes evident in the internal jugular and other more superficial veins in the neck. Further, regurgitant waves are often sent into the veins by the contraction of the auricle and ventricle.

§ 143.—*Incompetence of the ostial veins.*—The veins near the heart are provided with circular muscular fibres. When the heart passes into systole it does so by a wave of contraction of the muscular fibres, beginning first at the ostial veins, passing over the auricle, then over the ventricle. The result is that the contraction of these veins at their opening into the heart prevents the blood escaping back into the veins during the auricular systole.

But there is every reason to believe that with distension of the veins and the right heart this closure is readily rendered incomplete. Thus Chauveau and Faivre<sup>44</sup> in experiments on the horse have observed that while a slight reflux occurs naturally during the auricular systole, it is much increased when the respiration is embarrassed. Numerous other observers have demonstrated the same fact. I have frequently failed to obtain tracings of the jugular pulse at the beginning of an examination of the patient, but when the patient's breath has been held the jugular pulse would often appear, sometimes indeed becoming very large. In the great engorgement consequent on mitral disease, the veins become greatly distended, and the ostial veins, like the auricle, are presumably incapable of contraction because of over distension.

§ 144. *Incompetence of the tricuspid valves.*—When dilatation of the right ventricle occurs the tricuspid valves no longer completely close the auriculo-ventricular orifice. So readily does



this occur that the older physicians were wont to speak of the "safety valve function" of the tricuspid valves. While experimentally this has been frequently demonstrated, one constantly finds clinical evidence of the ready occurrence of tricuspid incompetence in the study of the venous pulse. The conditions giving rise to this dilatation will be dealt with later; suffice it here to state that a visible pulsation in the veins of the neck is only possible when the right heart no longer effectively forwards the blood through the lungs. The contraction of the auricle and of the ventricle sends waves of blood back into the veins, and it is only when these waves are of sufficient strength to reach the jugular and more superficial veins that we can detect them.

§ 145. *Incompetence of the jugular valves.*—The movements communicated by the heart to the blood in the veins are usually best observed in the internal jugular veins. The direct communication of the right internal jugular through the right innominate vein and superior vena cava in about a straight line renders it easily susceptible to the movements from the right heart. Its relatively superficial situation renders it also readily accessible for observation. At a distance varying from a half inch to two inches above the junction of the jugular veins with the subclavian, a couple of valves are situated. These valves in the majority of people are readily rendered incompetent when there is distension of the veins. In such cases the pulsation is seen reaching high up in the neck.

§ 146. *Competence of the jugular valves.*—On the other hand, we occasionally meet with a patient in whom these valves, as well as two similar valves in the subclavian, are competent. When in such a case there is much regurgitation from the heart, the innominate vein at the junction of the subclavian and jugular veins—the "jugular bulb"—may be distended into a round ball, whose pulsations are visible at the distance of some yards, and the patient is sensible of a "beating in the neck" due to these pulsations.

§ 147. *Sounds produced by the stretching of the valves in the veins.*—Moreover, these valves may be stretched so suddenly and with such force that a short sharp sound is produced. Thus I have heard over the bulb three sounds during a cardiac revolution. In addition to the first and second sounds of the heart there was one limited to the bulb, preceding the first sound and due to a hypertrophied auricle sending back a wave of blood that stretched

these valves. In this case the hypertrophied auricle was due to tricuspid stenosis. In other cases where the auricle is paralysed, these sounds are due to waves of blood sent back by the ventricle. But not only can these sounds be demonstrated over the jugular vein, but also over the subclavian and femoral veins. Thus in some cases, while the sounds of the heart may be heard but faintly, when one places the stethoscope very lightly immediately under the middle of the clavicle on both sides or above the clavicle at its inner end, one can hear a sound loud and sharp. The area over which it is heard is very limited. On listening over the femoral vein in the groin the same sounds can be heard. In such cases there is always strong pulsation in the veins and liver. At *post-mortem* examinations I have dissected out these veins and found two large valves in each vein (jugular, subclavian, and femoral), immediately under the place where the sounds were heard.

§ 148. *Inspection of the jugular pulse.*—In examining a patient for pulsation in the jugular vein it is best that he should be laid down. In some rare cases, where the veins are greatly distended, the pulsation can only be recognised when the patient sits up. As the pulsation is most commonly limited to the internal jugular veins, and as these veins are never visible, being covered at the root of the neck not only by the skin and sterno-mastoid muscle, but by a variable quantity of adipose tissue, and as they are situated by the side of the carotids, one recognises the venous pulse by the character of the movement communicated to the structures covering the vein. In that form of the venous pulse where the principal wave is due to the auricular systole, the sudden collapse of the tissues covering the vein is more striking than the protrusion. If one further carefully times this collapse it will be found to be synchronous with the arterial pulse. The pulse in the internal jugular vein is often mistaken by most experienced observers for “beating of the carotids.” The carotid pulse is always abrupt and sudden in its protrusion of the covering tissues, and gradual in the shrinking. Furthermore, whenever one finds a small radial pulse and a large pulsation in the neck, one may safely conclude that the neck pulsation cannot be carotid, unless under very exceptional circumstances (as aneurysm). When the pulsation is in the more superficial veins, as the external, jugular, and facial, or superficial thoracic veins, the collapse of

the vein synchronous with the carotid pulse is usually easy of recognition. In another form of venous pulse, where the pulsation is due to the ventricular systole, the engorgement of the veins is usually so great, the arterial pulse so small, and the cardiac mischief so evident, that the recognition of the venous pulse is comparatively easy.



## CHAPTER XVII

### CONSTITUTION OF THE VENOUS AND LIVER PULSES

- § 149. The recognition of the events in a venous pulse.
- 150. Description of the events in a cardiac cycle.
- 151. The arterial pulse as a standard.
- 152. The venous pulse represents the auricular pressure.
- 153. The cause of the variations in the auricular pressure.
- 154. The cause of the venous pulse.
- 155. Illustration of the changes that take place in a venous pulse.
- 156. The liver pulse when established more constant than the jugular.
- 157. Individual cases illustrating changes in the venous and liver pulses.
- 158. Division of the venous and liver pulses into two groups (auricular and ventricular).

§ 149. *The recognition of the events in a venous pulse.*—The movements of the venous pulse are usually more numerous than the movements of the arterial pulse. In tracings obtained from the veins, a number of waves are present. As each of these indicates a rise of pressure in the veins, it can only be properly appreciated when the force producing this rise of pressure is known. In order to find out what forces can produce these waves, their times of appearance in the cardiac cycle must be established. This is done by taking tracings of the venous pulse, at the same time as some movement whose position in the cardiac cycle is definite. For this purpose the arterial pulse, carotid or radial, is the most reliable. The apex beat is often useful and convenient, but care is necessary in the employment of the apex beat, as has been already pointed out (§ 31).

§ 150. *Description of the events in a cardiac cycle.* In the following table (Fig. 176) there is diagrammatically represented a series of movements due to various forces that occur during one cardiac cycle. If a wave be found in the vein, and if its time of occurrence be ascertained by referring to the place it would

occupy in this table, we can usually find its cause by noting what force is operative at that particular period. While this table represents with fair accuracy the chief events in a cardiac revolution, it is not asserted that it is correct in every detail. Authorities are not quite agreed on several small points, but it is sufficient for the purpose I have in view.

What we have here presented are, the curves representing

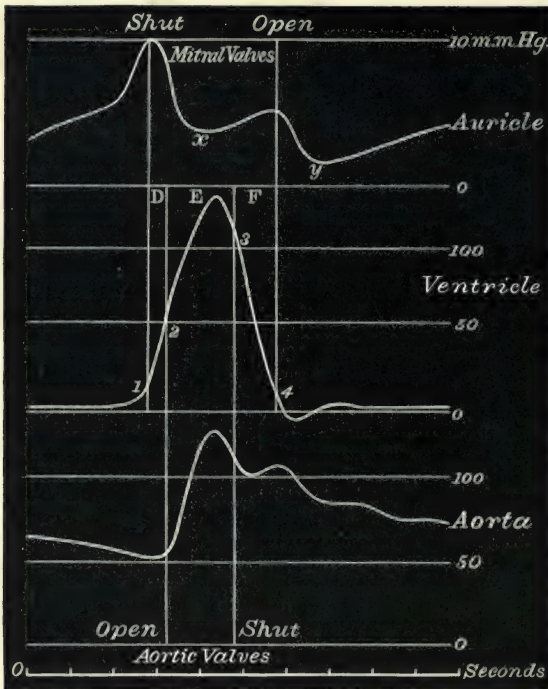


FIG. 176.—Semi-diagrammatic representation of the auricular, ventricular, and aortic pressures during one cardiac revolution. D, the presphygmic period of the ventricular systole; E, the sphygmic or pulse period; F, the postsphygmic period.

the variations of (1) the pressure within the auricle; (2) the pressure within the ventricle; (3) the pressure within the aorta. The spaces embraced by the perpendicular lines represent respectively the time during which the semilunar valves are open (E) and the auriculo-ventricular valves are shut (1-4). I would again direct attention to the presphygmic period, D, when the ventricular pressure is rising, but has not yet opened the aortic valves; and to the postsphygmic period, F, where the ventricular pressure is falling after the closure of the aortic valves. The

curves indicating the pressure are approximately correct, but are here utilised to show the periods when variations take place in the pressure. Though the events in this diagram represent what happens in the left side of the heart, there can be no doubt those on the right side are of the same character.

§ 151. *The arterial pulse as a standard.*—In the tracings of the venous pulse to be given hereafter, usually the carotid or

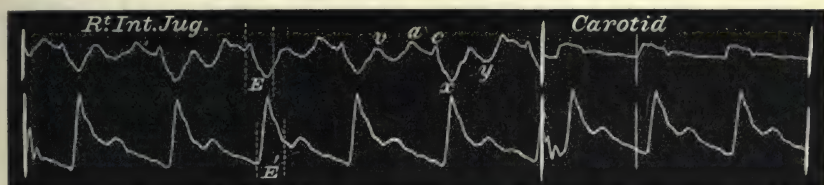


FIG. 177.—Simultaneous tracings of the jugular and radial pulses, and of the carotid and radial pulses.

radial pulse is taken as the standard of time. The curves of these pulses are later in time than that of the aortic pressure in the diagram. But as the carotid artery and jugular vein are equally distant from the heart, the pulsations in these vessels will bear the same relation as the auricular and aortic pressures do to one another in the diagram. The radial will be a little later than the carotid and jugular pulses, and consequently I




FIG. 178.—Simultaneous tracings of the jugular and radial, and carotid and radial pulses. *E* and *E'*, duration of ventricular outflow, right and left, through arterial orifices; *a*, auricular wave; *v*, ventricular wave; *c*, carotid wave; *x*, auricular depression; *y*, ventricular depression. The dotted lines between *a* and *x* indicate probably the true venous pulse wave.

frequently give the tracing of a few beats of the carotid artery after that of the jugular vein, in order to show the exact relationship (Fig. 177). The significance of the space *E* in the various tracings has already been described (§ 21). In many instances the tracings of the jugular pulse cannot be taken without the shock of the carotid pulse making a wave on the tracing, and as its presence is usually easily recognised, it serves as a standard of time to reckon the period of other events in the cardiac cycle.



Thus, as will be shown later, the wave *c* in Fig. 178 is due to the carotid artery, and the true venous curve follows the dotted line, cutting off *c*.

§ 152. *The venous pulse represents the auricular pressure.*—In cases where there is pulsation in the veins there is a free communication between the veins and the auricle; thus variations of pressure within the auricle are registered as waves or variations of pressure within the veins. Hence tracings of the venous pulse are but diagrammatic representations of the variations of pressure within the auricle. If we want to find out what is the cause of the venous pulse, we have but to search for the cause of the variations of the auricular pressure.

§ 153. *The cause of the variations in the auricular pressure.*—In the diagram (Fig. 176) there are two rises in the auricular pressure curve—a large and a small one, with of course two falls. The first rise in pressure immediately precedes the rise in ventricular pressure. It can only be due to the systole of the auricle. Immediately after the auricle ceases to contract there is a great fall (*x*) in the pressure due to the diastole of the auricle. The auriculo-ventricular valves being closed, and the blood pouring into the auricles from the veins, the pressure gradually rises, producing the second small wave in the curve. This wave is terminated by the opening of the auriculo-ventricular valves at the beginning of the ventricular diastole. It should be noted that the auricular pressure continues to rise after the closure of the aortic valves, during the postsphygmic interval *F*. When the pressure becomes lower in the ventricles than in the auricles the valves open and the contained blood passes through, reducing the auricular pressure, and causing the second fall, *y*, in the diagram. After this the pressure slowly rises by the accumulation of blood in both chambers, until it is suddenly increased by the next auricular systole.

§ 154. *The cause of the venous pulse.*—Now the curve obtained by experimental measurements of the auricular pressure corresponds to the tracing got from the venous pulse, just as the curve of the ventricular pressure corresponds to the tracing of the arterial pulse during the period (*E*), when the aortic valves are open.

If we compare the auricular pressure in the diagram Fig. 176 with the tracing Fig. 179, we find in both a large wave, preceding the period *E*; a fall, *x*, during the period of auricular diastole; a

gradual rising, *v*, continuing after *E* until the auriculo-ventricular valves open; then a fall, *y*, interrupted by the next auricular systolic wave (*a*). The same features are present in Figs. 177 and 178, and in most tracings of this form of venous pulse. The wave (*v*), which corresponds to the smaller wave in the auricular pressure curve of the diagram, is of great importance. In explaining

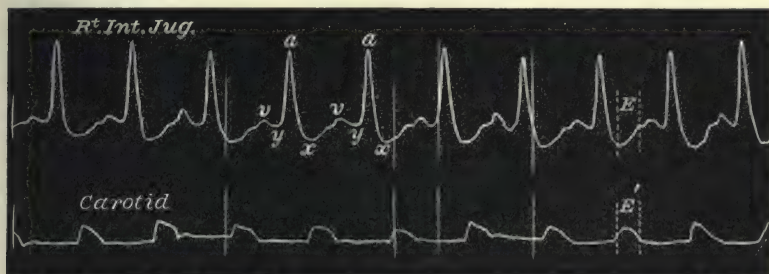


FIG. 179.—Simultaneous tracings of the jugular and carotid pulses, showing that the waves in the jugular correspond in time with the waves of increased auricular pressure in Fig. 176.

its causation in the diagram, I said it was due to an increase of pressure caused by the accumulation of the blood in the auricle flowing in from the veins. Presumably that is the cause of this rise in the auricular pressure in the normal heart. With engorgement of the right side the curve will be modified. Thus in cases of tricuspid incompetence the accumulation of blood



FIG. 180.—Simultaneous tracings of the radial and carotid, and of the radial and jugular pulses. The jugular pulse in this and the next tracing shows one large wave, *v*, due to the ventricular systole, and one large depression, *y*, due to the ventricular diastole.

in the auricle will more rapidly increase, because the flow backwards from the ventricle will be added to that from the veins. Hence the greater the tricuspid incompetence the sooner will the auricle be filled, and the earlier in the cardiac cycle will the wave (*v*) appear in the veins. As this wave, therefore, is an indication of the degree of tricuspid regurgitation, I have called it the ventricular wave. As the engorgement of the right side advances, this wave increases in size until it occupies

the whole period of ventricular contraction—a period corresponding to the period (*E*) in the diagram, as in Figs. 180 and 181. In both tracings there is but one large wave, *v*, synchronous with and due to the ventricular systole; and one large depression, *y*, synchronous with and due to the ventricular diastole. It will




FIG. 181.—Simultaneous tracings of the jugular and radial pulses.

be seen that there is not the slightest trace of a wave due to the auricle. As a matter of fact, the vigorous ventricle expelling the blood with such force through the wide tricuspid orifice had so enormously distended the auricle that its walls were stretched to such an extent that it was unable any longer to contract effectually upon its contents; it may in fact be said to be paralysed (see § 178).

§ 155. *Illustration of the changes that take place in a venous pulse.*—This increase in the size of the ventricular wave, with diminution and disappearance of the auricular wave, may be demonstrated by studying a series of cases with varying degrees of engorgement, or by watching in one patient the gradual alteration of the venous or liver pulse. In the early stages the auricle is active and able to contract. If it be able to contract and expel blood from its cavity, it must of necessity be able to expand and receive blood during its diastole. When, therefore, tricuspid regurgitation is present with an active auricle, the whole wave sent back by the ventricle does not reach the vein, because the cavity of the dilating auricle is interposed between the ventricle and vein. Hence, although the ventricle is pouring blood through the tricuspid orifice, it can only appear in the vein after the auricle has filled. With increasing engorgement the auricular systole is less effective, so that the auricle is not completely emptied; consequently the wave in the veins due to the regurgitation from the ventricle appears earlier.



It also gradually increases in size, encroaching more upon the period occupied by the auricular diastole. This increase in size of the ventricular wave is semi-diagrammatically represented in Fig. 182. Here it will be observed that as the auricular wave, *a*, diminishes in size, the period occupied by the ventricular wave, *v*, increases at the expense of the auricular diastole. The space (*E*) represents, as in Fig. 176, the period in the cardiac cycle when the semilunar valves are open—the sphygmic or pulse period of the ventricular systole. The ventricular wave at I appears at the end of this period. It gradually increases in size till it occupies the whole period (*E*) at V and VI. These tracings are not copied from one case, but are from actual tracings from a series of patients who showed an increasing degree of engorgement of the right heart.

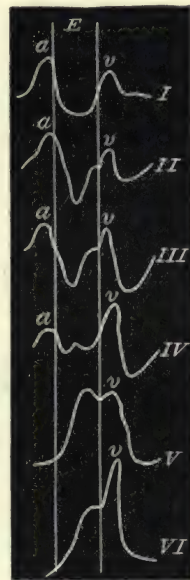


FIG. 182. — Semi-diagrammatic representation of the transition of the venous pulse from the auricular type into the ventricular. The space *E* represents the duration of the ventricular outflow through the pulmonary orifice, and the lines enclosing it therefore represent the time of opening and of shutting of the pulmonary valves. Coincident with the growth of the ventricular wave *v*, there is a diminution and ultimate disappearance of the auricular wave *a*.

§ 156. *The liver pulse when established more constant than the jugular.*—So far I have only referred to the pulse in the jugular veins. In certain cases waves of blood are sent back into the inferior vena cava, and these waves distend the liver, and give rise to a pulsatile swelling of the organ. When there is both a venous and a liver pulse present they are always of the same character, and one can demonstrate the changes that take place by the liver pulse as well as by the venous pulse. I select the liver pulse to show the gradual increase of the wave due to the ventricle, because the liver pulse when once established is a more constant phenomenon. It often happens with slight improvement in the heart's condition that the venous pulse disappears. In most cases that present a liver pulse or a pulse in the veins due to the ventricle alone, the patients suffer from great cardiac dilatation secondary to disease of the mitral valves. In these patients changes in the venous pressure are frequently taking place, so that the significance of the changes that occur

in the waves of blood thrown back into the veins is more difficult to follow in the jugular pulse than in the liver pulse. In developing this argument I therefore take the waves of blood thrown back into the inferior vena cava, which produce a liver pulse.

§ 157. *Individual cases illustrating changes in the venous and liver pulses.*—The patient on whom the following observations were made had been under my care since 1880. She suffered from mitral stenosis at that time. She had had rheumatic fever in childhood. Between 1880 and 1892 I attended her for three attacks of rheumatic fever. The following are notes of the case taken in September 1892. Female, aged forty-one. Complains of weakness and shortness of breath.

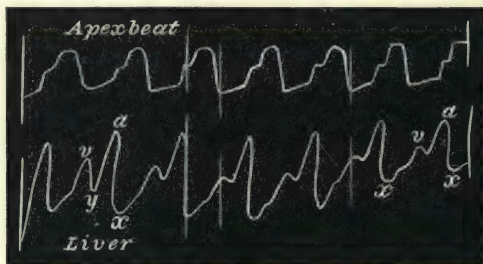


FIG. 183.—Simultaneous tracings of the apex beat and of the liver pulse. The wave, *a*, is due to the auricular systole; the wave, *v*, to the ventricular systole; the depression, *x*, is due to the auricular diastole; and the depression, *y*, to the ventricular diastole. This and the following three tracings were taken from the same patient, and show the gradual disappearance of the auricular wave: 1892.

There is marked heaving of the chest and a well-marked apex beat in the fifth interspace, with a distinct purring tremor preceding the beat. The vertical dulness of the heart begins at the second interspace, and the transverse dulness extends from one inch to the right of the middle line outwards to the left for five inches. There is a long murmur running up to and ending abruptly in the first sound, heard only at the apex. There is a soft murmur following the first sound heard at the apex and propagated towards the axilla. There is also a systolic murmur heard over the middle of the sternum, and also a faint diastolic murmur. The liver extends two inches below the margin of the ribs, and distinctly pulsates (Fig. 183). The diagnosis given then was stenosis and regurgitation at both mitral and aortic orifices, and tricuspid regurgitation. By and by I came to the conclusion that there was also tricuspid stenosis, for reasons to be

given later. If the liver tracing (Fig. 183) be examined it will be found that the liver pulse consists of two waves whose period in the cardiac cycle corresponds to the waves of auricular pressure in the diagram Fig. 176. The shortening of the period after the wave *v* always occurs in increased rapidity of heart action, as will be shown later. But the point here is to note the relative sizes of the two waves, the one due to the auricle being so much larger than the one due to the ventricle. At this period I had not devised the clinical polygraph. After I had devised it, most of my observations were made with it, and therefore the radial pulse was the standard by which the waves in the liver were recognised. Thus in Fig. 184 the liver and radial pulses are

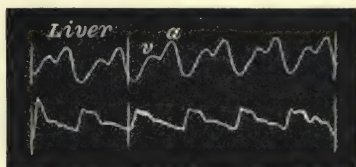


FIG. 184.—Simultaneous tracings of the liver and radial pulses : 1893.

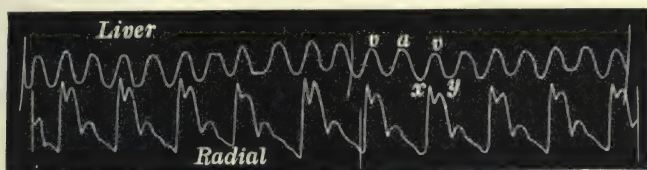


FIG. 185.—Simultaneous tracings of the liver and radial pulses : 1897.

taken together, and, as in Fig. 183, the auricular wave (*a*) is the larger of the two. Until her death in January 1899, this patient had many temporary attacks of extreme heart failure. In the later years of life a modification of the liver pulse became evident. Thus in February 1897 the tracing of the liver pulse in Fig. 185 was taken. It will now be seen that both waves are about equal in height, and the period of diastole following the auricular wave is not so marked as in Figs. 183 and 184. During the latter part of 1898 her weakness and breathlessness increased. When I examined her on December 1898 I found certain changes whose significance at the time I did not appreciate. I made a note as follows : The pulse is irregular, the heart dulness extends over to the right one inch beyond the midsternal line, and six inches to the left. The apex beat is in the seventh interspace. There is a systolic murmur at the apex, a systolic and diastolic murmur at the base, and a systolic murmur at the carotid. The liver is enlarged, extending three inches below the margins of the ribs, and distinctly pulsates (Fig. 186).



There is here no mention of a presystolic murmur. On looking over my notes of this patient, extending over many years, this is the first time a presystolic murmur was not mentioned. What is the explanation? The liver pulse supplies it. There is now no sign of the wave due to the auricle. There is but one large wave due to and synchronous with the ventricular systole. In fact, the auricle is distended to such an extent that the walls are no longer able to contract. While this patient lived, I took numerous tracings, and they all presented the same features—only one wave due to the ventricle. She died in 1899, and at the *post-mortem* examination the auricles were enormously distended into thin-walled sacs with a few strands of muscular fibres scattered over them. There are several points of interest in this

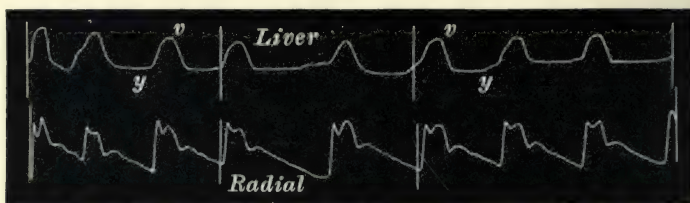


FIG. 186.—Simultaneous tracings of the liver and radial pulses. The liver pulse is now single waved, the auricular wave having disappeared: 1898.

case to which attention will be directed later, but here I desire to point out that with advancing engorgement of the heart, the liver pulse had changed in so far that what was in the earlier stages the most prominent feature—namely, the wave due to the auricle—had in the later stages entirely disappeared, and left a single waved liver pulse due to the ventricular systole.

That this is not an exceptional instance the following two cases demonstrate. The

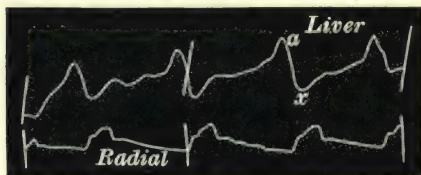


FIG. 187.—Simultaneous tracings of the liver and radial pulses. The main wave, *a*, in the liver pulse is due to the auricle: 1894.

first patient, a female, was under my care for heart failure consequent on mitral disease for a short time in 1894. There was marked pulsation of the liver (Fig. 187). Here there is a large wave, which from the time

of its occurrence is certainly due to the auricle. I did not see her again till 1899. In the meantime she had several attacks of extreme heart failure, and she was very ill when I saw her in

consultation. The liver was large and pulsating, and, as Fig. 188 shows, it was entirely due to the ventricle, there being no sign of

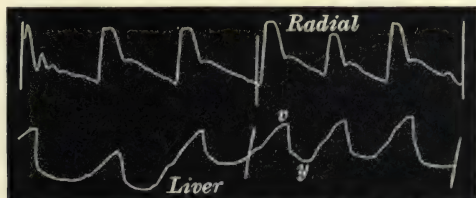


FIG. 188.—Simultaneous tracings of the liver and radial pulses. The main wave, *v*, is due to the ventricle. From the same patient as Fig. 187: 1899.

an auricular wave. The tracings show very distinctly that the liver wave now occurs with the radial pulse, not, as in Fig. 187, before it.

In another case the increase in the ventricular wave towards




FIG. 189.—Simultaneous tracings of the liver and radial pulses. This and the following four tracings are from the same patient.

the end of life is well seen. Fig. 189 shows a liver tracing with the two waves very distinct, the larger (*a*) being due to the auricle. Shortly before the patient died, the liver tracing showed a striking change (Fig. 190). Here the auricular wave, *a*, is much smaller than the ventricular, *v*. In this patient death occurred before the auricle had become completely paralysed.

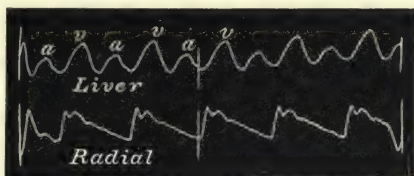


FIG. 190.—Simultaneous tracings of the liver and radial tracings. The auricular wave is the smaller here, in contrast to the preceding figures.

On account of the distressed breathing and abdominal distension, I was unable to get good tracings of the liver pulse. But in this patient the jugular pulse was always very distinct. Thus Fig. 191 shows the jugular pulse at the same time that the liver pulse in Fig. 189 was taken. The points to note here are the large size of the auricular wave, *a*, the following depression

due to the auricular diastole, and the small size of the ventricular wave, *v*. Shortly before she died, I took the tracing Fig. 192. The auricle is not completely paralysed, as there is a small wave,




FIG. 191.—Simultaneous tracings of the jugular and radial and of the carotid and radial pulses.

*a*, and its small size conveys an idea of the slight effect of the auricular systole; the systole being weak, so little blood has been expelled, that naturally only a slight fall will occur due to the auricular diastole. On the other hand, the ventricular wave, *v*, is

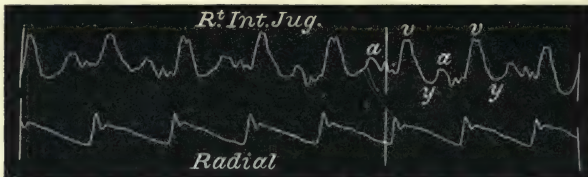


FIG. 192.—Shows the great diminution of the auricular wave as compared with the preceding tracing.

much increased in size, being now the most prominent feature in the venous pulse. The day before the patient died I got the tracing Fig. 193. Here the auricle is evidently nearly paralysed. There is an absence or the merest trace of the wave due to the

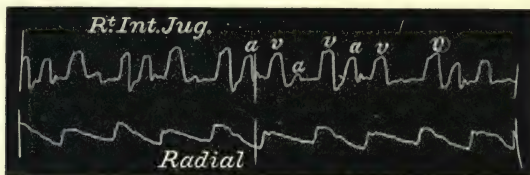


FIG. 193.—Shows the partial paralysis of the auricle from over-distension, the wave, *a*, being occasionally absent.

auricle at every second beat, and it is interesting to note that when the auricular wave is absent the succeeding ventricular wave is frequently increased in size. In this case also the auricles were found enormously distended after death.

§ 158. *Division of the venous and liver pulses into two*



*groups (auricular and ventricular).*—For the sake of convenience the pulsations in the veins may be divided into two classes—those in which the wave produced by the contraction of the auricle is a marked feature, and those in which the auricular contraction is no longer represented, only the wave produced by the ventricular contraction being present. The former will hereafter be spoken of as the “auricular venous pulse,” and the latter as the “ventricular venous pulse.” There is no sharp line dividing them, and while the auricular wave may disappear from the venous pulse, the ventricular wave is nearly always present, even in the more characteristic auricular venous pulsations. By the growth of this ventricular wave the one form becomes transformed into the other, and within certain limits the ventricular represents thereby a more advanced stage of engorgement than the auricular. Speaking generally, these two forms are those that have hitherto gone under the names of the normal, negative or false venous pulse (auricular), and the true or pathological venous pulse (ventricular). The changing of medical terms is at all times to be deprecated, and when undertaken there should be some very cogent reasons for so doing. In the present case the names applied to the venous pulses carried with them ideas at total variance with the actual facts. The one is as true a pulse as the other; both are often equally abnormal. The names I give them predicate nothing as regards their relative importance, and merely refer to their most characteristic features and their causes. It would be better to do without any distinctive naming were it not for the fact that the names I suggest are of great convenience, especially as regards the matter of brevity, in referring to certain salient points in the discussion of this subject.

## CHAPTER XVIII

### CONDITIONS GIVING RISE TO THE VARIOUS FORMS OF THE VENOUS AND LIVER PULSES

159. The auricle remains active in the majority of cases.
160. A powerful right ventricle with tricuspid incompetence necessary to paralyse the auricle.
161. In muscle failure the auricle remains active.
162. The liver pulse is absent in cases of muscle failure.
163. The liver pulse of the auricular type implies hypertrophy of the right auricle.
164. The effect of tricuspid stenosis on the right auricle.
165. Possible auricular hypertrophy in the absence of tricuspid stenosis.

§ 159. *The auricle remains active in the majority of cases.*—I have used the liver pulse to demonstrate how the auricular form of pulse may pass into the ventricular form. As will be seen, the jugular pulse agrees in its main features with the liver pulse. But it must not be supposed that the jugular pulse always passes into the ventricular form even in patients who die from heart failure. The vast majority of cases that exhibit the auricular form of pulse never exhibit any tendency to change of form. The reason for this is to be sought in the conditions giving rise to the heart failure. As a matter of experience, with rare exceptions we find the ventricular venous or liver pulse only in patients who have suffered from heart failure in consequence of disease of the mitral valves. Invariably the heart failure has lasted for a considerable time. On the other hand, where there is no valvular disease, but weakening or degeneration of the muscular wall (*i.e.* muscle failure) of the heart, we find the auricle always active, and at times the pulse in the veins due to the auricle becomes very large. What is the explanation of these facts?

§ 160. *A powerful right ventricle with tricuspid incompetence*

*necessary to paralyse the auricle.*—The following explanation I think is the most satisfactory. In mitral valvular disease (producing stenosis or incompetence or both) the muscle being healthy usually hypertrophies because its work is increased. The backward pressure of the blood when it reaches the right heart may increase the strength of the right ventricle. With the tricuspid orifice rendered widely incompetent during the ventricular systole, the back rush of blood will be such as to distend the auricle with a force against which it is incapable of contending. Even if we do not find hypertrophy of the right ventricle, still the power of the ventricle exercised upon the lax walls of the auricle does forcibly distend them. At death we always find the auricle enormously distended, and its walls much thinned in all patients who have during life exhibited a jugular or liver pulse of the ventricular type.

§ 161. *In muscle failure the auricle remains active.*—In cases of functional dilatation of the heart, due to a weakness of the wall, such as occurs in the various anæmias, the ventricular muscle is also weakened, and so does not exert the same force upon the auricle. Besides, the tricuspid orifice is rarely so wide in these cases, nor is the auricle ever so distended. Likewise, when the muscle wall is degenerated (fatty or fibrous) the ventricle is most affected, and its power being weakened, it cannot so deleteriously affect the auricle. Hence in all these cases where there is a venous pulse present, it is always of the auricular form, and the wave due to the auricle may be very large (see Chapter XXII.).

§ 162. *The liver pulse is absent in cases of muscle failure.*—In these cases, where the venous pulse is due primarily to muscle failure and not to valvular disease, there is never a liver pulse. The reason seems to be that to produce a liver pulse a much greater force is necessary to distend the liver than to distend the vein. That the powerful right ventricle sending waves back through a widely patent tricuspid orifice should cause a liver pulse is easy to understand. That the weak-walled auricle has not sufficient strength is evidenced by the fact that even when the wave in the vein is of great size, no movement whatever can be detected in the liver.

§ 163. *The liver pulse of the auricular type implies hypertrophy of the right auricle.*—When, therefore, we find a liver pulse with a marked wave due to the auricle, we can confidently



predict that the auricle must have become hypertrophied. In order to produce hypertrophy in the auricle, two things are necessary,—a healthy muscular wall and some resistance offered to the work of the auricle. Both these are present in tricuspid stenosis. For this reason I have assumed that a liver pulse of the auricular form is probably diagnostic of tricuspid stenosis.

§ 164. *The effect of tricuspid stenosis on the right auricle.*—The adherent cusps of the tricuspid not only offer an obstacle to the work of the auricle, and thus induce a hypertrophy of the auricular wall, but they serve as a curtain protecting the auricle from the distending force of the ventricle. It may be that the stenosis of the tricuspid in this manner prolongs the life of the patient, by limiting the extent of the regurgitation. At all events all my patients have lived many years after a liver pulse of the auricular form has appeared. But even in spite of the protecting curtain, the distension of the auricle in some cases becomes so great that it finally loses its power of contraction as illustrated by the tracings Figs. 183-186. In others it remains active to the end, although the relative size of the waves is reversed.

§ 165. *Possible auricular hypertrophy in the absence of tricuspid stenosis.*—It is possible that the auricle in the early stages of tricuspid incompetence consequent on mitral disease may increase in strength before it yields to the distension. In such cases there may be present a liver pulse of the auricular form. From my notes I find I have had over twenty cases of auricular pulsation of the liver. Considering the rarity of tricuspid stenosis, it is scarcely to be expected that I should have come across such a number. In a few I have found the auricular change into the ventricular form, and it is possible that in the earlier stages of failing compensation secondary to mitral disease a liver pulse of the auricular type may be present. But in the patients from whom I have had tracings showing an auricular liver pulse, and on whom I have made a *post-mortem* examination (seven in all), there has been stenosis of the tricuspid orifice.

## CHAPTER XIX

### THE AURICULAR FORM OF THE VENOUS PULSE

- § 166. The auricular venous pulse differs from the auricular liver pulse.
- 167. The effect of the carotid pulse on tracings of the jugular pulse.
- 168. The carotid wave in tracings by other observers.
- 169. The period of stasis in the venous pulse.
- 170. Changes due to variations in the rate of the heart's action.
- 171. Timing with the arterial pulse necessary for the certain recognition of the nature of the venous pulse.
- 172. Variations in the size of the auricular wave.
- 173. Significance of the auricular and ventricular diastolic depressions.
- 174. Prolongation of the ventricular wave after closure of the semilunar valves.
- 175. The notch on the ventricular wave not due to instrumental defect.
- 176. The cause of the increase in the ventricular wave after the closure of the semilunar valves.

§ 166. *The auricular venous pulse differs from the auricular liver pulse.*—In the foregoing description the auricular liver pulse is characterised by two distinct waves, one due to the auricular systole, and the other to the ventricular systole after it has filled the auricle. The same features are recognised in the pulsation of the jugular veins. The pulse in the veins is met with in a large number of people in whom there is no liver pulse, and there are other elements introduced which give a greater variety to the character of the tracings of this pulse.

§ 167. *The effect of the carotid pulse on tracings of the jugular pulse.*—The most noteworthy of the differences between the tracings of the jugular and liver pulses is the effect of the carotid impact upon the tracing. When the tracing is got from the internal jugular vein it is often impossible to obtain it without the effect of the carotid impulse being manifested. The receiver placed over the vein receives the shock communicated by the carotid pulse, and it appears in the tracing sometimes as a sharp wave, and sometimes as a mere interruption in the line of descent. It is not a wave

in the vein, but is due to the carotid pulse affecting the instrument. The facts which prove it to be purely carotid are as follows: (1) It is always synchronous with the carotid pulse (Figs. 194 and 195). (2) In moving the receiver away from the




FIG. 194.—Simultaneous tracings of the carotid pulse and of the jugular pulse, showing exact synchronism of the carotid pulse with the carotid wave (c) in the jugular pulse.

vein towards the artery, this wave assumes more and more the character of the arterial pulse, or when the venous element in the tracing diminishes the arterial element remains. Fig. 196 shows the venous pulse present during two respiratory movements, after which the breath is held.

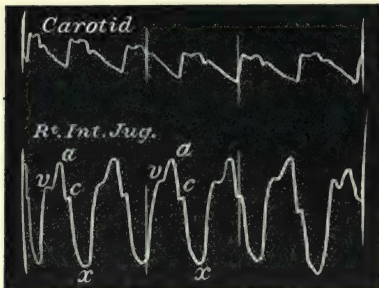


FIG. 195.—Shows the same as Fig. 194.

During inspiration the carotid pulse (C) alone is present; when the breath is held the venous pulse increases in size and the carotid wave becomes greatly reduced in size. (3) It is never present in the liver pulse when, otherwise, the liver pulse bears a distinct resemblance to the venous pulse in character and rhythm (Figs. 197 and 198).

(4) During irregular heart action, when there is an absence of the arterial pulse while the venous pulse continues, the carotid wave is absent from the venous tracing during this irregularity (Fig. 274).

When the jugular valves are competent, so that the jugular bulb is much distended, there is no carotid wave in the tracing (Fig. 179). Also, when the pulse in the jugular vein is very large and the carotid very small, this wave is usually absent (Fig. 207).






FIG. 196.—Simultaneous tracings of the jugular and carotid pulses, showing the disappearance of the jugular pulse during inspiration, and its increase when the breath is held. The wave, *c*, in the venous pulse is seen to become the carotid pulse, *C*, when the jugular pulse disappears during inspiration.




FIG. 197.—Simultaneous tracings of the jugular and liver pulses, showing absence of the carotid wave, *c*, from the liver pulse.

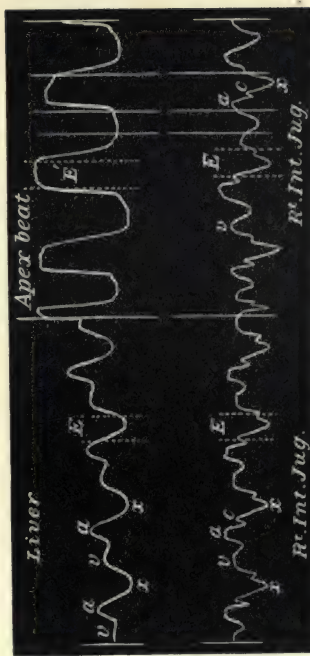


FIG. 198.—Simultaneous tracings of the liver and jugular pulses and of the apex beat and jugular pulses, showing the absence of the wave, *c*, from the liver pulse.

§ 168. *The carotid wave in tracings by other observers.*—The arterial or carotid wave is to be found in the tracings by several observers. In Friedreich's<sup>45</sup> tracings of the venous pulse from the normal heart it is frequently present, but as he misinterpreted the time of the events in these particular cases his explanation is distinctly erroneous. In Potain's<sup>46</sup> tracings it is likewise distinctly visible, and is accounted for by him as a wave in the vein produced by the ventricular contraction. But as has been pointed out, the appearance of such a wave from such a cause at this period is a physical impossibility (on account of the dilating auricle at this time receiving the regurgitant wave from the ventricle). In some of Riegel's tracings it is also very evident. But when it appears here it has rather a deceptive appearance. Later, I shall have to dwell upon the changes that take place in the character of the tracing during rapid action of the heart, and it may for the present suffice to say that frequently only two waves appear, one produced by the auricle separated by a slight depression from that produced by the carotid arterial wave, as in Figs. 205 and 206. Curves somewhat similar to these are given by Riegel,<sup>47</sup> and I am more than suspicious that the tracings in his Figs. 8 and 9 are of a similar nature. I am all the more suspicious that this is the case since he attributes the latter of the two waves in his Fig. 8 to the closure of the tricuspid valve, and in his Fig. 9 the latter of the two waves to the auricle, its contraction being delayed on account of the low pressure. In numerous observations on similar curves I have established beyond the possibility of doubt the exact synchronism of this wave with that of the carotid pulse. In Mosso's<sup>48</sup> tracings this wave is to be detected, and he likewise points out its exact synchronism with the carotid pulse, but attributes it to the distension of the jugular vein prior to the suction exercised by the sudden diminution of the heart's size after expulsion of its contents. Pramberger<sup>49</sup> gives a tracing with this wave occurring during the auricular diastole; he considers that it is propagated from the aorta. The wave is to be recognised in a tracing given by Galabin,<sup>50</sup> but he does not attempt to account for its presence, and his interpretation of the whole tracing, in my opinion, is incorrect. In Gibson's<sup>51</sup> tracings the carotid wave is well marked, and he adopts my interpretation.

§ 169. *The period of stasis in the venous pulse.*—When the heart is acting slowly the veins during diastole may gradually

fill before the next auricular systole. In such instances after the ventricular wave (*v*), the tracing rises somewhat gradually. In the tracing (Fig. 199) it appears as a rise with a somewhat flattened top, interrupted by the sudden appearance of the auricular wave (*a*), and corresponds to the gradual rise in the

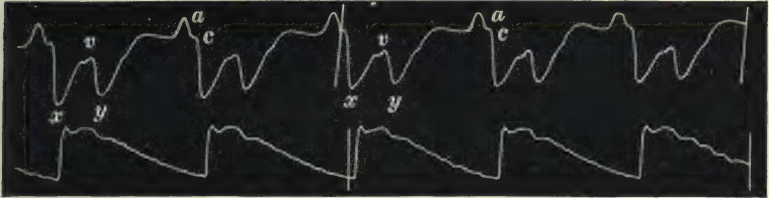


FIG. 199.—Simultaneous tracings of the jugular and radial pulses, showing how the interval, *y* to *a*, after the ventricular wave is occupied by a gradual rise due to stasis in the vein. Pulse rate 44 per minute.

auricular pressure curve after the depression *y* in Fig. 176. The rise I consider due to the distension of the vein by the blood flowing to the heart. It is the changes in the volume of the vein which the instrument records in the tracing, whether these be due to actual waves of blood sent into the veins or to stasis. The pulse rate in this case was forty-four per minute.

§ 170. *Changes due to variations in the rate of the heart's action.*—The quickening of the venous pulse occurs entirely at the expense of the auricular diastolic period of the cardiac revolution, just as the quickening of the arterial pulse takes

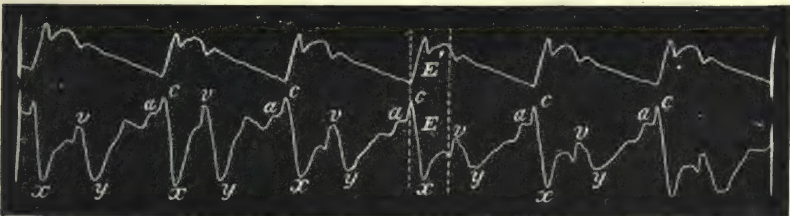


FIG. 200.—Simultaneous tracings of the jugular and radial pulses. Pulse rate 56. This and the following seven tracings show a gradual quickening of the pulse rate with a gradual disappearance of all the events during the auricular diastole.

place mainly at the expense of the ventricular diastolic period. The events occurring in the veins during the auricular diastolic period tend to disappear. Thus in Fig. 199 the auricular diastolic period is very long. When the pulse rate increases, as in Fig. 200 and 201, the shortening affects entirely the period



of stasis (*y* to *a*). This period of stasis (between *y* and *a*) is very short in the first part of Fig. 202. When the pulse rate is slightly accelerated on holding the breath it quite disappears.

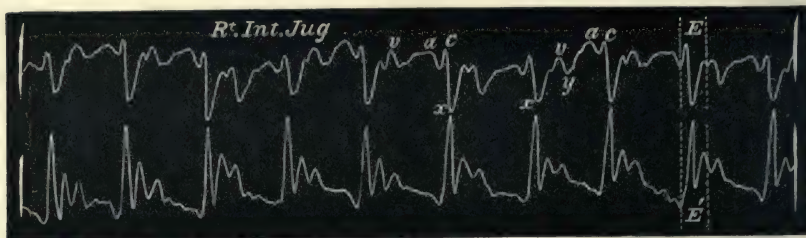


FIG. 201.—Simultaneous tracings of the jugular and radial pulses. Pulse rate 70.

With still greater increase of the pulse rate, the ventricular wave *v* becomes shortened even to such an extent that its rise is blended into that of the auricular wave, so that only one true

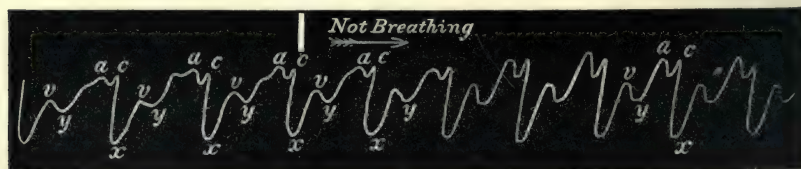


FIG. 202.—Tracing of the jugular pulse, showing shortening of the period of stasis (*y* to *a*) on holding the breath.

venous pulse wave is recognised. Thus in Fig 203 the ventricular wave, *v*, is represented by a mere interruption of the upstroke, as the auricular wave follows so close upon it, and

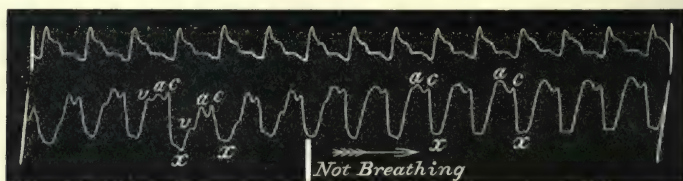


FIG. 203.—Simultaneous tracing of the radial and jugular pulse, showing disappearance of the ventricular wave, *v*, on holding the breath.

when the breath is held even this slight wave disappears. In the next two tracings the same result is shown when the pulse quickens on account of an increase in the temperature. In Fig. 204 the pulse rate is one hundred per minute, and the temperature  $100^{\circ}$ , and a tracing of the venous pulse shows it to be of

the auricular form, with the three waves—ventricular, auricular, and carotid. In the evening the temperature rose to 102°, and the pulse quickened to one hundred and twenty-six, and the

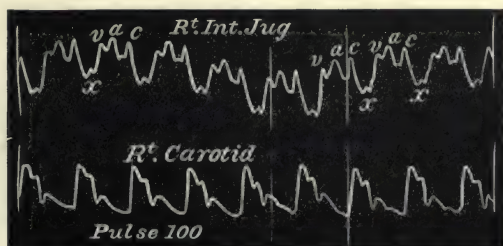


FIG. 204.—Simultaneous tracing of the jugular and carotid pulses. The period of stasis is absent, and the ventricular wave *v* is represented by a slight movement, T. 100, P. 100.

ventricular wave entirely disappeared, Fig. 205. In Fig. 206 the pulse was always quick, and the venous pulse always had this character, one large auricular wave, *a*, with a well marked

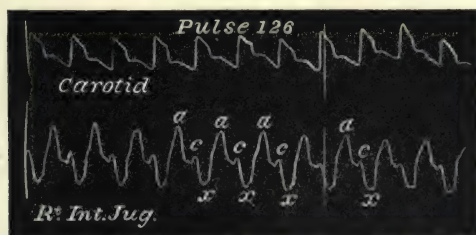


FIG. 205. From the same patient as Fig 204. Shows the disappearance of the wave *v*, when the pulse quickens, T. 102, P. 126.

carotid wave, *c*. The auricular venous pulse may even be single waved (Fig. 207). In these cases the ventricular outflow is followed rapidly by the contracting auricle. The time of the

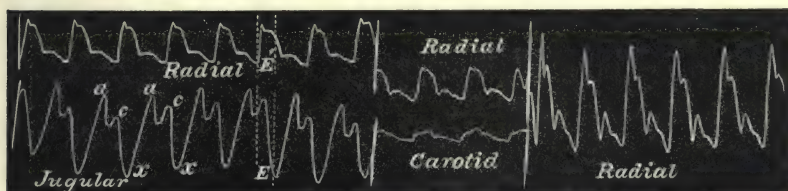


FIG. 206.—The jugular tracing shows only the wave due to the auricle and carotid artery.

wave in the cardiac cycle is seen to correspond to that of the auricular systole. The wave in the vein is large, and quite obscures the small carotid pulse, which fails to affect the tracing.

It is thus seen that with the venous pulse of the auricular type, increase in rate takes place entirely at the expense of the events that happen during the auricular diastolic period. The period of stasis first goes, then the period of ventricular diastole, then the wave due to the ventricular systole. Finally, as in Fig.

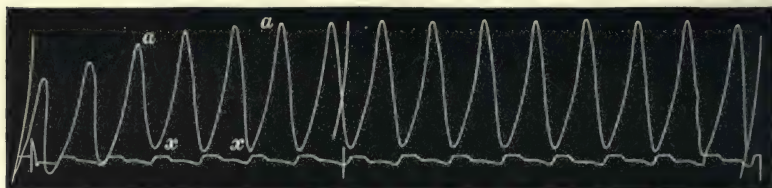


FIG. 207.—Simultaneous tracings of the jugular and radial pulses. There is but one large wave due to the auricular systole.

207, there is only one large wave, *a*, due to the auricular systole, and one large depression, *x*, due to the auricular diastole.

§ 171. *Timing with the arterial pulse necessary for the certain recognition of the nature of the venous pulse.*—These variations in the auricular venous pulse can only be distinguished when the arterial pulse is taken synchronously as a standard of time. Tracings of a similar shape are got with the ventricular venous pulse, and if one reasoned from the shape alone error would surely arise. Thus, for instance, Fig. 206 resembles Fig.

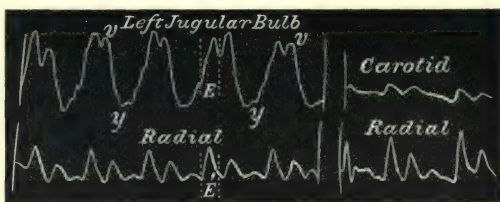


FIG. 208.—Simultaneous tracings of the jugular and radial pulses and of the carotid and radial pulses. The jugular pulse is of the ventricular type, but bears a resemblance to jugular pulses of the auricular type in Fig. 206. Timing with the radial shows at once the difference.

208, the latter being a ventricular tracing, the former showing the auricular and carotid waves. In tracings taken by other observers the similarity in form has led them to draw erroneous conclusions.

§ 172. *Variations in the size of the auricular wave.*—The actual size of the auricular wave shows remarkable variations. When the vein is full immediately before its occurrence, the wave itself may be small, as in Figs 199 and 200. On the other hand, it may be of great height and force, as in Figs. 179 and 207. No



satisfactory deductions can be drawn from this difference, although it may be put down as a general rule that when the auricular wave is large and stands out clear and distinct from the other elements, it is an evidence of a distended though powerful auricle.

§ 173. *Significance of auricular and ventricular diastolic depressions.*—The depressions I have marked  $x$  and  $y$  on the tracings are respectively synchronous— $x$  with the beginning of the auricular diastole, and  $y$  with the beginning of the ventricular diastole. When the pulse is slow, as in Figs. 199 and 200, both depressions are well marked. With the increase of the rate of the heart, the occurrence of the auricular systole cuts short the duration of the depression  $y$  in the manner already described, while in rapid pulses the depression  $y$  is no longer seen (Figs. 206 and 207). In all these tracings the period  $x$  is well marked. The reason for this is that while the auricular systole is effective it must contract freely, and in consequence its diastole must be very effective, and in its diastole it empties the jugular and other veins, thus giving rise to the great fall in the tracing. The depression due to the ventricular diastole is cut short, and finally disappears with increase of the rapidity of the heart's action, because the auricle in its diastole receives all the inflowing blood during the short ventricular diastole.

But if we consider those cases where the auricle becomes weakened and finally paralysed, we find a progressive shortening and final disappearance of the period  $x$ , due to the auricular diastole, for the simple reason, that the dilated auricle at each systole contracts only slightly, therefore it can only receive from the veins a small amount of blood. It is thus we see that a failing auricle not only produces a small wave but also a small depression.

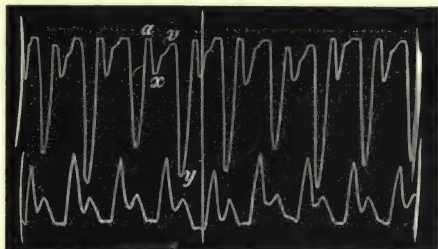


FIG. 209.—Simultaneous tracings of the jugular and radial pulses, showing the small auricular diastolic depression  $x$ , due to weakening of the engorged auricle.

In Fig. 209 the size of the depression  $x$  is in marked contrast to the size of the depression  $y$ . In the patient from whom this figure was taken there was found, *post-mortem*, enormous distension of right auricle, with

great dilatation of the mitral and tricuspid orifices. Here the auricle was evidently approaching paralysis when the patient died.

One may put it down as an axiom that when the ventricular diastolic depression  $y$  is more marked than the auricular diastolic depression  $x$ , there is great dilatation of the right heart and weakening of the power of the auricle. This is also well illustrated in the tracings showing the venous pulse when the auricle is recovering from paralysis (Figs. 212-217), and in acute dilatation of the heart (Fig. 246).

§ 174. *Prolongation of the ventricular wave after closure of the semilunar valves.*—There are certain characters in the ventricular wave that are worthy of note. Whenever it occurs it is found to be delayed longer in the cardiac cycle than the period of outflow from the ventricle through the arterial orifices ( $E$ )—that is to say, it continues during the postsphygmic intervals, like the auricular pressure in Fig. 176. This is evident when it occurs in its most rudimentary form in the auricular type of venous pulse, as well as when the ventricular wave constitutes the whole of the venous pulse. Thus in Fig. 179 the spaces  $E$  and  $E'$  represent the period occupied by the ventricular outflow in the tracings of the jugular and carotid pulses. In the carotid tracings the termination of the period  $E$  corresponds nearly with the aortic notch, which is recognised as the time of closure of the aortic valves. No more blood escapes from the ventricle into the artery, and the arterial pressure falls until it is temporarily checked by the cause of the dicrotic wave. In the tracing of the venous pulse, on the other hand, there is a distinct rise immediately after that period. In such tracings as Figs. 177 and 178 the ventricular wave is represented by the portion that occurs after the semilunar valves are closed. In many cases of the auricular venous pulse the ventricular wave is divided into two by the occurrence of a notch, the rise after the notch invariably occurring after the closure of the semilunar valves (Figs. 179, 191, 199, 200, 201, etc.).

§ 175. *The notch on the ventricular wave not due to instrumental defect.*—It might be assumed that the notch on the ventricular wave is due to instrumental defect. But that this is not so will be seen when it is considered how persistent this notch is at a definite period in the cardiac cycle under a

great variety of conditions. Thus in Fig. 200, where the ventricular wave varies much in size in accordance with the respiratory movement, the notch, though appearing at different heights, maintains its time in the cardiac cycle. I have also found it present in the tracings taken directly with a steel spring, and its presence can sometimes be detected in tracings taken by other methods.

§ 176. *The cause of the increase in the ventricular wave after the closure of the semilunar valves.*—The fact that the ventricular wave increases in size after the pulmonary valves have closed would indicate that some extra force is at work. This is strongly evident in some tracings, where a sudden rise

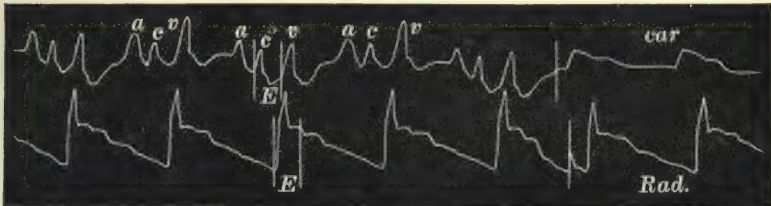


FIG. 210.—Simultaneous tracings of the jugular and radial pulses to show the sudden rise of the ventricular wave, *v*, during the postsphygmic period.

of considerable extent takes place. Thus in Figs. 210 and 272 the wave, *v*, is very abrupt, of considerable size, and almost entirely limited to the period after the ventricular outflow through the pulmonary orifice has ceased, *i.e.* to the postsphygmic period. To find out what force is operative here reference can be made to the diagram (Fig. 176). The only force operative after the period *E* is the still high (though falling) ventricular pressure. During the period after the semilunar valves close, the ventricular pressure, though no longer able to overcome the aortic pressure, is still high above the venous pressure, and therefore the ventricle pours its contents back into the auricle and venous system. During the ventricular systole the outflow in such cases is occurring in two directions, and with the sudden cessation of the onward current there is a sudden increase in the backward current. This period of high ventricular pressure is extremely brief, but the wave sent back at this time is also extremely brief and exactly corresponds in duration. Another argument in favour of this view is to be found in the greatly increased size of the wave during a premature beat



when the venous pulse is of the ventricular form. In Fig. 225 the fourth apex beat is of the nature of a premature systole, and the corresponding wave in the jugular bulb is higher, though of shorter duration. The reason for this is that during the premature systole of the ventricle little or no blood escaped into the pulmonary artery; hence the ventricular contraction, though weak, sent the whole of its contents into the veins.

Although I am not thoroughly convinced of this explanation, it is the only feasible one at which I have been able to arrive.

## CHAPTER XX

### PARALYSIS OF THE AURICLE AND THE VENTRICULAR FORM OF THE VENOUS PULSE

- § 177. Increase of the ventricular wave synchronous with diminution of the auricular wave.
178. Paralysis of the auricle.
179. A presystolic murmur is never present with a ventricular venous pulse.
180. Is the left auricle also paralysed ?
181. The appearance of the wave in the ventricular venous pulse earlier than that of the systolic wave in the arterial pulse.
182. The ventricular venous pulse represents the pressure variations within the right ventricle.
183. The period of stasis in the ventricular venous and liver pulses.
184. The postsphygmie portion is the most constant part of the ventricular wave.

§ 177. *Increase of the ventricular wave synchronous with diminution of the auricular wave.*—As has already been stated, the ventricular wave appears in an attenuated form in the auricular venous pulse. The whole of the wave sent back by the ventricle does not reach the veins, because the dilating auricle receives the first portion, and it is only when the auricle is filled that the ventricular wave appears. As the auricle becomes less and less efficient its systole becomes feebler, and in consequence its cavity is never properly emptied. The diastole of the auricle is also less efficient, and the ventricular wave increases in size, encroaching more upon the period occupied by the auricular diastole. This increase in the size of the ventricular wave is semi-diagrammatically represented in Fig. 182, and has already been described.

§ 178. *Paralysis of the auricle.*—This increase of the ventricular wave and diminution and disappearance of the auricular wave implies the paralysis of the auricle. The auricular appendage is usually described as being the last part of the heart to cease contracting,—the *ultimum moriens*,—so that the notion of a

patient continuing to live with an auricle incapable of contracting is a somewhat novel idea in cardiac symptomatology, and it seems necessary to devote a little study to the condition.

I have already demonstrated, in Figs. 183 to 186, how in one patient the steadily advancing failure of the heart was accompanied by the diminution in size and final disappearance of the auricular wave, with the increase in size and final persistence of the ventricular wave. At the *post-mortem* examination one could easily surmise that the greatly distended, thin-walled sac of an auricle was incapable of exercising any pressure on its contents. In quite a number of cases I have noted the same steady progress of events, and occasionally I have had the opportunity to watch the restoration of the auricle to temporary activity. All who are familiar with cases of heart failure con-

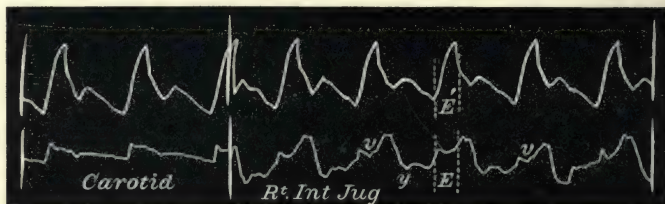


FIG. 211.—Simultaneous tracings of the carotid and radial and jugular and radial pulses during an attack of temporary heart failure. The jugular pulse is ventricular in form, the auricle being inactive.

sequent on mitral disease recognise periods of extreme failure when the heart's dulness increases. Sometimes it happens that a presystolic murmur that was present entirely disappears during the time of temporary failure, and returns with increased vigour of the heart. The explanation usually given for this is that the distended right side had pushed the left ventricle away from the chest wall, so that the sound was no longer capable of being heard, and as the recovery took place the return of the left ventricle to the front enabled the sound to be heard. I have another suggestion to offer—namely, that during this period of heart failure in some cases the auricle has become so enormously distended that it ceases to contract, but that with restoration of compensation it again regains its power of activity. In Fig. 211 there is a tracing taken from a patient suffering from extreme heart failure. It will be noted that there is no sign of an auricular wave, the venous pulse wave being synchronous with the arterial outflow from the ventricles (*E*). Gradually



this patient's strength improved, the area of cardiac dullness diminished, and the venous pulse then presented a distinct though relatively small wave, *a*, due to the contraction of the auricle



FIG. 212.—From the same patient as Fig. 211; the heart's strength has increased and there is now a small wave, *a*, due to the auricle.

(Fig. 212). The improvement continued, and the last tracing I took (Fig. 213) shows a still larger auricular wave. Figs. 214 and 215 show the same thing. This patient had symptoms of

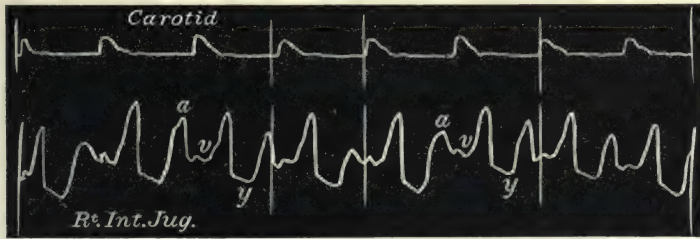


FIG. 213.—From the same patient as Figs. 211 and 212; with increased strength the auricular wave, *a*, has increased in size.

extreme heart failure, during which Fig. 214 was obtained. When he had much improved the tracing Fig. 215 was taken, which shows a well marked auricular wave. Here I have not

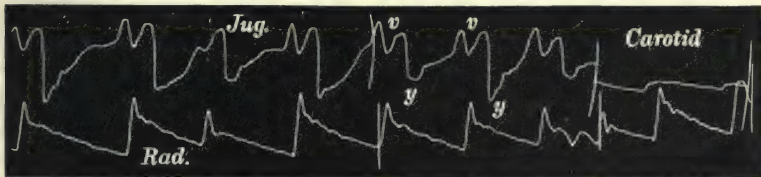


FIG. 214.—Simultaneous tracings of the jugular and radial and of the carotid and radial pulses, during an attack of temporary heart failure. The venous pulse is of the ventricular form, the auricle being inactive.

the slightest doubt there was a temporary paralysis of the auricle, and very likely with recurring attacks of heart failure the auricular wave would entirely disappear. In another patient,

whom I first saw in May 1892, there was a faint venous pulse of the auricular type (Fig. 216). After an attack of heart failure




FIG. 215.—From the same patient as Fig. 214, after recovery. There is now a large auricular wave, *a*, in the jugular pulse.

in July of that year the venous pulse was ventricular in form, with an occasional small beat due to the auricle, *a* (Fig. 217).




FIG. 216.—Simultaneous tracings of the carotid and jugular pulses, showing a small jugular pulse of the auricular form.

The following year this small wave had ceased to appear, and up to the time of her death in 1900 the venous pulse was invariably of the ventricular form only.

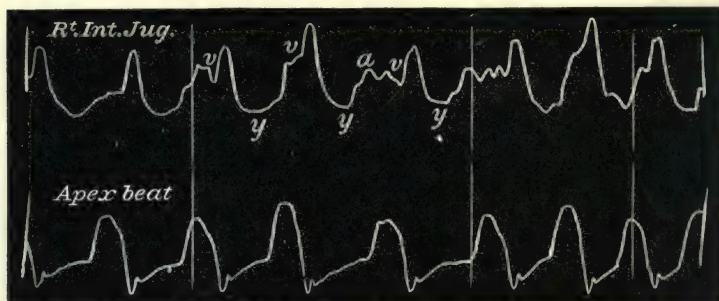


FIG. 217.—Simultaneous tracings of the jugular pulse and of the apex beat, from the same patient as Fig. 216, showing only the occasional appearance of the wave, *a*, due to the auricular systole, during an attack of heart failure.

§ 179. *A presystolic murmur is never present with a ventricular venous pulse.*—It is only lately that the true meaning of this solitary ventricular wave has been duly appreciated by me as

being a proof of the paralysis of the auricles. Hence my notes of the cases are not so full in regard to other symptoms as they ought to be. Yet in all these cases where there is only a ventricular venous pulse I have never heard a presystolic murmur. I have examined my notes carefully, and found no record of a presystolic murmur even when at the *post-mortem* examination well marked mitral stenosis was present. As I have already said, in describing Figs. 183-186 (§ 157), I made a note that for the first time there was an absence of the presystolic murmur. Another curious instance occurred where the recognition of the symptoms of auricular paralysis afforded a suitable explanation. It is often my custom after taking a tracing to indicate by a series of light scratches under the pulse tracing to indicate the period when a murmur is heard. Thus in 1894, in taking a tracing of the slow pulse in Fig. 218, I scratched the tracing




FIG. 218.—Simultaneous tracings of the apex beat and of the radial pulse from a case of mitral stenosis. The premature systole is well marked in the apex tracing and absent in the radial. The shading underneath shows the time of the murmurs.

indicating that there was a systolic murmur and a long murmur during the pause in the pulse. At this time I could offer no explanation. After death there was found marked mitral stenosis. The auricles were enormously distended. The venous pulse was purely of the ventricular type (Fig. 296). During the period that should have been occupied by the auricular systole there was neither pulse wave nor murmur. I put the tracing aside, trusting that future experience would supply the explanation. I had forgotten all about the tracing. In 1899 I came across an exactly similar case, and I made the same scratches, indicating the same observation (Fig. 219). In this case also the venous and liver pulses were of the ventricular form (Fig. 300). When examining critically my collections of tracings I came across first one then the other of these two tracings—the explanation then dawned upon me. First, there was no presystolic murmur, meaning thereby auricular systolic, even though there was marked mitral stenosis, because the auricle was



incapable of contracting. Second, the long diastolic murmur was evidently due to the onrush of blood from the dilated paralysed auricle through the mitral orifice during the ventricular diastole—the diastolic murmur that is occasionally present in




FIG. 219.—Simultaneous tracings of the apex beat and radial pulses, with murmurs as in Fig. 218.

cases of mitral stenosis. The diastolic murmur usually runs into the presystolic or auricular systolic murmur, the latter ending abruptly in the first sound. Here this latter murmur is absent.

§ 180. *Is the left auricle also paralysed?*—I have assumed here, when there is an absence of the auricular wave in the venous pulse, that both auricles are paralysed. On the one hand, the venous pulse gives evidence for the right auricle, while the presystolic murmur supplies the evidence of the activity of the left auricle, and the simultaneous disappearance of both suggests the paralysis of both. I have had another striking illustration of the tendency of both auricles to cease acting when one is paralysed. The patient from whom Fig. 179 was taken had the jugular bulb distended into a pulsating ball, whose movements could be seen at a distance of several yards. For the five years I had her under observation this pulsation was invariably present till a few days before her death. There was also present a loud presystolic murmur at the apex. Latterly I could also detect another presystolic murmur at the middle of the sternum. Some time before she died she had severe attacks of angina pectoris. One day she said to me that “the beating in her neck” had ceased. I examined her carefully and found that the jugular swelling had entirely disappeared, that the hitherto well marked liver pulse had disappeared, and there was no presystolic murmur present either at the apex or over the sternum. There was continuous irregularity of the heart’s action observed for the first time. For three days these observations were verified, when she suddenly died. There was found mitral and tricuspid stenosis, and the right auricular appendage was found tightly packed with

a firm, white, partly organised clot, the size of a large walnut. The formation of this clot had evidently paralysed the right auricle, as evidenced by the absence of the venous and liver pulsation, and of the tricuspid presystolic murmur, while the simultaneous disappearance of the very well marked presystolic murmur at the apex marked the cessation of the left auricular systole.

I know that these facts are too limited actually to prove that both auricles cease to act; nevertheless they are so striking in themselves that I throw out this suggestion as the only feasible explanation.

§ 181. *The appearance of the wave in the ventricular venous pulse earlier than that of the systolic wave in the arterial pulse.—*

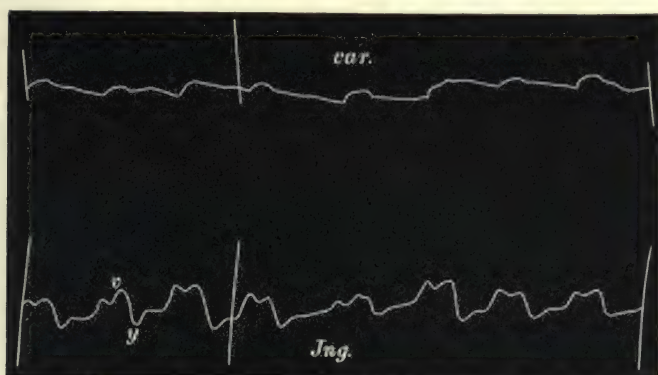


FIG. 220.—Simultaneous tracings of the carotid and jugular pulses. The jugular pulse is of the ventricular form, and shows the earlier appearance and longer duration of the jugular pulse than of the carotid.

Inasmuch as the wave in the ventricular venous pulse is due to the right ventricular systole, and the systolic wave in the carotid pulse is due to the left ventricular systole, it might be supposed that they would occupy the same time in a cardiac revolution. If, however, it be borne in mind that in the case of the arterial pulse the left ventricle has opposed to its systole the high pressure in the aorta, whereas the right ventricle has opposed to its systole the slighter pressure in the auricle, it will be realised that certain modifications must take place in the duration of their respective waves. It will be remembered that the ventricle cannot open the aortic valves until the pressure within the ventricle rises above that in the aorta. There is therefore a brief period, the presphygmic interval, after the beginning of the ventricular systole before the arterial pulse appears. The right

ventricle having little pressure in the auricle to overcome, the venous pulse appears as soon as the ventricle contracts. In Figs. 220 and 221, where the venous pulse of the ventricular

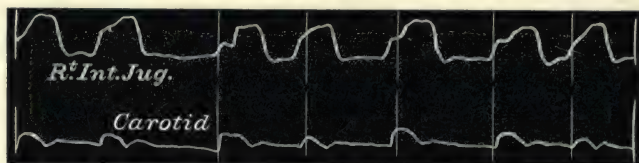


FIG. 221.—Shows the same as Fig. 220.

type is taken at the same time as the carotid, the venous pulse occurs earlier than in the carotid. The time is exceedingly short, but it is distinct, and corresponds to the presphygmic interval in the cardiac cycle. In Fig. 222, where the apex

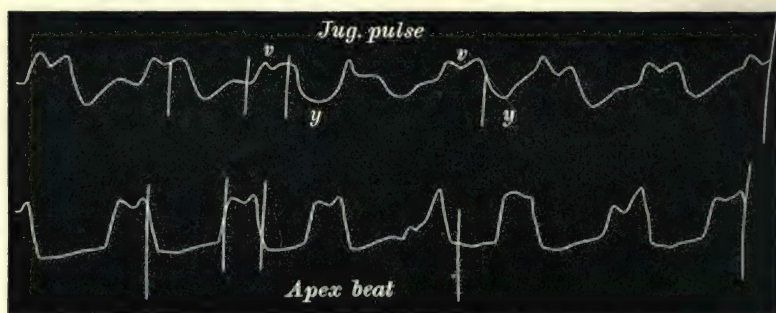


FIG. 222.—Simultaneous tracings of the jugular pulse and of the apex beat. The jugular pulse is of the ventricular form, and its duration corresponds to that of the apex beat.

beat and venous pulse are taken together, these events appear almost simultaneously, the slight difference in time being due to the venous wave having to travel from the heart to the jugular vein (see also Figs. 180 and 181, and § 154).

§ 182. *The ventricular venous pulse represents the pressure variations within the right ventricle.*—In all tracings of the venous pulse of the ventricular type, the beginning of the wave occurs slightly earlier and the duration lasts longer than the systolic wave of the arterial pulse. Its duration in fact corresponds more to that of the apex beat. The duration of the apex beat corresponds to the time of increased ventricular pressure, and as the increased ventricular pressure is directly communicated in such cases through the dilated tricuspid orifice



to the veins, there is therefore a correspondence in the duration of the apex beat and venous pulse and of the whole period, *Hg*, in Fig. 176. The prolongation of the venous pulse wave after the closure of the semilunar valves has already been pointed out (§§ 174-176) as being due to the continuance for a brief space of the high ventricular pressure after the valves have closed. One might, therefore, represent the tracing of the ventricular venous pulse as showing variations of the pressure within the right ventricle. This holds true in regard to the great change from systole to diastole, and may even hold true of the pressure during systole, as in Figs. 180 and 181; but the change in the venous pulse during the systole, as in Fig. 225, must be modified by more conditions than the ventricular pressure. How this comes about is explained in § 176 (see also § 236).

§ 183. *The period of stasis in the ventricular venous and*

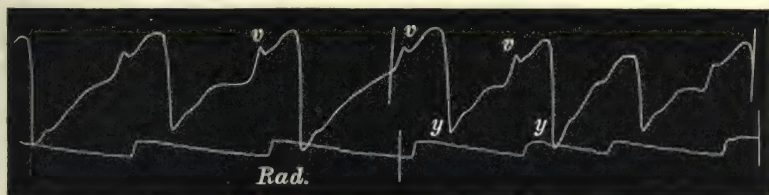


FIG. 223.—Simultaneous tracings of the jugular and radial pulses, showing period of stasis from *y* to *v*.

*liver pulses.*—In the ventricular form of the venous and liver pulses there is but one large wave and one large depression. The depression being due to the abstraction of blood from the veins during the ventricular diastole, its character varies with the degree of engorgement of the right heart. When the engorgement is not so great as to distend the veins during the ventricular diastole, the diastolic period may be represented by a straight line in the tracing, as in Fig. 221. When, however, there is great engorgement of the right side of the heart the diastolic depression is brief, and the lever begins to rise early in the diastolic period. This is well seen when there is considerable engorgement and a slow acting heart. Thus in Fig. 223, immediately after the lowest part of the tracing, the lever begins gradually to rise, due to the distension of the vein on account of the stasis. The more or less gradual ascent of the lever due to the passive distension of the vein is suddenly increased by the true venous pulse wave, *v*. There can be little doubt that the whole period from *y* to *v*

is due to the stasis in the vein, and implies such great engorgement of the right ventricle that the ventricle is evidently filled some time before it contracts. The same features are present in

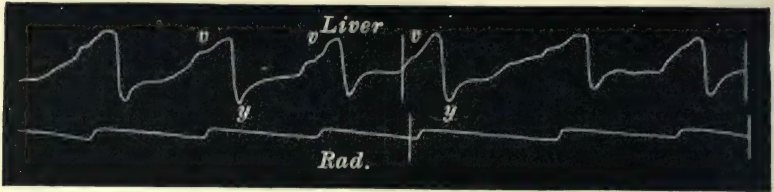


FIG. 224.—Simultaneous tracings of the liver and radial pulses, showing the period of stasis, *y* to *v*.

the liver pulse (Fig. 224). It can also be seen during the long pauses after the premature beats in Fig. 181.

§ 184. *The postsphygmic portion is the most constant part of the ventricular wave.*—In many tracings of the auricular type,

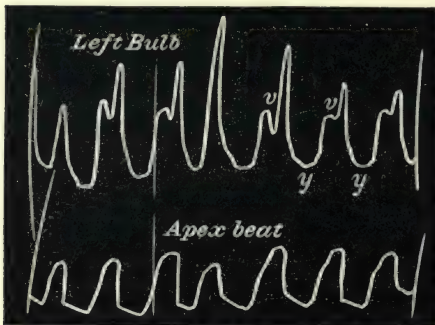


FIG. 225.—Simultaneous tracings of the venous pulse and apex beat, showing the increased size of the venous pulse during the postsphygmic period, and during the occurrence of a premature beat, *v* (see end of § 176).

as has already been pointed out, the ventricular wave is only represented by that portion that occurs after closure of the semilunar valves. When any increase in size of the ventricular wave takes place, it is by the appearance of the wave in front of this postsphygmic portion, in the manner shown in the diagram, Fig. 182. When the venous or liver pulse is of the ventricular form,

this portion of the wave is always the most distinct. In some cases, indeed, it is markedly higher than the earlier part. In Fig. 225 the jugular pulsation is of the ventricular type, and shows a very striking rise of the latter portion of the ventricular wave. In the liver pulse the ventricular wave usually occurs as a gradual rise, due to the swelling of the organ, but even here the postsphygmic portion is occasionally sudden and abrupt, as in Fig. 227. The persistence of this portion of the tracing is well seen in Fig. 226. In the patient from whom this tracing was obtained the jugular pulse would sometimes disappear altogether. On holding the breath the blood would accumulate in the right

heart and great veins, till gradually the pulse in the jugular would appear. The first sign of the returning pulse would be the appearance of this postsphygmie portion. It will be seen




FIG. 226.—Simultaneous tracings of the jugular and carotid pulses, showing the persistence of the postsphygmie part of the venous pulse.

in the tracing that the pulse is sometimes double waved and sometimes single waved. The former occurs during expiration, when the veins are fuller, and the latter during inspiration.

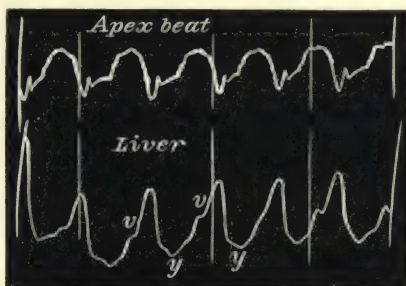


FIG. 227.—Simultaneous tracings of the apex beat and of the liver pulse, showing that the highest portion of the liver pulse is during the postsphygmie period.

When single waved, the wave always occurs after the closure of the pulmonary valves. The liver pulse (Fig. 227) is from the same patient.



## CHAPTER XXI

### ENLARGEMENT AND PULSATION OF THE LIVER

- § 185. Neglect of the signs and symptoms.
- 186. Signs of congestive enlargement of the liver.
- 187. Cause of the congestive enlargement.
- 188. A liver pulse usually present in congestive enlargement.
- 189. Intimate relationship between hepatic and venous congestion.
- 190. Two forms of liver pulse.
- 191. The auricular liver pulse a probable sign of tricuspid stenosis.
- 192. Differences between the venous and liver pulses.
- 193. Differential diagnosis of the liver pulse from (*a*) movements communicated to the liver by the heart ; (*b*) the pulse of the abdominal aorta.

§ 185. *Neglect of the signs and symptoms.*—The symptoms arising from regurgitation of the blood into the liver from the heart receive but scanty notice even in our most recent text-books. It has been noted and slightly commented on by several writers, as Stokes, Broadbent, and Graham Steell, but the subject has not yet received that attention it deserves, and in some systematic treatises it is not once referred to. The attention of many observers is concentrated too often upon the heart itself, to the neglect of many remote symptoms of no less moment, and sometimes of far more diagnostic value. In many cases the changes in the volume of the liver offer a most instructive indication of the condition of the circulation.

§ 186. *Signs of congestive enlargement of the liver.*—The usual means for recognising the increase in the size of the liver are very often at fault. To read the description in a book of physical diagnosis one would imagine there should be no difficulty. If the abdominal walls are lax and there is no œdema present, nor much flatulent distension, then the recognition of enlargement will be as simple as the physical diagnosis text-books make it. But unfortunately in the majority of cases the patient's

condition renders the examination of the liver a matter of peculiar difficulty. Thus a very frequent symptom present in distension of the liver is great tenderness of the tissues forming the external body-wall covering the liver. Not only may the skin and subcutaneous tissues be tender to pressure, but the abdominal muscles are often extremely sensitive. In consequence of this, they become hard and rigid as soon as one exercises pressure upon them. The tenderness is too often assumed to be in the liver itself, but if the muscle be carefully pinched up it can be demonstrated that the tenderness is not in the liver. Further, the tenderness is found to extend much further than the limits of the liver. The presence of this extensive area of hyperæsthesia is sometimes diagnostic of liver enlargement. With the muscles of the abdominal wall in this rigid state it is a matter of much difficulty to demonstrate the exact limits of the hepatic dulness. The distinction between the resonant note obtained by percussion of the bowel and the dull note on percussing the liver, often helps but little. The liver so readily conveys the resonance from the underlying bowel that it is often impossible to mark the limits by percussion. Palpation, on the other hand, helps materially if one exercises pressure carefully and gently. Even if the sharp liver edge cannot be defined, the curious sense of resistance conveyed to the pressing finger often reveals the enlarged liver. With abdominal ascites, on displacing the fluid by means of intermittent pressure, one can sometimes feel the hard underlying organ. Other methods may be adopted, such as pushing the liver forward by one hand placed behind, while the other explores the front. Or, if the patient is fit, making him bend over on his knees, when the liver falls against the anterior abdominal wall. All these methods may fail. The ascitic or gaseous distension of the abdomen, or the condition of the abdominal wall, may baffle our best endeavours. Even then I have been able to obtain evidence of the liver enlargement, by gently but firmly pressing the liver receiver into the abdominal wall at different places till I got the under surface of the liver. That I had got the under surface was demonstrated by the pulsation of the liver being communicated to the tambour.

§ 187. *Cause of the congestive enlargement.*—So far as my experience goes, enlargement of the liver occurs mostly in cases of heart failure consequent on organic disease of the valves. In

muscle failure it is not so frequent, though Steell<sup>52</sup> mentions it as a symptom in alcoholic muscle failure. I have also found it in a number of advanced cases of alcoholic muscle failure. It also occurs in the great dilation of the heart due to adherent pericardium. It may occur in other cases of heart failure, but I have not observed it.

§ 188. *A liver pulse usually present in congestive enlargement.*—When there has been enlargement of the liver, in all my cases of valvular disease I could demonstrate that the liver pulsated. In cases with easily demonstrated liver enlargement and lax abdominal walls, this pulsation may easily be detected. The hand laid over the enlarged liver is gently heaved up and down. But in the great majority of cases I have been unable to say whether the liver pulsated or not until I had explored it with the liver receiver after the manner already described (§ 9). Once the liver has begun to pulsate, I question if ever it ceases again while the patient lives. In the cases where there has been marked enlargement of the liver during an attack of heart failure, when the liver shrinks, and to all our methods of examination it evidently is not increased in size, yet, by careful exploration of its under surfaces with the receiver, I have been able to demonstrate that the pulsation continued. In this respect the liver pulse is a more constant sign, when once established, than the venous pulse, inasmuch as the latter may disappear for long periods.

§ 189. *Intimate relationship between hepatic and venous congestion.*—The relationship between the liver pulse and the jugular




FIG. 228.—Tracing of the internal jugular pulse. After the three large waves pressure was applied by the hand to the liver, and the vein became full and large, and the amplitude of the waves diminished.

pulse is a very intimate one. In some cases where there is marked enlargement of the liver, if gentle but firm pressure be applied to the liver, the jugular veins can be seen to fill up and the pulsation diminish because the vein no longer empties so completely during diastole. In Fig. 228 this is well marked. After three beats of the jugular pulse were taken pressure was applied over the liver,—the vein immediately became distended, and the amplitude of the individual wave diminished. Doubtless the cause of this is that the blood



pressed from the liver increases the distension of the right heart and superior vena cava. Usually such pressure on the liver causes increased dyspnoea.

§ 190. *Two forms of liver pulse.*—The pulsations in the liver can be divided into two groups, with attributes similar to those characteristic of the two groups of the venous pulsations, namely an auricular and a ventricular.

When a liver pulse and a pulse in the internal jugulars are present in the same individual they are of identical form—a pulse of the auricular form in the veins being always associated with a pulse of the auricular form in the liver; a pulse in the veins of the ventricular form being always associated with a pulse of the ventricular form in the liver—an auricular venous pulse never being associated with a ventricular liver pulse, or *vice versa*.

This is of course to be expected, when the cause of the different forms of the pulse is considered, for the regurgitant waves of blood flow as freely into the inferior vena cava as into the superior. But although regurgitant waves of blood may reach the inferior vena cava, they do not necessarily produce a liver pulse. As already stated, the great majority of cases that exhibit the auricular venous pulse never present the slightest symptom of the liver pulse. The liver pulse of either form only appears in patients with failing compensation from valvular disease. The regurgitant waves of blood in "functional" heart failure never produce a liver pulse (§ 162). In most cases of heart failure from valvular diseases, the muscle for a time hypertrophies to overcome the difficulties opposed to its work. Thus, when the auricle is paralysed and the tricuspid orifice widely incompetent, the powerful right ventricle sends waves of blood back into the veins with much greater force than the weak-walled auricle can exert. This force is sometimes so great that the hand placed upon the greatly enlarged liver is gently heaved up and down with each

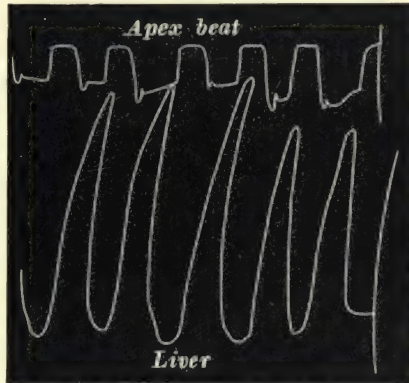


FIG. 229.—Simultaneous tracings of the apex beat and of the liver pulse. The liver edge was below the level of the umbilicus, and its pulsation of great size.

cardiac revolution, and the lever usually employed to take these tracings executes excursions of great dimensions (Fig. 229). While the ventricular liver pulse is fairly common in all cases of advanced heart failure from mitral disease, the auricular pulse is not so often met with.

§ 191. *The auricular liver pulse a probable sign of tricuspid stenosis.*—In tricuspid stenosis, where the auricle at first hypertrophies, the waves sent back by the auricle are of sufficient strength to cause a marked pulsation in the liver. In the cases of auricular liver pulse where I have had a *post-mortem* examination (seven in all), there has always been tricuspid stenosis present as well as mitral and aortic disease. I therefore reasoned that this was due to the hypertrophied auricle, which increased so greatly in strength to overcome the resistance opposed to its work by the stenosed tricuspid orifice that waves of blood were sent back of sufficient strength to distend the liver, and hence that the liver pulse of the auricular type was a probable diagnostic sign of the tricuspid stenosis. Tricuspid stenosis, it may be remarked, is rarely recognised during life, and in my cases only two had a recognisable presystolic murmur about midsternum, and one of these only exhibited this sign a few days before death. During

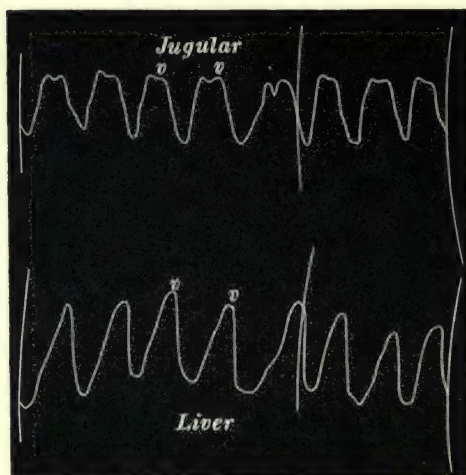


FIG. 230.—Simultaneous tracings of the jugular and liver pulses, to show the difference in the character of the wave.

the life of four of my patients I confidently predicted that tricuspid stenosis was present from the long continued presence of the auricular liver pulse. Although my prediction was verified, yet, as I have already said, I am not sure of its universal application.

§ 192. *Differences between the venous and liver pulses.*—There are some slight differences in the character of the liver and venous pulses.

The sponge-like substance of the liver blots out several of the more minute details found in the venous pulse. Thus

the notch in the ventricular wave is rarely seen. Its presence, however, is indicated in Figs. 183 and 227. In Fig. 230 the venous and liver pulses of the ventricular type are given, showing the smoother appearance of the liver pulse compared with the venous pulse. Thus the liver pulse does not serve equally well for the study of the more minute incidents that take place in the cardiac revolution (see also Figs. 197 and 198).

§ 193. *Differential diagnosis of the liver pulse from (a) movements communicated to the liver by the heart.*—I would

again call attention here to a possible error in diagnosis of the liver pulse. The proximity of the heart to the liver causes certain movements of the liver that are often quite perceptible. These movements have already been considered. They bear no resemblance to the ventricular




FIG. 231.—Simultaneous tracings of the carotid and liver pulses of the ventricular form, showing the rise in the liver tracing to occur with the carotid pulse.

form of liver pulse, because that wave distends the liver during the ventricular systole, causing the wave, *v*, in Figs. 227 and 231, whereas the liver is drawn upwards during the ventricular systole in the cases where the heart mechanically displaces the liver (§ 27). When the liver is drawn up the tracing shows a fall, as the receiver being placed under the liver records a descent of the

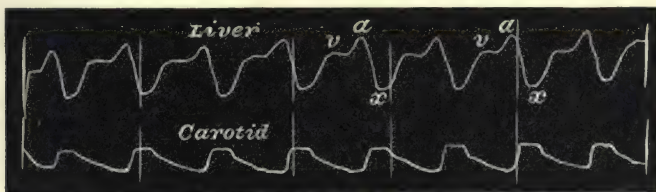


FIG. 232.—Simultaneous tracings of the liver pulse and of the carotid pulse. The liver pulse is of the auricular form, the fall after the auricular wave, *α*, begins before the carotid pulse.

liver by a rise of the lever, and a recession of the liver by a fall of the lever. But confusion may arise between the liver pulse of the auricular form and this mechanical displacement of the liver. In the liver pulse of the auricular type the auricle distends the liver at the same time that the filling of the ventricles pushes the liver down, and the auricular diastole causes shrinking



of the liver at nearly the same time that the liver is drawn up, in consequence of the shrinking of the ventricles during their systole. One can readily differentiate these two movements by

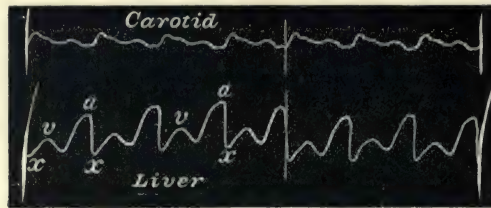


FIG. 233.—Shows the same thing as Fig. 232.

accurately noting the time when the liver tracing begins to fall. In the case of the liver pulse it begins to fall immediately after the auricular systole and before the appearance of the carotid




FIG. 234.—Simultaneous tracing of the liver movements due to emptying and filling of the ventricles and of the carotid pulse. The fall in the liver movement begins after the carotid pulse.

pulse (Figs. 232 and 233). When the liver movement is due to the filling and emptying of the ventricles, the fall can only occur when the ventricle begins to empty; hence the fall in the tracing occurs a little later than the appearance of the carotid pulse (Figs.

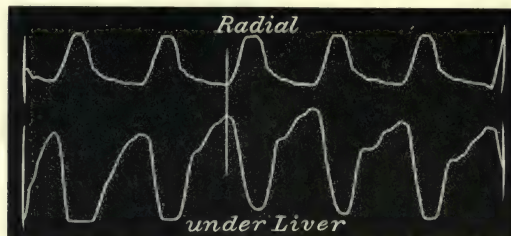


FIG. 235.—Simultaneous tracing of the radial pulse and the liver movements, due to emptying and filling of the ventricles; compare the time of the great fall here with that in the auricular liver pulse, Fig. 189.

234 and 33). The difference is still more marked when the auricular liver pulse is taken with the radial (Fig. 189), and compared with the liver movement due to the filling and emptying of the heart and the radial (Fig. 235).

(b) *From the pulse of the abdominal aorta.*—Generally there is little difficulty in distinguishing the pulsation of the abdominal aorta from that of the liver pulse. In cases where

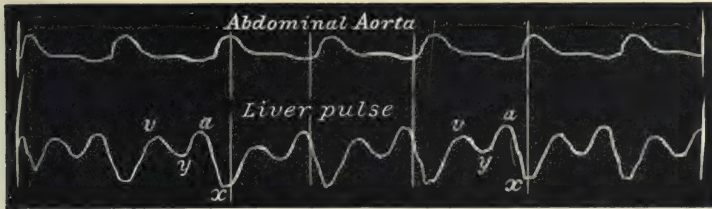


FIG. 236.—Simultaneous tracings of the abdominal aorta and of the auricular liver pulse.

the ventricular liver pulse is present it is very rare that the abdominal aorta can be felt, and the characters of the tracings are readily distinguishable. Still more distinct in character is the auricular form of liver pulse from that of the abdominal aorta, as shown in Fig. 236.

## CHAPTER XXII

### THE CLINICAL SIGNIFICANCE OF THE VENOUS AND LIVER PULSES

- § 194. Difficulty in recognising a venous pulse.
- 195. The grouping of cases.
- 196. A. The venous pulse without organic valvular disease.
- 197. The venous pulse is significant of cardiac dilatation.
- 198. Cases in which the auricular venous pulse occurs.
- 199. The venous pulse in recoverable conditions (anæmia, pregnancy, fatty loaded heart, etc.).
- 200. The venous pulse in fatal exhausting diseases (malignant cachexia and pernicious anæmia).

§ 194. *Difficulty in recognising a venous pulse.*—Before entering upon a consideration of this portion of the subject, it is necessary again to insist upon the difficulty of recognising the pulse in the veins. From the somewhat perfunctory notices in most of the text-books one would imagine that the sign is not only easy of recognition, but of little importance when it is recognised. As a matter of fact, but few people do recognise it even when present in a very exaggerated form, and even when recognised its significance is but rarely appreciated. I say this all the more confidently, as many of my patients have been under the care of some of the most experienced and eminent physicians in the kingdom, and the sign in every case when present was overlooked. In one case, where it was very large, and where there was also enlargement and pulsation of the liver, the eminent physician wrote to me saying the prognosis was fairly hopeful, as there was no evidence of backward pressure of blood from the heart.

Probably the oversight of the venous pulse has been due to the fact that in a great many cases its presence is of little importance, and the patient's condition can be fairly gauged from



the other more readily understood symptoms. While this is undoubtedly true, yet there is a large number of patients in whom the presence of the sign gives a clue to a better understanding of the power of the heart, besides bringing the physician into more intimate relationship with the action of the various chambers of the heart.

§ 195. *The grouping of cases.*—The cases presenting a venous pulse can be divided into three groups. For the sake of clearness of description these groups will be considered under the following heads: viz. (A) the venous pulse without organic valvular disease; (B) the venous and liver pulse consequent on organic valvular disease; (C) the venous pulse in acute dilatation of the heart.

§ 196. A. *The venous pulse without organic valvular disease.*—The form of venous pulse under the first head is invariably of the auricular form, and there is never present a pulse in the liver. The venous pulse may be present in a slight form in people evidently in good health, in whom no defect can be detected in the circulation, and whose subsequent history testifies that the presence of the venous pulse has been associated with nothing prejudicial to their health. Although this is quite true, yet I am of opinion that the circulation in healthy people who show this symptom is not as efficient as in others,—that, as a matter of fact, the field of response is to a certain extent limited, much in the same manner as it is in people with naturally soft and dicrotic pulses. They may pursue their ordinary routine of life without embarrassment, but they are more readily rendered breathless on excessive exertion.

§ 197. *The venous pulse is significant of cardiac dilatation.*—I have already pointed out that the right heart readily accommodates itself to increased engorgement by the widening of the tricuspid orifice and of the ostial veins, so that the free escape backwards of the blood saves the right ventricle from being embarrassed in its work (§§ 143 and 144). To keep the chambers of the heart fitted to do their work effectively a certain amount of vigour in their muscular structure is necessary. If from any cause there should be a defect of the muscular vigour, the chambers do not contract effectively, a certain amount of residual blood remains, and a slight degree of dilatation takes place, permitting the regurgitation already referred to, with the outward and visible sign of a pulsation in the jugular veins.

It follows, then, when a venous pulse is present, in order to estimate its importance we have to inquire into the conditions that may induce the dilatation of the heart, which is indicated by its presence.

§ 198. *Cases in which the auricular venous pulse occurs.*—So far as I have considered the question these cases can be divided into three fairly well defined groups: (1) In recoverable conditions, where the venous pulse appears in consequence of simple dilatation of the heart without disease of the myocardium, and where restoration to health occurs with disappearance of the cardiac enfeeblement, as in the curable anæmias, pregnancy, fatty loaded heart; (2) In fatal exhausting diseases, where there is dilatation of the heart, but where the conditions giving rise to it are fatal, as in the cachectic conditions consequent on malignant disease and pernicious anæmia; (3) In degeneration of the muscular wall, where the dilatation is permanent, and ultimately leads to a fatal end, as in chronic myocarditis.

§ 199. *The venous pulse in recoverable conditions (anæmia, pregnancy, fatty loaded heart, etc.).*—This class includes those cases where there is a well-marked venous pulse of the auricular form, with limitation of the field of cardiac response due to weakening of the cardiac muscle, where restoration to health is accompanied with a disappearance of the cardiac symptoms.

I have specified that this class of cases includes the simple anæmias, pregnancy, and fatty loaded heart. There are other cases of cardiac enfeeblement with more or less venous regurgitation, in whom no permanent disease is discernible. The most characteristic of these is seen in patients recovering from an exhausting illness, such as typhoid fever.

*Anæmia.*—The cardiac enfeeblement is but one of the other




FIG. 237.—Simultaneous tracings of the radial and jugular pulse, from a chlorotic girl.

symptoms that have been long known to be associated with anæmia. Except in so far as the venous pulse helps to

demonstrate that there is distinct evidence of dilatation, particularly of the right heart, it has no other significance. With the disappearance of the anæmia it gradually subsides, but may often remain as a faint pulsation. In after years, as during pregnancy, or if the patient becomes debilitated, it may return as large as ever. It would seem that the heart, once having




FIG. 238.—Simultaneous tracings of the jugular and radial pulses, from a chlorotic girl.

been dilated, readily returns to that condition when either a strain is put upon it or when its walls again become enfeebled from any cause. The type of pulse, as I have said, is always auricular, and good illustrations can often be obtained from suitable cases (Figs. 237 and 238). It is not, however, present in all cases, nor does its absence or presence depend upon the severity of the disease.

In pale youths and young men a venous pulse is often present. There is usually a certain amount of breathlessness on exertion. Fig. 177 is from a youth when eighteen years of age. He is now twenty-six years old, healthy and active, yet rather breathless, and still presents a well marked venous pulse. I have also seen a large venous pulse in a case of anæmia following upon repeated attacks of malarial fever, and with disappearance of the anæmia the venous pulse gradually subsided.

*Pregnancy.*—During pregnancy and for some time after delivery, the most instructive evidence of the venous pulse is to be found; the variations are very striking, and are often capable of satisfactory explanation. The pulse is always of the auricular form (Figs. 194 and 200). That changes take place in the maternal circulation during pregnancy has been long recognised. On account of the occurrence of certain imperfectly understood—and usually misinterpreted—phenomena, it has been assumed that there occurs during this period a sort of physiological hypertrophy of the left ventricle. Whether this is so or not does not directly concern the question in hand. What certainly does occur is dilatation of the cavities of the right heart.



Although there are other accompanying symptoms indicative of this change, it would be unnecessarily introducing controversial matter to enter upon their discussion, and it would obscure the importance of the part played by the most striking of these were the whole subject entered upon. The subject is one, if sufficiently observed and fully discussed, which would throw light upon the variations of arterial and venous pressures, and would lead to a more philosophical appreciation of the forces at work in modifying the circulation. Here I may content myself with stating that the venous pulse may be largely developed during pregnancy, and that with restoration to health it disappears—in many cases permanently.

*Fatty loaded heart.*—In fat people who betray marked shortness of breath on climbing a hill or mounting stairs quickly, the venous pulse of the auricular type is often a very well marked symptom. The cause here, I imagine, is probably the embarrassment of the heart by increase of the pericardial fat. Under strict dietetic regimen, with resumption of greater freedom in respiration, I have noticed the venous pulse disappear.

§ 200. *The venous pulse in fatal exhausting diseases (malignant cachexia and pernicious anæmia).*—This class includes those cases where there is a well marked venous pulse of the auricular type, with marked limitation of the field of cardiac response due to the weakening of the cardiac muscle in consequence of some fatal exhausting disease. The venous pulse




FIG. 239.—Simultaneous tracings of the jugular and radial pulses, from a case of pernicious anæmia.

here forms only one of the symptoms of failing strength. The weakness that characterises the condition of all the muscles of the body likewise affects the heart muscle. While it may be seen well developed in cases of cancerous cachexia, it is in the cases of pernicious anæmia that the venous pulse assumes the largest proportions (Fig. 239). Its clinical significance is overshadowed by the gravity of the disease that gives rise to it. With its presence so well marked and with the symptoms of

cardiac distress so evident, there may be difficulty in the first instance in deciding whether the cardiac trouble is not after all the sole trouble. Thus in May 1899 I saw in consultation a man aged forty-five, complaining of weakness and breathlessness on exertion. The only objective symptoms were slight pallor, a systolic murmur at the base of the heart, and marked pulsation in the veins of the neck. It was difficult to decide whether the case was an early pernicious anæmia, or some form of myocarditic degeneration. I saw him again a year after. He had made a

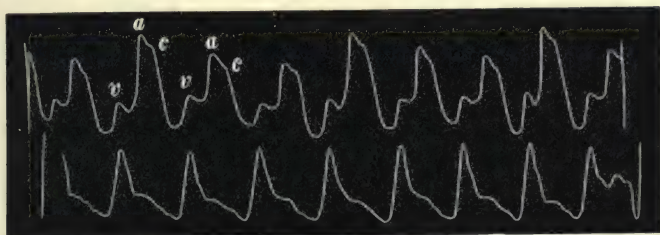


FIG. 240.—Simultaneous tracings of the jugular and radial pulses, from a case of pernicious anæmia.

temporary partial recovery, but was now undoubtedly suffering from pernicious anæmia. The pulsation in the neck was greatly increased (Fig. 240). He died a month later. At the *post-mortem* examination there was marked dilatation of the tricuspid orifice, slight of the mitral, and the cardiac muscle on microscopic examination presented marked fatty degeneration. Usually, as in the foregoing instance, the subsequent history of the case clears up the doubt. But when the venous pulsation is present, and it cannot be decided whether it is secondary to the exhausting disease or to degeneration of the heart wall, it is nevertheless a sign of the gravest significance.

## CHAPTER XXIII

### THE CLINICAL SIGNIFICANCE OF THE VENOUS AND LIVER PULSES (*Continued*)

- § 201. The degeneration of the heart muscle (fatty and fibrous, due to atheroma, alcohol, and overstrain).  
202. Illustrative cases.  
203. B. The venous and liver pulses consequent on organic valvular disease.  
204. Character and significance of the venous and liver pulses in mitral disease.  
205. Prognostic value of the venous and liver pulses in pregnancy.

§ 201. *The degeneration of the heart muscle (fatty and fibrous, due to atheroma, alcohol, and overstrain).*—This class includes those cases where there is a well marked venous pulse with marked limitation of the field of cardiac response, due to degenerative changes in the cardiac muscle.

The extreme difficulty of giving a prognosis in cases of heart failure meets us continually. We see patients reduced to the most helpless condition from heart failure, and for weeks may daily expect them to die, yet they recover and may for years pursue laborious occupations. On the other hand, a patient may exhibit slight forms of heart failure at first, and our means of examination fail to yield us any definite signs of serious mischief; yet the patient may be suddenly struck down, or he steadily drifts to his death.

Speaking generally, patients with organic valvular disease rarely die during the first attack of extreme heart failure. Many indeed recover from repeated attacks. Here the muscle itself is not the seat of disease, but has the power of recovering itself with rest. But when the heart muscle itself is diseased (fibrous or fatty degeneration) there is no such recuperative power. But the difficulty is to recognise this change. If any one studies the symptoms given by writers for the recognition of these degenerative changes, it will be found that there is



nothing absolutely definite, and the symptoms present are compatible with conditions apart from muscle degeneration. There may be presumptive evidence, but no absolute diagnostic evidence.

I do not pretend to be able to give evidence that will be present in all cases, but there are some cases in which the occurrence of regurgitant waves of blood into the veins testifies to the failure of the heart. After examination of patients when this symptom is present, and after we have excluded the cases mentioned under the two foregoing groups, there is a residue where the presumption is in favour of serious degenerative changes occurring in the muscle.

If then we find a patient who has marked limitation of the field of cardiac response, over forty years of age, in whom there is a considerable venous pulse of the auricular type, even though there be no definite symptom observed after physical examination of the heart, the probability is that we have to do with serious degenerative changes in the heart muscle. Even subjects younger than forty may exhibit this symptom, especially if they have been exposed to hard physical labour or to excessive indulgence in alcohol. The truth of this assertion has been gradually borne in upon me by watching the after-history of a number of cases in which the venous pulse was the main objective symptom. I was struck by observing that these patients showed little tendency to recover, and that they sooner or later died. Looking back upon my observations of such cases I found that nearly all that I was able to trace died within a comparatively short time after the observation. The cases were by no means identical, nor were the predisposing causes alike. In only a very few have I been able to obtain a *post-mortem* examination. I can only say this much, that in the cases examined the muscle wall of the heart had become so enfeebled from degenerative changes that progressive heart failure ultimately caused their death. As this view treats the subject from a somewhat new aspect, I will quote a series of illustrative examples, referring only to the salient points in each case.

§ 202. *Illustrative cases.*—Case 1, female, aged sixty-one.—Complains of severe pain in left forearm, great weakness and shortness of breath on the slightest exertion. The patient is pale, with careworn face and anxious expression. The pulse is regular, full,

soft, and compressible, and the arteries are atheromatous. It is always quick, from ninety to one hundred beats even when laid in bed. There is marked pulsation in the veins of the neck, tracings of which reveal simply the auricular wave, with the small wave due to the carotid pulse (Fig. 206). There is a slight increase in the area of the heart's dulness. The second sound over the second right costal cartilage is exceedingly loud and like a drum-tap. The patient was under observation for some months, and was at first slightly benefited by three weeks' rest in bed. Dropsy, however, set in, and she died rather suddenly during an attack of diarrhoea. On *post-mortem* examination the coronary arteries were found converted into calcareous tubes, and on microscopic examination the muscular substance of the heart was found to be replaced to a considerable extent by fibrous tissue. In this case the fibrous degeneration was evidently consequent upon the advanced atheroma of the arteries. The enfeebled muscle wall permitted dilatation, so that the auricular systole sent waves of blood through the widened ostial veins.

Probably the next case was of the same nature, although my notes are not so full, as I saw him but once in consultation.

Case 2, male, aged fifty-eight years.—Complains of great weakness and shortness of breath, which have been gradually

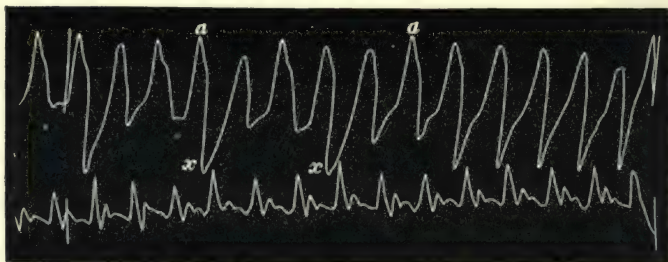


FIG. 241.—Simultaneous tracings of the jugular and radial pulses. There is but one large wave in the venous pulse, due to the auricular systole.

increasing the last few years. The face is pale. The pulse is small, soft, regular, and quick. There is a large pulsation in the veins of the neck, which is shown in the tracing (Fig. 241) to be single waved and auricular in time. There was no increase in the area of the heart's dulness, and the sounds were free from murmur. This patient, I heard afterwards, made no progress

towards recovery, but died within the twelvemonth from the time I saw him.

The symptoms were very similar in the following case, although the history of shortness of breath is of much longer duration. As in case 2, I saw him but once in consultation.

Case 3, male, aged fifty years.—Is a weaver, but worked as a collier till twenty-four years of age. Has been rather short of breath on exertion for many years. Had pneumonia ten years ago, but was breathless on exertion before then. The pulse is small, soft, and quick—one hundred and sixteen per minute. The feet are slightly swollen, the abdomen hard, and there is enlargement of the liver. There is marked pulsation of the jugular veins, a tracing of which shows it to be single waved and auricular systolic in time (Fig. 207). The heart's dulness extends to the left beyond the nipple and half an inch to the right of the mid-sternum. There is no apex beat. The first sound is soft, but no distinct murmur heard anywhere; the second sound is accentuated in the aortic and pulmonary areas. The respirations are laboured—twenty-eight per minute; the base of the left lung is dull, and the breath sounds are absent; the right base is slightly dull, with numerous moist crepitations on deep inspiration.

The picture here is one of advancing failure of the heart, the most striking feature being the enormous wave in the jugular vein. The patient never rallied, and died three months after I saw him.

Excessive indulgence in alcohol is sometimes a cause of a very severe form of muscle failure. In some cases it leads to permanent impairment of the muscle structure, probably by fatty degeneration, as in the following case.

Case 4, female, aged fifty-two years.—For many years a secret




FIG. 242.—Tracing of a large venous pulse of the auricular form.

drinker, has been weakly for months, with anorexia and swelling of the legs. There is slight enlargement of the heart's dulness



to the right, and a loud systolic murmur at the base of the heart and over the middle of the sternum. There is marked pulsation of the auricular form in the internal jugular veins (Fig. 242). The patient's strength gradually sank, and towards the end of her life the pulsation was well marked, even in the veins of the face and scalp. After death there was found great dilatation of the right side of the heart, with extensive fatty degeneration of the walls, but no valvular disease.

Case 5, male, aged forty-eight years.—A secret drinker for many years; complains of great weakness and depression. The pulse is quick, soft, and dicrotic—one hundred per minute. There is marked pulsation in the jugular veins of the auricular form. There is slight enlargement and tenderness of the liver, but no pulsation. The area of the heart's dulness is increased. The apex beat is diffuse in the fifth and sixth interspaces outside the nipple line. The sounds are feeble, but free from murmur. The patient, not receiving much benefit from my treatment, went off to a hydropathic establishment, and while undergoing some special bath treatment he suddenly died.

I can only infer from the lack of response of the heart to all efforts to improve its tone, that this patient had extensive fatty degeneration, and his end certainly pointed to that conclusion.

The combination of excess in alcohol with overstrain may produce a serious form of heart failure, probably from the same cause—fatty degeneration, as the following case illustrates.

Case 6, male, aged forty-one years.—Mechanical engineer. Is a heavy drinker; is a strong-looking, well-built man,

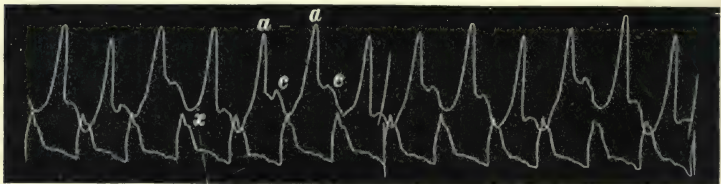

FIG. 243.—Simultaneous tracings of jugular and radial pulses, showing a large wave, *a*, due to the auricle.

accustomed for years to heavy mechanical labour; complains of shortness of breath, sleeplessness, and no appetite. The pulse is quick, soft, and compressible—ninety per minute. There is great pulsation of the jugular veins, due to the auricular systole

(Fig. 243). The heart is only slightly enlarged and there is a systolic murmur, heard best over the third and fourth left costal cartilages. Ten weeks after I saw him the patient died suddenly.

I am unable to say what is the immediate cause of heart failure in overstrain, whether fibrous or fatty degeneration, but that it causes the same serious inefficiency of the heart muscle is evident from the following case.

Case 7, male, aged forty-three years.—A tackler (at times requiring to lift very great weights); complains of shortness of breath, tightness across the chest, and sleeplessness. He is a powerful-looking man. The pulse is soft, small, and rapid—one hundred and sixteen per minute. The pulsation in the jugular is not great, but there is marked pulsation of the superficial veins over the clavicle. The heart's size cannot be mapped out on account of the voluminous lungs and thick chest walls; the sounds are clear and free from murmur. Under treatment he improved slightly, the pulse falling to ninety-six, but nine months after I first saw him he dropped down dead. No *post-mortem* examination was made.

Here, though the jugular pulse was not marked, the pulsation in distal superficial veins is always a grave sign, as in case 4. I have many patients coming to me suffering from overstrain, as I have already said, but there are only a few in whom I have found this pulsation. Possibly overstrain at some time had much to do with cases 3 and 6.

While correcting the notes at this point, a patient who presented symptoms similar to the two foregoing cases died suddenly. He was a moulder, aged forty years. Drank beer regularly, though, he said, not to excess. He complained of tightness across his chest and pain down the inside of both arms when he hurried. There was a systolic murmur at the base, and marked pulsation of the superficial jugular veins and slight of the internal. The pulsation was of the auricular type. Two weeks after I first saw him he dropped down dead. At the *post-mortem* examination there was found a small aneurysm of the aorta immediately above the aortic valves. There was also fatty degeneration of the muscular wall. Whether the aneurysm or the fatty degenerated heart was the immediate cause of death I cannot say, but there is no doubt the fatty degenerated muscle was the cause of the venous pulse.

What was the cause of the heart failure in the following two cases, I am unable to specify. They present some features in common, and differ little from cases of heart failure from valvular disease. But the point I want to call attention to is the striking evidence afforded by the large pulse in the jugular veins. Both patients were men in easy circumstances, and had the benefit of being for a time under the care of some of the foremost physicians of the day. The pulsation in the veins was not recognised by any of them. Whether the jugular pulse indicated that the cases were hopeless from the start I am not prepared to assert, but their cases furnish additional evidence in favour of the proposition I have made regarding this group.

Case 8, male, aged fifty-six years.—Was suddenly seized with extreme breathlessness in the middle of the night. I was sent for, and found him sitting up breathing heavily, and in great




FIG. 244.—Simultaneous tracings of jugular and radial pulses.

distress. I had known him for many years as a robust healthy-looking man, who rarely needed medical attendance. A few months previous to the above attack he noticed that he was rather scant of breath on going up a hill, but thought it was due to increase of fat and want of exercise. From the time of the attack of breathlessness until he died a year later, he gradually grew weaker, while he became extremely dropsical. My notes regarding the condition of his heart at the beginning of his illness are as follows: pulse small, regular, quick—one hundred per minute. Apex beat is felt in the fifth interspace. The heart's dulness extends from  $1\frac{1}{2}$  inches to the right of the midsternal line to  $1\frac{1}{2}$  beyond the nipple. There is a loud systolic murmur heard all over the cardiac dulness, but it is loudest at the apex. The second sound is feeble and rather soft. There is a large pulsation in the neck, the tracing showing it to be of the auricular form (Fig. 244). This patient removed to a seaside town, where he died, and I had no opportunity of getting a *post-mortem* examination.



Case 9, male, aged fifty years.—This patient had consulted me occasionally for years for trivial ailments, and I looked upon him as a healthy man. He went to Ireland for some shooting one autumn, and while there he was seized with great breathlessness, and was laid up for some time. On his return home I found him extremely weak, slight dropsy of the legs, the pulse




Fig. 245.—Simultaneous tracings of the radial and jugular pulses.

small and quick—one hundred and ten per minute, the heart much enlarged, and a systolic mitral murmur. There was marked pulsation of the veins of the auricular type (Fig. 245). Three consultants who saw him at various times were unable to account for the breakdown, unless it was due to failure of a heart enlarged secondary to chronic Bright's disease. There was never any albumin in the urine, and his history also excluded the probability of such a thing. The patient never rallied to any treatment, but the dropsy increased, until he died, four months after the first symptom of heart failure. A *post-mortem* examination was not permitted to be made.

The chain of evidence in most of these cases is unfortunately incomplete, but it is striking that patients with these symptoms,—the occurrence of a large venous pulse of the auricular form, with evidence of great enfeeblement of the heart,—have shown little tendency to rally, but have rather tended to go steadily from bad to worse. Extended experience may show the symptom to be without the fatal significance I have attached to it, but it is curious that almost every case I have had, so far, has justified the prognostication. A few cases still under observation show a like want of response to treatment, and seem steadily drifting to the same end. (See also cases described in §§ 209 and 227.)

§ 203. B. *The venous and liver pulses consequent on organic valvular diseases.*—In cases where there is ample compensation, so that there is no evidence of any limitation of the field of cardiac response, the venous pulse has no more significance that it has in anæmia. It may be present or it may not, and when present it is invariably of the auricular type. Even when compensation begins to fail there are many cases in which no venous pulse occurs. Why this should be I do not clearly understand. In disease limited to the aortic valves a venous pulse is rarely present.

Here the right side of the heart is rarely distended, because, as Balfour,<sup>31</sup> expresses it, the "peculiar sources of mortality are such as to anticipate any important alteration of the right ventricle."

§ 204. *Character and significance of the venous and liver pulses in mitral disease.*—It is essentially in the changes subsequent to organic diseases of the mitral orifice (stenosis or regurgitation) that the variations in the venous pulse are best studied. It is the backward pressure of blood resulting in dilatation of the right side that produces the venous and liver pulses. When compensation fails the venous pulse sometimes becomes very large. At the first it is invariably of the auricular type, and when it is large there is always marked limitation of the field of cardiac response. With recovery of the compensation the venous pulse may diminish or disappear, to return again on the onset of another period of heart failure. In the absence of tricuspid stenosis, after repeated attacks of heart failure, the wave due to the auricle disappears, after the manner already described, and there is left but one large wave synchronous with and due to the systole of the ventricle. As the ventricular venous pulse can only appear when the auricle is paralysed, it may be confidently assumed that when it is present there is great dilatation of the right ventricle and of both auricles. It follows then that the presence of a venous pulse of the ventricular type is always indicative of an advanced stage of cardiac failure. The field of cardiac response is invariably greatly limited. There is a great and a constant liability to attacks of extreme heart failure, any one of which may prove fatal. Yet the patient is not necessarily in immediate danger, for I have watched such cases extending over a period of many years. Thus I got Fig. 227 from the patient in 1892, and she died in July 1900. During all that period the venous pulse has been invariably of the ventricular type. In the majority of cases where the venous pulse is of that type, it is possible to demonstrate an enlargement and a pulsation of the liver. Thickness or hardness of the abdominal wall or the presence of fluid in the tissues or peritoneal cavity may at times obscure its presence. In other cases the sharp well-defined edge of the liver may be felt as low as the umbilicus, and the huge pulsating mass can be easily recognised.

The presence of a liver pulse of either form indicates advanced heart failure. A liver pulse of the auricular form is

suggestive of tricuspid stenosis. The explanation of its occurrence has already been given.

§ 205. *Prognostic value of the venous and liver pulses in pregnancy.*—Besides indicating the condition of the mitral and tricuspid orifice, the presence of a venous pulse of the ventricular form or the presence of a liver pulse of either form indicates an advanced stage of cardiac failure. This may be evident from other symptoms, but its importance should not be overlooked in consideration of the patient's future life and work. I need only specify one instance where it is of the highest importance. In regard to the question of pregnancy with heart disease, the presence of a liver pulse or of a ventricular venous pulse is of the greatest value in determining whether the risk of pregnancy should be incurred, or whether the pregnancy should be interfered with if conception has already taken place. I have had frequent occasion to observe patients, with well marked mitral stenosis, conceive and bear children with no bad after-effects. I do not here intend to enter fully into the consideration when interference should take place or not, but I state most emphatically that women with a liver pulse of either type, or with a venous pulse of the ventricular type, should be prevented from conceiving, and if conception has taken place premature delivery should be induced at the earliest possible moment. The reason for this dictum is that these pulses indicate a stage of failing compensation, so advanced that the additional strain of pregnancy and child-bearing exhausts what little power there is left, and if the mother escapes with her life, it is but to spend her later days in misery. I have not yet found an exception to this statement.



## CHAPTER XXIV

### THE CLINICAL SIGNIFICANCE OF THE VENOUS AND LIVER PULSES (*Continued*)

- § 206. Signs and symptoms of acute dilatation of the heart.
- 207. Acute dilatation in advanced mitral disease.
- 208. Acute dilatation in the absence of valvular disease.
- 209. Illustrative case.
- 210. Explanation of the changes in the venous pulse.
- 211. Acute dilatation of the heart in paroxysmal tachycardia.

#### C. *The Venous Pulse in acute Dilatation of the Heart*

§ 206. *Signs and symptoms of acute dilatation of the heart.*—When the heart is forced to excessive exertion, the walls sometimes yield and permit a considerable amount of dilatation. Certain very well-marked subjective symptoms usually appear in consequence of this overstrain, such as breathlessness and great præcordial distress. Of the objective signs, the pulsation of the veins is sometimes the most striking. In addition to the venous pulsation we get direct evidence in the increased area of the heart's dulness, particularly to the right, and often in the presence of a well-marked regurgitant tricuspid murmur. The arterial pulse is always quickened and of very low pressure.

§ 207. *Acute dilatation in advanced mitral disease.*—These symptoms are caused, as I have said, when a heart is exposed to a great strain. The amount of strain is relative to the strength of the heart. A heart otherwise sound and healthy yields only after some very exhausting effort. A heart intrinsically weak yields after an effort that is relatively very slight. In cases of advanced disease of the mitral valves, the patient is always liable to break down, the condition in extreme heart failure being in reality a dilatation of the heart. The symptoms present in these cases have already been pretty fully indicated. We have

seen that they vary with the stage at which the heart failure has arrived. In the earlier stages there is engorgement of the right side, so that the auricular systole is much embarrassed. The auricle's power of contraction is distinctly limited. It may even be completely paralysed. The liver becomes engorged and pulsates. With restoration of the heart's power these symptoms subside. The liver diminishes in size and the auricle's power may be re-established (Figs. 211-215).

§ 208. *Acute dilatation in the absence of valvular disease.*

—While such is a brief outline of the symptoms present in dilatation of the heart with organic valvular disease, there are some points difficult to elucidate that occur in acute dilatation where there is no valvular disease, or where the effects of the valvular disease have not advanced very far. I have said that the acute dilatation may take place when a sound heart is exposed to a great strain, or, to put it differently, when a heart contends with a strain greater than it has power to overcome. There are other patients in whom no defect in the heart can be detected, who exhibit acute dilatation of the heart without being exposed to any physical strain. Thus in a long attack of paroxysmal tachycardia the symptoms of acute dilatation may be present in a marked degree. I shall direct particular attention to these shortly. There are other cases, again, where the symptoms of acute dilatation may occur when it is well nigh impossible to assign a sufficient cause. Thus a patient of mine, a male aged thirty-six years, who was suffering from a subacute attack of rheumatoid arthritis, was suddenly seized with extreme breathlessness. When I saw him he was sitting up in bed, breathing heavily, with an expression of extreme discomfort, and complaining of weight and oppression over the chest, and of a sensation as if he were being suffocated. The pulse was quick—one hundred and twenty per minute, the heart's dulness markedly evident to the right of the sternum. But the most striking feature of all was the condition of the veins of the neck. He was a very spare man, and all the superficial and deep jugulars were full and beating very strongly. There were two beats in the veins to one of the pulse, the movements in the veins thus being at the rate of two hundred and forty per minute. The smaller veins flickering and the larger ones pulsating largely gave a most animated appearance to the neck. By the next day all the symptoms had subsided, and there has been no

return of the condition. I could detect nothing wrong with the heart.

Such cases are taken so suddenly and so unexpectedly ill that one has not always the opportunity to make sufficiently precise observations. I have occasionally been fortunate enough to get a fairly good record of the condition at various periods. But these instances have been too few to enable one to assert with absolute confidence what are the results of the sudden giving way of the muscle wall of the heart. Nevertheless, the symptoms are so striking that one is justified in calling attention to them in the hope that they will either be confirmed or a better interpretation supplied by subsequent observations. The first case I shall give leaves little room for speculation. The facts are sufficiently clear as to be easy of interpretation. In the state of extreme dilatation one notes the evident failing strength of the auricle. With improvement the increase in strength of the auricle can be inferred by the increase in the size of the wave, and of the depression due to the filling of the auricle. In the cases of paroxysmal tachycardia to be cited, the dilatation had become so extreme that one is driven to the conclusion that the auricle had ceased to contract effectively. Such on the face of it is the inference to be drawn from the facts here presented, but inasmuch as in these cases the heart acted with great rapidity, some doubt as to the interpretation may arise, and I therefore place the facts on record, in order to call attention to the condition.

§ 209. *Illustrative case.*—In the following case the patient suffered from some obscure condition of the heart that predisposed him to the attack. He was a man aged thirty-seven years. I had attended him several times during the past two years. He was given to occasional heavy drinking bouts, but I could never detect anything wrong on physical examination. For the past year he had noticed that he was more readily rendered short of breath on exertion. He had been making merry with some friends on the night of the relief of Mafeking. For some days after this he did not feel quite up to the mark. On the tenth day after his carouse he took a walk into the country to try and rid him of the depression that hung over him. The road was a hilly one, and he was forced to stop at frequent intervals to recover his wind. On his return home he felt so ill that I was sent for. I found him lying in bed with his shoulders raised, tossing uneasily



from side to side. His face wore a look of distress. His eyes were slightly jaundiced. His temperature was 101°. The radial pulse was large, full, and very compressible—one hundred and thirty beats per minute. The apex beat was diffuse in the nipple line. The heart's dulness extended half an inch to the right of the middle line. There was a loud blowing systolic murmur heard most distinctly over the third left costal cartilage. There was a great tenderness to pressure of the tissues covering the liver (subcutaneous tissues, and abdominal muscles). But the most striking feature was the pulsation of the veins of the neck. He has rather

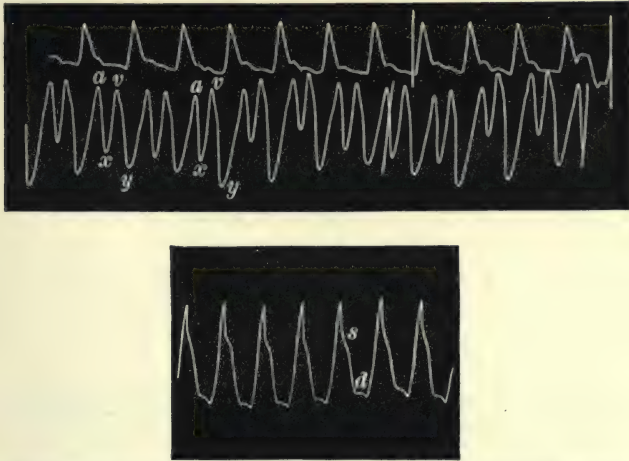


FIG. 246.—Simultaneous tracings of the radial and jugular pulses. The auricular wave (*a*) and the auricular depression (*x*) are smaller than the ventricular wave and depression (*v* and *y*). The full radial beats show a pulse of very low arterial pressure—first day.

a long neck, and the movement in the veins was so great as to be visible from a distance of five or six yards. It extended as high as the angle of the jaw. As there were two pulsations in the jugular for one of the pulse beat—about two hundred and sixty per minute—the neck presented the appearance of continuous movement. In Fig. 246 there is a tracing taken at this examination. The upper tracing is the radial—its size reduced to permit a full inscription of the jugular pulse. With each tracing from this patient a few full beats of the radial pulse are given to show the character of the large pulse of low arterial pressure. The double waved venous pulse is well shown. The points to be noted in Fig. 246 are the slightly larger size of the ventricular wave, *v*, than the auricular wave, *a*, and the greater

amplitude of the ventricular diastolic depression, *y*, than the auricular diastolic depression, *x*. This decrease in the auricu-

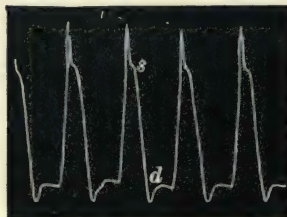
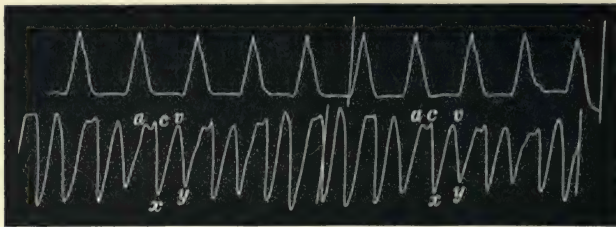


FIG. 247.—This and the following four tracings show a gradual increase in the auricular wave and an increase in the arterial pressure—second day.

lar depression, as I have already stated (§ 173), indicates that the diastole of the auricle is greatly limited. In other

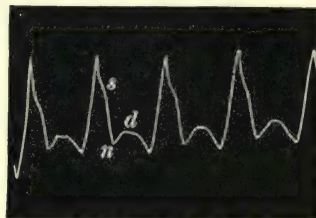
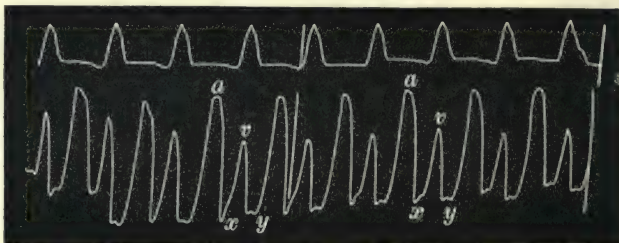


FIG. 248.—Third day.

words, the auricle is over-filled, and its systole only partially empties it of its contents. The ventricular wave encroaches

upon the auricular depression, and, as always happens then, the ventricular depression increases, showing that the chief emptying

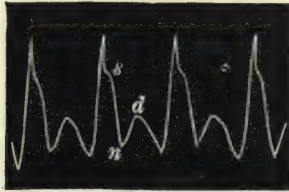
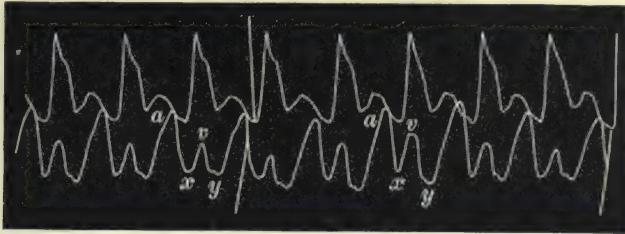


FIG. 249.—Fourth day.

of the veins is due to the ventricular diastole. One can conceive that on a further increase in the dilatation the auricle would cease to act. As a matter of fact, however, from this date all

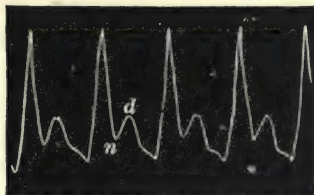
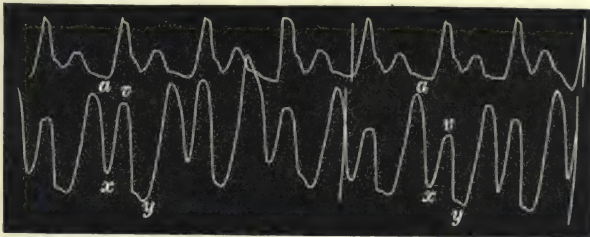


FIG. 250.—Fifth day.

the patient's symptoms tended towards improvement: the area of the heart's dulness diminished, the systolic murmur indeed persisted, but it lost much of its intensity, the breathing



became more easy, the jaundice and liver tenderness disappeared. In the series of tracings (Figs. 247-251) we can see that the radial pulse not only became slower, but the arterial pressure became greater, as evidenced by the relatively higher position of the aortic notch in the radial tracing. Coincident with these changes there is distinct evidence of the gradual recovery of the power of the auricle. In Fig. 247 the wave due to the auricle is not only as large as the ventricular, but the depression,  $x$ , due to the absorption of the venous contents by the auricular diastole, is deeper than in Fig. 246. In Figs. 248-250 the auricular wave,  $a$ , is much the larger of the two waves, in striking contrast to what occurs in Fig. 246. The venous pulse gradually diminished till it became scarcely perceptible, and the radial pulse showed marked increase in arterial pressure (Fig. 251). These

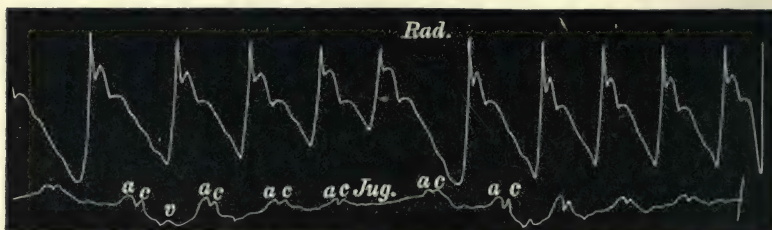


FIG. 251.—Simultaneous tracings of the radial and jugular pulses, taken ten days after Fig. 250. The jugular pulse has almost disappeared, while the character of the radial pulse shows a marked increase of the arterial pressure.

changes were coincident with marked improvement in the patient's health. (While correcting these proofs, nine months later, the patient has again broken down. There is marked pulsation of the veins, *now of the ventricular form*, great lowering of the arterial pressure, and considerable enlargement of the liver.)

§ 210. *Explanation of the changes in the venous pulse.*—In this case we have a weakened heart wall, yielding in consequence of the strain thrown upon it. The nature of the jugular pulsation is sufficient to tell what has happened, but we have also here many other corroborative symptoms. The increase of the heart's dulness was characteristic. The tricuspid regurgitation produced the systolic murmur. The præcordial distress and breathlessness were indication of the embarrassment of the heart's work, while the jaundiced eye and liver tenderness indicated engorgement of the liver. Nor was the slight rise of temperature the cause of these symptoms. Very likely the condition giving rise to the

fever contributed to the enfeeblement of the heart wall. But the presence of a moderate amount of fever in a fairly healthy heart stimulates the heart muscle, increases the capacity of the arterial system, and usually causes the total disappearance of the venous pulse, if such were present prior to the febrile attack.

But the point that I wish to raise here is, What would have become of the auricle if the engorgement of the right heart had increased? If one were to read the foregoing tracings backward, each would indicate a gradually increasing embarrassment of the auricle's activity. If the embarrassment were to proceed further, the auricle would soon cease to act. Such indeed is the course of events depicted in the case illustrating the auricular paralysis (Figs. 183-186). But there was in that case valvular disease, and, so far, I have rarely found paralysis of the auricle except when caused by the engorgement secondary to valvular disease.

§ 211. *Acute dilatation of the heart in paroxysmal tachycardia.*—That paralysis of the auricle may occur when the dilatation is due to other conditions is very doubtful. Yet I have come across a few cases of paroxysmal tachycardia which seem to point to such a condition. But I may point out that the events occur here with such rapidity that a difficulty in interpretation arises. Still, when one closely scrutinises the tracings got in such cases, the paralysis of the auricle is the only explanation that sufficiently accounts for the symptoms. The condition of the first patient from whom the following tracings were taken has already been described in the section under "paroxysmal tachycardia" (§ 103, case 7). He had mitral stenosis, and therefore the changes of the venous and liver pulses are in accordance with the rule I have laid down. But the second case given here had no valvular disease, yet the changes in the venous pulse were identical. It is only necessary here to call attention to the pulsation in the liver and in the veins in the first patient. I have made many observations on this patient during numerous attacks of paroxysmal tachycardia. When he was free from the attack only the faintest movement could be detected in the jugular bulb, and, as Fig. 252 shows, it is only a slight wave preceding the carotid pulse. I was fortunate one day to see him within five minutes after an attack began. The pulse at first was not excessively rapid, and the carotid pulsation was fairly evident, and I took a tracing (Fig. 253) of the carotid immediately above the clavicle, from the same situation that the jugular

pulse in Figs. 252 and 254 was afterwards obtained. In Fig. 253 it will be noted that no sign of the jugular pulse is present. This would imply that at first the increased action of the heart diminishes the venous pressure, as usually happens when the heart is quickened from other causes. The radial tracing in Fig. 253 is not so good as I could have wished; still it shows its time relation to the carotid pulse. When I saw him again




FIG. 252.—Tracings of a slight movement in the jugular vein taken at the same time as the radial pulse. The wave, *a*, is due to the systole of the right auricle.

eighteen hours later the condition of affairs had greatly altered. He had slept little all night; he felt wretched, and complained of great pain in the upper part of the abdomen and behind about the level of the eighth dorsal vertebra. His face had a wan and weary look, and was of a greyish colour. Above the inner end of the clavicles on both sides there was now visible a large and distinct pulsation. If one carefully palpated this part a distinct pulsating tumour could be felt. It did not

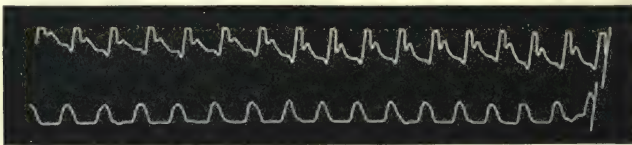


FIG. 253.—Simultaneous tracings of the carotid (upper tracing) and radial pulses at the beginning of an attack of paroxysmal tachycardia. The carotid pulse was obtained immediately above the clavicle, from the same place that the jugular pulses in Figs. 252, 254, and 255 were obtained.

extend up the neck, and was quite distinct from the carotid artery. It was evidently the jugular bulb distended by regurgitating waves of blood. The valves in the jugular and subclavian veins were evidently competent. On auscultating either of these pulsating tumours or under the middle of the clavicle, one very loud sound was heard, synchronous with each pulse beat. These sounds were evidently originated by the sudden and forcible stretching of the jugular and subclavian valves (§ 147). When I applied the receiver connected with



the tambour over this movement, the lever was jerked up with great violence, and the tracing got had a totally different character from that taken at the beginning of the attack. After taking a few beats from the pulsating jugular bulb I applied the receiver over the carotid in the middle of the neck, and got the tracing of this carotid pulse (Fig. 254). The wave obtained

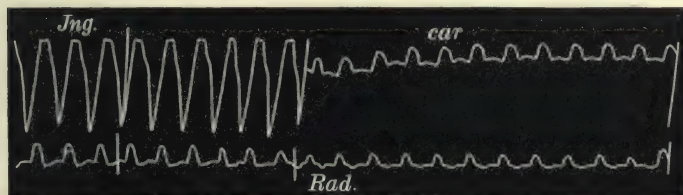


FIG. 254.—Simultaneous tracings of the pulsation in the jugular bulb and in the radial, and of the carotid and radial pulses, during an attack of paroxysmal tachycardia, taken eighteen hours from the beginning of the attack.

from the jugular bulb occurs at the same time as the radial pulse, and must therefore be due to the ventricular systole. I have taken a large number of tracings during many attacks, and they have all presented a similar character. The tracing Fig. 255 was taken after an attack had lasted twenty-four hours. It will be noted that the wave here occurs at the same period as the venous tracing in Fig. 254. That this

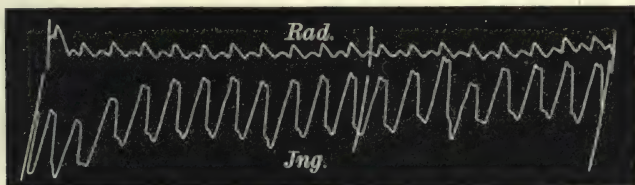


FIG. 255.—Simultaneous tracings of the radial and jugular pulses twenty-four hours from the beginning of an attack of paroxysmal tachycardia.

wave is not due to the carotid can be seen by comparing its character with that of the carotid pulse in Figs. 253 and 254. One could convince one's self that it was not the carotid by examination, the movement being so distinctly limited to the root of the neck, while the carotid above the pulsation could only be found with difficulty. Six months before he died I was able to detect slight enlargement and pulsation of the liver after an attack of tachycardia had lasted fifteen to twenty hours. During the last few weeks of his life he was seldom

free from the rapid action of the heart, and the liver extended three inches below the ribs and pulsated very largely (Fig. 256). As the heart became exhausted the pulse did not acquire so great a rapidity as it did in the earlier stages of the disease, so that we can recognise with certainty the occurrence of the liver pulse during the ventricular systole.

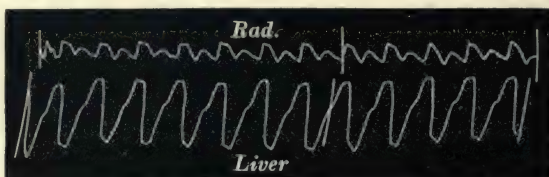


FIG. 256.—Simultaneous tracings of the radial and liver pulses during an attack of paroxysmal tachycardia towards the end of life.

I would have been diffident in making the suggestion that in paroxysmal tachycardia after many hours duration the dilatation of the auricle proceeds so far that the auricle becomes paralysed, were it not that confirmation was found in three other cases. The first time I observed this was some eight years ago, in a lad who had an attack of great rapidity in the heart's action. Prior to the attack I had frequently got a tracing of the venous pulse of the usual auricular form. On taking a tracing of the

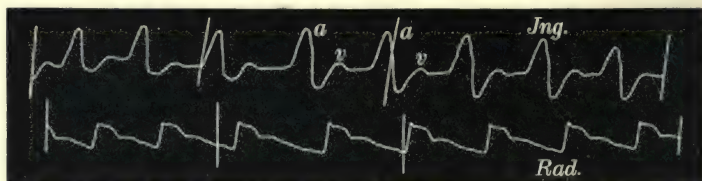


FIG. 257.—Simultaneous tracings of the jugular and radial pulses from a case of paroxysmal tachycardia during the quiet period of the heart's action. There is a well-marked auricular wave, *a*, in the jugular pulse.

movement of the neck I found the venous pulse had a totally different character—the wave in the veins being synchronous with the radial pulse. I put the tracing aside, fancying somehow that I had got a tracing of the carotid pulse. The significance of the observation did not strike me until the case just considered came under my notice. In another case, already described (paroxysmal tachycardia, § 103, case 8), the same peculiarity appeared. In this patient there was occasionally a fair venous pulse when the heart's action was quiet. As will be seen from

Fig. 257, it was of the auricular type, the auricular wave, *a*, being a well-marked feature. I examined him one day during an attack of rapid heart action which had been going on for five or six hours. The pulsation in the neck was identical with that in the case already described, and a tracing of the pulsation in the jugular bulb shows it to be at exactly the same period (Fig. 258); that is to say, one large sudden wave at the same time as the radial pulse—a ventricular venous pulse.

It would therefore seem from the consideration of these facts that during an attack of paroxysmal tachycardia the output of the heart, though quickened, is diminished. The result of this diminished output is, that an increasing amount of blood remains in all the chambers at the end of their




FIG. 258.—Simultaneous tracings of the radial and jugular pulses during an attack of paroxysmal tachycardia. The jugular pulse is due to the ventricular systole, there being now no trace of the auricular waves (from the same patient as Fig. 257).

systole,—that this leads to incompetence of the auriculo-ventricular valves, and through these openings the ventricle forces the blood back into the auricle. The auricle distends so greatly that by and by it ceases to be an effective agent, and thus in the veins and in the liver there appears one large wave of blood synchronous with and due to the ventricular systole, and one large depression synchronous with and due to the ventricular diastole. As this remarkable change may take place in patients free from valvular disease, it forms an exception to the statement that I have previously made—that a ventricular form of pulse in veins or liver only occurred in advanced heart disease consequent on disease of the mitral valves. A similar change in the venous pulse is seen in Figs. 323-327, and the analysis of these tracings in § 237 agrees with the above interpretation. It is to be noted that a liver pulse was not recognised in the second case of paroxysmal tachycardia given above, nor in the patient described in § 237.





## PART III

THE VENOUS AND LIVER PULSES IN IRREGULAR  
ACTION OF THE HEART





## CHAPTER XXV

### IRREGULAR HEART ACTION WHERE THE AURICLES AND VENTRICLES PARTICIPATE IN THE IRREGULAR RHYTHM

§ 212. Graphic records necessary for the interpretation of pulse irregularities.

213. Classification of irregularities.

214. Cases where the auricles and ventricles participate in the irregular rhythm :  
(a) in the youthful type of irregularity ; (b) in the adult type of irregularity with a single premature beat ; (c) during a series of premature contractions ; (d) during persistent bigeminal irregularity.

§ 212. *Graphic records necessary for the interpretation of pulse irregularities.*—To a very great extent the study of pulse irregularities has so far been limited to the action of the left ventricle. Statements in regard to the other cavities have not been wanting, but these for the most part have been the outcome of observations on the movements of the heart, which, without graphic records, are extremely difficult to recognise. Thus the occurrence of such a phenomenon as the right heart acting while the left stood still (hemisystole) has been frequently asserted. The evidence in support of this statement has been based mainly upon the dropping of a pulse beat in the carotid or radial pulse, while the hand, placed over the præcordium, recognised a slight impact during the pause, or the fact that the ear may have recognised faint sounds in the heart during the pause. I have endeavoured to show that these symptoms are not evidence of the cessation of the action of the left ventricle, but point to the occurrence of a small premature contraction of the left ventricle. By means of the liver and venous pulses we can demonstrate with more clearness the participation of the right heart in the different kinds of irregularity.

§ 213. *Classification of irregularities.*—There is a plentiful supply of material for studying the different phases of irregular heart action. It will be convenient here to study them according

as to whether the auricles participate in the irregularity, or whether the irregularity is solely due to ventricular action.

The cases that have come under my observation can be divided into four very clear and distinct groups.

1. Those cases where the auricles and ventricles participate in the irregularity (Chapter XXV.).

2. Those cases where the auricle preserves its rhythm during irregular action of the ventricles (Chapter XXVI.).

3. Those cases where the ventricle fails to respond to the stimulus after the auricular systole (Chapter XXVII.).

4. Those cases where the auricles are paralysed (Chapter XXVIII.).

§ 214. *Cases where the auricles and ventricles participate in the irregular rhythm: (a) in the youthful type of irregularity; (b) in the adult type of irregularity with a single premature beat; (c) during a series of premature contractions; (d) during persistent bigeminal irregularity.*—However the stimulus arises, the natural order of contraction is for the systole to pass like a wave from the auricle to the ventricle. The auricle to a certain extent gives the rhythm to the ventricle. When the auricle deviates from the normal rhythm the ventricle follows. When any departure takes place from this sequence it is because some stimulus has been applied only to the ventricle, so that it contracts before the auricular systole, or remains indifferent to the stimulation proceeding from the auricle.

(a) *In the youthful form of irregularity.*—In the simplest form of irregularity—that which I have described as the youthful form—the auricle always gives the rhythm. This occurs whether

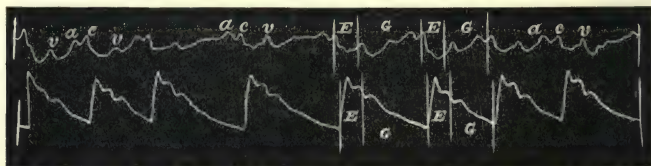


FIG. 259.—Simultaneous tracings of the jugular and radial pulses, showing the agreement in rhythm of the right auricle and ventricle (waves *a* and *v*), with the radial pulse, in the youthful form of irregularity.

the heart is slowing on the approach of puberty (Fig. 259) or after a febrile attack (Fig. 260), or in adults after recovery from an attack of heart failure (Fig. 261). In all these tracings the auricular wave will be found to precede the radial pulse, and to

participate in the same irregular rhythm that is shown by the radial pulse. In some cases we meet with adults whose pulse is very frequently irregular, and where it is at times difficult to tell whether the irregularity is of the adult type or of the

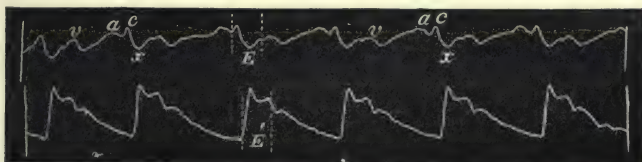


FIG. 260.—Shows the same thing as Fig. 259.

youthful type. Beats with long pauses are present, and occur with beats with pauses of varying duration, some being very short. There may be a doubt whether, during the long pauses, premature contractions may not have taken place where the pulse

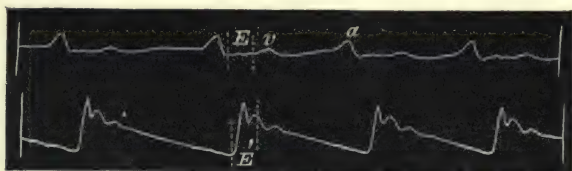


FIG. 261.—Shows the same thing as Fig. 259.

waves caused by these ventricular contractions have not reached the radial artery. In the next two tracings, which are taken from different patients, this peculiarity is well shown. In Fig. 262 the pauses are sometimes long, and usually vary in duration. The




FIG. 262.—Simultaneous tracings of the jugular and radial pulses, showing that the auricle participates in the irregularity, and that there is no premature contraction during the long pauses.

auricular wave of the jugular pulse is found to precede the arterial pulse in every case, and it does not appear during the long pauses. Here one can say with certainty that the auricle has participated in the irregularity, and that there is no missed beat during the pause, as one might incline to think from the



study of the radial pulse alone. The same features are present in Fig. 263. In this radial tracing there is also a slight resemblance to the pulse of the adult type, for one might suspect that there was a missed beat during the long pause of the radial pulse. But it will be seen that the jugular pulse shows that the




FIG. 263.—Shows the same thing as Fig. 212.

auricle contracted with the same irregular rhythm as the radial pulse, and that the irregularity is entirely due to the variation in the length of the diastolic period. Such instances as these, however, are very rare in adults. They both occurred in women in good health. The irregularity in Fig. 263 has been present at times in this patient for ten years to my knowledge.

(b) *In the adult type of irregular pulse with a single premature beat.*—So far the wide separation of events in a cardiac



FIG. 264.—Simultaneous tracings of the jugular pulse and of the radial pulse. The jugular pulse is due to the auricle, and shows the occurrence of a premature auricular wave, *a'*, before the premature beat in the radial.

revolution has left little room for doubt regarding the interpretation of the different waves in the jugular pulse.

When the premature systoles occur early in the diastolic period, the rapid occurrence of the events in the jugular pulse cannot be so easily differenti-

ated. The chief difficulty lies in distinguishing a wave in the jugular preceding the premature wave in the radial or carotid

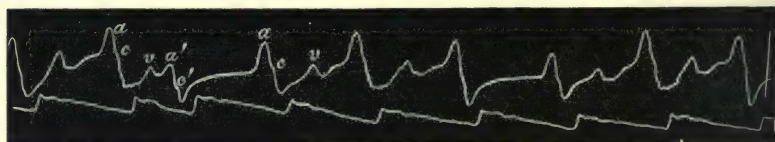


FIG. 265.—Shows the same thing as Fig. 264.

pulse. If the premature systole occurs late, as in Figs. 264 and 265, no difficulty is experienced in recognising that the

wave,  $a'$ , is due to the auricle preceding the premature wave in the radial pulse. But supposing the premature systole occurred a little earlier in the cardiac cycle, the auricular wave,  $a'$ , would merge into the ventricular wave,  $v$ , and we should not know what would be the true nature of that wave. In Fig. 266 the occurrence of a premature auricular wave,  $a'$ , at the time when the ventricular wave,  $v$ , should occur is well seen. The patient from whom this tracing was got had tricuspid stenosis and a hypertrophied right auricle. The auricle sent large waves back with such force that the jugular bulb was distended into a pulsating ball. I have already commented on this case, and Fig. 179, which is a tracing of this pulsation taken at the same time as the carotid, shows that this large wave precedes the carotid pulse, and is undoubtedly auricular in origin. The relative size of the two waves,  $a$  and  $v$ , in the

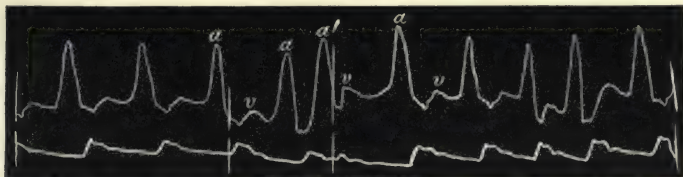


Fig. 266.—Simultaneous tracings of the jugular and radial pulses, showing a large wave ( $a'$ ) due to a premature systole of the auricle, obscuring or taking the place of the ventricular wave  $v$ .

tracing (Fig. 266) leaves no doubt as to the nature of the large wave,  $a'$ , namely, that it is due to a premature systole of the auricle. It follows the preceding auricular wave,  $a$ , at exactly the same period of time that the small premature wave in the radial follows the preceding pulse wave. Hence one can say that the auricle participated in the irregularity shown in the radial pulse, and that the auricular contraction has followed so quickly behind the closure of the semilunar valves that the wave,  $v$ , due to the ventricle is incorporated in the auricular wave,  $a'$ .

It will be remembered that I pointed out that the chief portion of the ventricular wave often occurred immediately after the closure of the semilunar valves. Thus in Fig. 179 the space  $E$  represents the period of outflow from the ventricles. After this has ceased by the closure of the semilunar valves an increase of the wave is seen. Now, when a premature auricular systole occurs, and sends a wave back into the veins exactly at this period, we have but one wave. It is rarely of such size

as in Fig. 266, but usually it is so modified that one can reasonably infer that the auricle has had a share in its production.

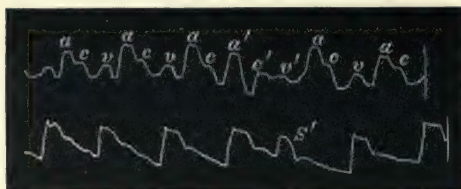


FIG. 267.—Simultaneous tracings of the jugular and radial pulses, showing the participation of the auricle, *a'*, in the irregularity.

Thus in Fig. 267 there is a tracing of the jugular pulse with the radial. A well-marked premature wave, *s'*, is easily recognised in the radial pulse. In the jugular tracing a wave, *a'*, appears, and is much

larger than the ventricular wave, *v*, that occurs at this period of the cardiac cycle in the other portions of the tracing. This large wave, *a'*, is found to follow the preceding auricular wave at exactly the same period that the premature beat in the radial pulse follows the preceding beat. One can reasonably infer from what has just been said that this is a compound wave, made partly of the ventricular wave of the preceding beat and of a premature auricular systole. The auricle here has contracted during the post-sphygmic period of the ventricular systole.

The wave due to the carotid, when it appears in the jugular tracing, may change its character when due to a premature systole. The reason for this is that in most cases the jugular distension is slight. Towards the end of the normal cycle the vein distends, and the auricular wave raises the lever higher. The carotid impact usually occurs when the lever is raised by the full vein, and may only affect the lever very slightly, as in Fig. 264, or cause a mere interruption in the line of descent, as in Fig. 265, when the lever is falling on account of the auricular diastole.

When a premature systole occurs the vein is not so full, the lever is not raised so high, and therefore the carotid pulse figures more prominently in the tracing (see Fig. 196). Thus in Fig. 268 the carotid wave, *c*, is very small. When a premature systole occurs it is more distinct, *c'*. This wave, *c'*, will be found to occur exactly at the same period after *c* that the premature wave, *s'*, in the radial pulse occurs after the preceding pulse wave. The wave between *c* and *c'* in this tracing (Fig. 268) I take to be partly ventricular and partly auricular. It will be found to begin at exactly the same period in the cardiac cycle that the previous ventricular waves, *v*, commenced. But it is more rounded and lasts longer than these. The middle of the



wave is the same distance from the preceding auricular wave, *a*, that the premature pulse wave in the radial is from the preceding pulse. Hence it is evidently made up of a ventricular wave and of the wave arising from a premature systole of the auricle.




FIG. 268.—Simultaneous tracings of the jugular and radial pulses, showing the more pronounced effect of the carotid pulse, *c'*, during the irregular period, on account of the smaller distension of the vein at that period.

It may be pointed out that in all these instances, if the auricle had maintained its rhythm, that an auricular wave would be found at the usual distance, *o*, after the premature systole. As will be seen here, there is no wave at that period.

(*c*) *During a series of premature contractions.*—It is difficult to make out what is happening during such a period. Presumably the auricles participate in the series of rapid beats. Such is the conclusion drawn from the following instance. The patient from whom the tracing Fig. 269 was taken (male, aged fifty-two years) had had occasional irregularities for several years. The irregularity




FIG. 269.—Simultaneous tracings of the jugular and radial pulses during an irregular period, consisting of two premature beats.

was almost invariably due to two premature beats following one another. Very rarely there would be a longer series of premature beats, as in Fig. 270, where there are four premature beats. In Fig. 269 the jugular and radial pulses are taken together. The venous pulse was often very slight, which accounts for the relatively large size of the carotid wave. The waves, *c'*, I take to be the carotid wave during the two premature systoles. Nothing can be inferred from the difference in the sizes, as such variations are dependent very often upon the respiratory movements, which often cause a variation in the filling of the receiver placed over the vein. The wave, *c'*, occurs at times corresponding to the

premature beats in the radial pulse. The wave marked *a'* I take to be due partly to the premature contraction of the auricle, and partly to the wave from the preceding ventricular contraction.

Exactly the same features can be made out in Fig. 270, where there are four premature contractions; the waves between the premature carotid beats, *c'*, are probably compounded of both

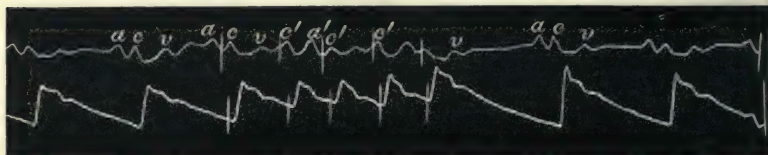


FIG. 270.—Simultaneous tracings of the jugular and radial pulses during an irregular period of four premature beats.

ventricular and auricular waves. While this seems to me the most feasible interpretation, I am not in a position positively to assert the correctness of the interpretation. Another phase of this subject is dealt with in § 237.

(*d*) *During persistent bigeminal irregularity.*—When there is a sufficient interval between the full beat and the premature beat, there is little difficulty in recognising the significance of

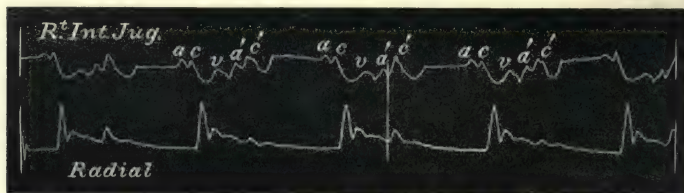


FIG. 271.—Simultaneous tracings of the jugular and radial pulses during bigeminal action of the heart. The auricle, *a'*, participates in the irregularity.

the various waves in the jugular pulse. Thus in Fig. 271 there is a typical pulsus bigeminus with a small but distinct wave in the radial, due to the premature ventricular systole. It corresponds in time to the wave, *c'*, in the jugular tracing, which is undoubtedly due to the premature wave in the carotid. It seems unduly large, but this is due to the fact, already explained, that the jugular being less distended at this period of the cardiac cycle, the tracing of the carotid must become more marked. The wave, *a'*, immediately preceding the carotid wave,

$c'$ , is undoubtedly due to a premature contraction of the auricle. In this tracing we have therefore an illustration of the auricle participating in the rhythm characteristic of the bigeminal pulse. In most of the cases of bigeminal pulse where the auricle takes part in the irregularity, it is very difficult to interpret the tracings with certainty. Thus Fig. 272 shows a typically regular jugular pulse. This patient's pulse would frequently

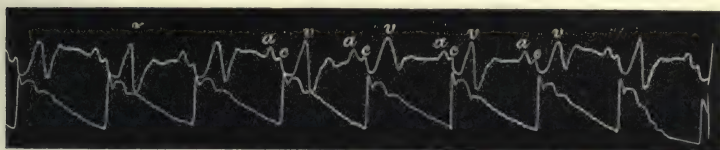


FIG. 272.—Simultaneous tracings of the jugular and radial pulses. The jugular pulse is of the auricular form.

assume the bigeminal form, as in Fig. 273. In taking this tracing one receiver was placed over the carotid under the jaw, and the other over the jugular above the clavicle, and the movements registered on a revolving drum. Here the wave,  $c'$ , coincides in time with the premature beat in the carotid, and is therefore doubtless due to the carotid. The wave,  $v'$ , following the carotid wave,  $c'$ , is, I think, the ventricular wave due to a premature systole of the right ventricle, as it occupies the same

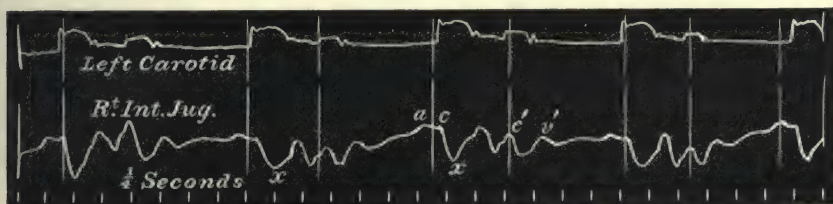


FIG. 273.—Simultaneous tracings of the carotid and jugular pulses during bigeminal action of the heart.

time relation in regard to the carotid wave,  $c'$ , as the ventricular wave,  $v$ , bears to the carotid wave,  $c$ , in Fig. 272. I am unable to say whether the large wave between  $c$  and  $c'$  is a compound wave, partly due to the ventricular wave or to a premature auricular systole. It may be that the slight wave in the ascending limb of  $c'$  is really the auricular wave. That this is really an instance of the auricle participating in the irregular rhythm will be readily inferred after considering similar pulse irregularities when the auricle preserves its rhythm. †



## CHAPTER XXVI

### IRREGULAR HEART ACTION WHERE THE AURICLE RETAINS ITS RHYTHM DURING VENTRICULAR IRREGULARITY

- § 215. Cases in which this form of irregularity occurs : (a) with a single premature beat ; (b) during persistent bigeminal irregularity.
216. Duration of the irregular period.
217. The jugular pulse in slow action of the heart.
218. The absence of the ventricular wave in the jugular pulse when the auricle maintains its rhythm.

§ 215. *Cases in which this form of irregularity occurs : (a) with a single premature beat ; (b) during persistent bigeminal irregularity.*—(a) When there is only an occasional bigeminal irregularity it is easy to understand how the idea arose that the right heart acted when the left stood still, when we examine some of those cases. The pulse would often be felt to miss a beat, and when the eye was kept on the jugular vein, it could be readily seen that during this long pause there was a very large beat in the vein. As the pulse in the vein was vaguely put down to the ventricular systole, the idea naturally arose that there was here evidence that the right heart beat when the left stood still. In Fig. 274 we have an excellent illustration of this. The patient from whom this tracing was got had a frequent pause in the radial pulse. At times these pauses would appear after every second beat, so that for a few seconds the pulse would be at half the ordinary rate. I tried repeatedly to get a tracing during this period, but as often happens in these cases, it would not occur until I had used up all my tracing papers and had taken off the instrument. I had, therefore, to be contented with the occasional irregularities, as in the figure. Here it will be noted that the jugular tracing consists of the two waves, *a* and *c*, the one due to the auricular

contraction and the other due to the carotid impact. During the pause in the radial pulse the venous pulse continues, but there is present only the one wave,  $a'$ , due to the auricle. The wave,  $c$ , due to the carotid is absent, because at that time, as in the radial pulse, there was a beat missed in the carotid pulse. If the position of the waves,  $a'$ , be measured they will be found to

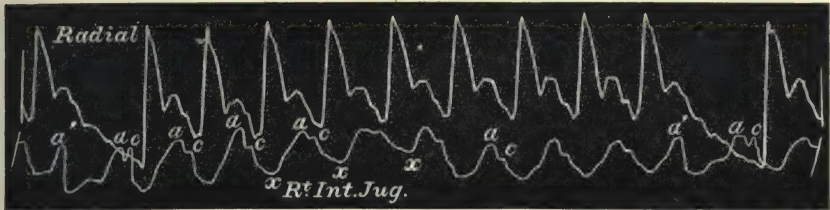


FIG. 274.—Simultaneous tracings of the radial and jugular pulses. The wave,  $a$ , in the jugular pulse is due to the auricular systole, and preserves its rhythm,  $a'$ , during the irregular period in the radial.

appear at regular intervals with the waves marked  $a$  during the period of manifest irregularity in the radial pulse.

In Fig. 275 we have a very similar state of affairs. There is an occasional missed beat in the radial pulse. During that interval the jugular pulse continues its rhythm. Thus the large wave,  $a'$ , appears at exactly the same interval as the other auricular waves,  $a$ . It is certainly much larger than the other

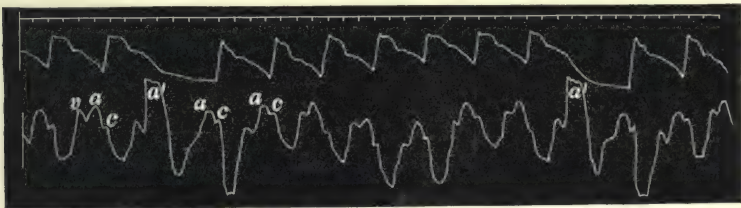


FIG. 275.—Shows the same thing as Fig. 274.

auricular waves, but this is a character common to nearly all these cases, and I shall explain its probable origin later. Suffice it here to point out that the auricle preserves its rhythm during an irregular period of the heart's action.

In these two tracings there is a total absence in the radial pulse of the wave due to the early systole. That it took place may be inferred from the fact that slight undulations are seen in the radial tracing of Fig. 274. In the patient from whom I

obtained Fig. 275 the ventricular contraction was so feeble that sometimes there was absolute silence during the pause, while at other times the short sharp sounds could be heard.

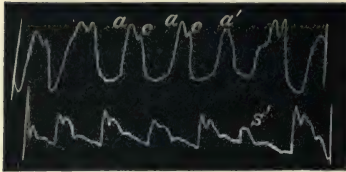


FIG. 276.—Shows the same thing as the two preceding tracings, except that there is a well-marked premature beat, *s'*, during the irregular period.

In Fig. 276 there is a well marked premature wave in the radial pulse. In the jugular tracing the auricular waves, *a* and *a'*, occur with perfect regularity. The carotid wave corresponding to the premature radial pulse beat is absent, because the time of its

occurrence is almost identical with the auricular wave, *a'*, and it is masked by this large wave in the jugular.

In the case from which the next two tracings were taken there was always a well-marked wave in the radial pulse, due to the early systole of the ventricle, and there could readily be heard the two sounds accompanying the early systole, as is illustrated in Fig. 67.

Fig. 277 gives the venous pulse during a regular period of




FIG. 277.—Simultaneous tracings of the jugular and radial pulses.

the heart's action. The pulse in this case was usually quite regular, but at intervals during the last six years I have found it irregular, as in Fig. 278. From Fig. 277 it will be seen that the pulse is a good example of the auricular form of the venous pulse. The same features are present during the regular beats in Fig. 278. But when an early systole occurs we find that the wave, *a'*, due to the auricle, occurs at the usual auricular interval, but is of much greater size and is not followed by a ventricular wave. That the wave was really in the vein could easily be determined by watching the vein. Every time a premature feeble beat occurred in the radial artery, the vein suddenly distended much greater than usual. We can see here the cause of the greater size of the vein during this period. It will be



found on careful measurement that this auricular wave,  $a'$ , occurs at exactly the same time as the radial pulse. In fact, when the auricle contracts there is no exit for the blood through the auriculo-ventricular orifice, as the ventricle at that time is also in systole. Therefore a much bigger wave is sent back into the

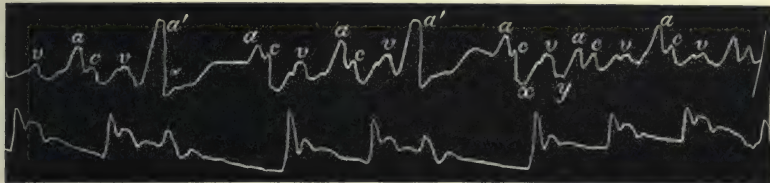


FIG. 278.—Simultaneous tracings of the jugular and radial pulses, showing that the auricle preserves its rhythm,  $a'$ , during the irregular period in the radial pulse.

veins. The ventricle here has been stimulated to contract before it receives the impulse from the auricle.

This greater size of the auricular wave during the occurrence of an early systole is present in most of the tracings. Thus in another case where there was a well marked apex beat, the tracing Fig. 279 was obtained. Here the premature systole is shown by the smaller apex beat,  $O$ ; the large wave in the venous pulse,  $a'$ ,

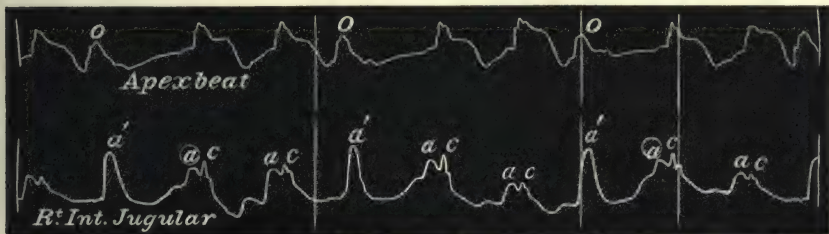


FIG. 279.—Simultaneous tracings of the apex beat and of the jugular pulse, showing the rhythmical appearance of the auricular wave during the irregular periods in the apex tracing.

occurs at the same time as this premature ventricular systole. Fig. 69 is the sphygmogram from this case, showing a fair-sized beat, due to the early occurring systole.

The same large wave, due to the auricular systole during the occurrence of an early ventricular systole, can be made out in the liver tracing Fig. 280. Irregularities are extremely rare in cases presenting a liver pulse of the auricular type, for a possible reason, to be given later (§ 234). In one case I found at intervals of sixty or seventy beats a pulse of the bigeminal form (Fig. 61). I tried over and over again to catch the irregularity,

while getting a record of the liver pulse. At last I succeeded, but unfortunately the tracing is not so good as in Fig. 183,

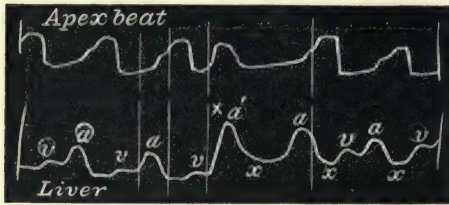


FIG. 280.—Simultaneous tracings of the apex beat and of the liver pulse, showing the rhythmical contraction of the auricle,  $a'$ , during an irregular period in the apex tracing.

taken at the same visit from the same patient. Still, the features of the liver pulse are readily recognisable, and here we again find the persistence of the auricular rhythm during an irregularity in the ventricular contraction. And as in the other instances, the

wave,  $a'$ , is much larger than the usual auricular waves, and there is a total absence of the ventricular wave.

(b) *During persistent bigeminal irregularity.*—In these cases the jugular tracing differs in appearance from those in which the auricle participates in the irregular rhythm, inasmuch as the auricular wave, occurring at the same time as the premature contraction of the ventricle, is of large size. In Fig. 281 the




FIG. 281.—Simultaneous tracings of the radial and jugular pulses, while the left ventricle contracts irregularly (pulsus bigeminus) the auricle ( $a$  and  $a'$ ) contracts regularly;  $a'$  is the large wave due to the auricular systole that occurs at the same time as the premature ventricular systole.

tracing of the radial pulse is not very good, but it shows the character of the irregularity very well. In the accompanying jugular pulse, the auricular waves,  $a$  and  $a'$ , are seen to occur at regular intervals. The waves,  $a'$ , are large, because at that period the ventricle is in systole, and as no blood can escape into the ventricle a larger wave is sent back into the veins by the contracting auricle. It should be borne in mind in studying these tracings that the radial pulse occurs a little later than the carotid. Hence in the jugular tracing there is no evidence of the carotid, because at the time of its occurrence the large wave appeared in the vein and obscured the carotid movement.

In the patient from whom this tracing was got the pulse

often presented a variation in the rhythm. Sometimes it would be quite regular, and again it would present the bigeminal form. When it presented this bigeminal form the period at which the premature systole appeared would vary slightly. In Fig. 281 it appeared at regular intervals, just at the time the auricular wave,  $a'$ , appeared in the veins. In Fig. 282, from the same patient,

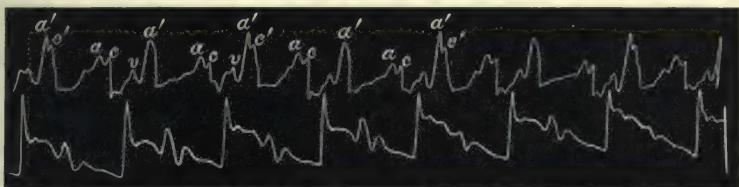


FIG. 282.—Simultaneous tracings of the jugular and radial pulses. On every second large auricular wave,  $a'$ , is the small wave,  $c'$ , due to the premature carotid beat. If the time of the occurrence of the premature radial pulse be measured it will be found to be slightly later every second beat when the wave,  $c'$ , is present.

the jugular tracing shows a curious variation. It will be noted that every second wave marked  $a'$  is followed by a wave,  $c'$ . When there is no wave,  $c'$ , present, the jugular pulse is practically the same as in Fig. 281. If the radial tracing be carefully measured it will be found that the premature systole appears slightly later in every second beat, measuring from the beginning of the preceding full beat. When this occurs the wave,  $c'$ , is

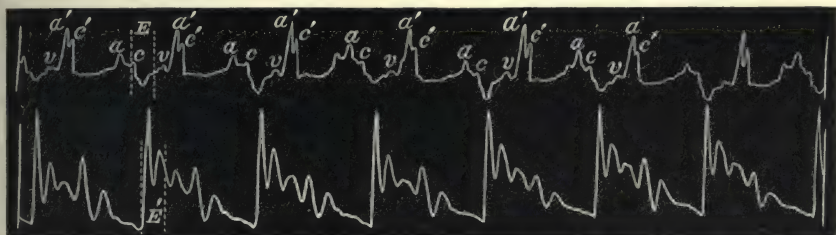


FIG. 283.—Shows the same as Fig. 282, except that the carotid wave,  $c'$ , is present on every larger auricular wave,  $a'$ .

present in the jugular tracing. In other words, when the premature systole appears earlier, the carotid pulse is masked by the large auricular wave,  $a'$ . When the premature systole appears a little later, the carotid pulse is later than the jugular wave, and its presence is signified by the slight wave,  $c'$ , in the large auricular wave,  $a'$ . At other periods this wave,  $c'$ , would be a constant phenomenon, as in Fig. 283. In Fig. 284 the radial pulse passes into a regular form for three beats, and the venous



pulse likewise alters. It will be noted that in the irregular period preceding these regular beats the carotid wave,  $c'$ , is present, while in the last beat in the tracing which is irregular the carotid wave is not present on the wave,  $a'$ . If the distance of the premature beat in the radial pulse from the preceding beat be measured, it will be found to be slightly less in the last irregular period than in the other irregular periods.

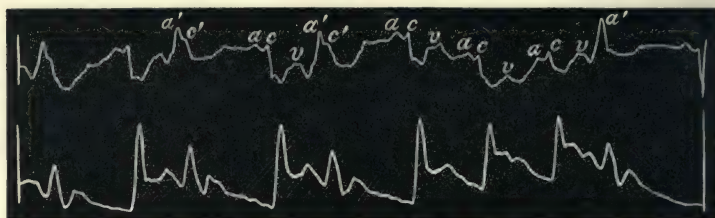


FIG. 284.—Simultaneous tracings of the jugular and radial pulses. The radial rhythm becomes regular for three beats.

§ 216. *Duration of the irregular period.*—If the auricle maintains its rhythm during an irregular period, and if there is but one premature beat in the arterial pulse, the period will naturally be of the same duration as two full regular beats. Thus in Figs. 274, 279, and 280 the irregular periods correspond closely to two regular periods. There is a tendency at times, however, for the auricle to vary slightly during the irregular




FIG. 285.—Simultaneous tracings of the jugular and radial pulse, showing a progressive shortening of the last two irregular periods in the radial and an earlier occurrence of the last auricular wave,  $a$ .

period; thus in Figs. 275 and 278 the first irregular period in both cases is distinctly longer than the latter irregular period or than two regular beats. A marked shortening of the period is seen in Fig. 285. This tracing is from the same patient as Fig. 275. In her an occasional irregularity of the pulse was a very common feature, and I have tracings extending over a period of seven years. Sometimes there would be a small wave in the radial corresponding to the premature systole, sometimes there would

be none. At rare intervals the irregularity would persist for three or four beats. When the irregularity was single, as in Fig. 275, it invariably occupied a period nearly corresponding to two beats, even when there was no trace of the premature beat in the radial. In the tracing Fig. 285 there are three irregular periods following one another, and it will be noted that the latter two periods are distinctly shorter than two full beats at the beginning of the tracings. This is due to the earlier occurrence of the auricular systole, *a*, after the irregular period. Thus the distance from the wave *a'* to the wave *a*, during the last irregular period, is markedly shortened. Exactly the same thing is seen in Figs. 320 and 321, where the auricle has maintained its rhythm while the ventricle prematurely contracted, yet the succeeding auricular wave occurs earlier, as if to accommodate itself to the ventricular rhythm.




FIG. 286.—Simultaneous tracings of the radial and jugular pulses. The auricle participates in the irregularity, and the irregular period equals two pulse beats, *a'* wave due to the premature auricular systole, *c'* wave due to premature carotid beat, *v'* wave due to premature contraction of the right ventricle.

Apart from such exceptions, it may be laid down as a general rule that when an irregularity is due to the occurrence of a premature systole originating with the ventricle, that the irregular period occupies the same time as two regular periods. If it occupies a longer period, the irregularity is also likely to be of ventricular origin. When an irregularity is due to the premature contraction of the auricle the irregular period is usually less than two regular beats. Thus in Figs. 264 and 266 the irregular period is distinctly smaller than two regular beats. The pause after the premature systole is rarely so long as after a premature systole of ventricular origin. In these tracings the diastolic period after the premature systole is practically of the same length as the diastolic period following a regular contraction. I have found an exception to this when the premature systole is of fair size, and occurs rather late, as in Fig. 286. In this tracing the premature beat is of large size, and there is a fair interval between it and the preceding beat. The features of the

jugular pulse are readily discernible, and the auricular wave, *a'*, is evidently due to premature contraction of the auricle. The diastolic period after the premature contraction is distinctly prolonged, so that the whole irregular period corresponds to double the length of the preceding full beat. This also is an exceptional circumstance, as far as my experience goes. It may therefore be laid down as a general rule that when an irregularity is due to the premature contraction of the auricle, the irregular period occupies less than two regular beats.

§ 217. *The jugular pulse in slow action of the heart.*—Before leaving the subject of pulse irregularities due to premature systole, I may point out the further usefulness of the venous pulse in determining the character of certain irregularities, particularly when there is a long pause. I have already shown how it explains the long pause in such tracings as Figs. 262,




FIG. 287.—A bigeminal pulse.

263, 274, and 275, and also the character of the slow pulse in Fig. 199. In the following instance, were it not for its help, a totally wrong view would be taken of the nature of the irregularity. This patient, a female aged forty-one, has been under observation for over ten years. During that period her pulse has very frequently been irregular. For months at a time



FIG. 288.—From the same patient as Fig. 287, showing the frequent absence of the premature beat.

it would be of the bigeminal form, as in Fig. 287. Occasionally it would vary in its rhythm during an examination, sometimes being regular, as in Fig. 272, sometimes beating very slowly, as in Fig. 288. In considering the nature of the irregularity in Fig. 288, it will be found that the single slow pulse beat occupies the same period as an irregular period (two beats) in Fig. 287. One would, therefore, naturally conclude that the ventricle had contracted during the long pause in Fig. 288, but



that the contraction was not of sufficient strength to produce a radial pulse. One would be all the more inclined to this view when there is observed an occasional premature pulse wave during the long pause, as in the Fig. 288. Such, indeed, was the view I took of the matter, till one day while taking a venous tracing the heart again took the form of irregular rhythm—a slow pulse with an occasional premature systole (Fig. 289).




FIG. 289.—Simultaneous tracings of the jugular and radial pulses, showing that no premature beat occurred during the long pause in the radial pulse. From the same patient as Figs. 287 and 288.

Here it will be seen that during the long pause in the radial pulse there is no sign whatever of a movement in the jugular, showing that during the pause the chambers of the heart did not contract. But when a premature systole occurred in the left ventricle, indicated by the small radial pulse, the right auricle and ventricle also contracted (Figs. 272 and 273 are from the same patient).

§ 218. *The absence of the ventricular wave in the jugular pulse when the auricle maintains its rhythm.*—Another means of distinguishing the irregularities due to the auricle from those due to the ventricle by observing the venous pulse, is to be found in the presence or absence of the ventricular wave after the premature beat. In all the tracings with premature beats of the radial illustrating a corresponding irregular rhythm of the auricle (Figs. 266, 267, 268, 269), the ventricular wave, *v*, is present, with the exception of Fig. 265. Here the wave is missed on account of the hardening of the sterno-mastoid muscle during inspiration, which prevented the lever accurately following the movements in the vein. The same obscuring of the venous movements is seen in the following fourth beat. In every other case the ventricular wave can be recognised. Its origin is, of course, the same as that already described, namely, due to a backward flow after the auricle has been filled by the ventricular systole. On the other hand, when the ventricle has originated the irregularity while the auricle maintained its rhythm, there is never found a ventricular wave. In the tracings of this

irregularity, as Figs. 278 and 280, there is a blank after the large auricular wave at the time the ventricular wave should have occurred. In the other tracings showing this form of irregularity there is no distinct ventricular wave during the regular period, so that its absence during the irregularity is not so significant. The reason for its absence in Figs. 278 and 280 is that the auricle and ventricle contracting practically at the same time, no backward flow of blood can take place into the auricle during the ventricular systole, and therefore no ventricular wave can appear, and at the period corresponding to the time that the ventricular wave should appear the auricle has just passed into diastole, and is able to absorb all the blood. It is the presence of this wave in such a tracing as Fig. 273 that makes one assured that the auricle has participated in the irregularity.

## CHAPTER XXVII

### IRREGULAR HEART ACTION WHERE THE VENTRICLE FAILS TO RESPOND TO THE STIMULUS AFTER THE AURICULAR SYSTOLE

- § 219. Illustrative case.  
220. Explanation of the phenomenon.  
221. The ventricles acted together.  
222. Did the auricles act together?

§ 219. *Illustrative case.*—I have only had a few cases where this peculiarity occurred. Unfortunately in most of them the venous pulse was not well marked, and I had to be content with the faintest evidence of the auricular movement.

I have already pointed out that when there is but a faint pulse in the veins, all that we can recognise is a small wave




FIG. 290.—Tracings of the pulsation in the neck due to a wave, *a*, in the jugular vein and the carotid pulse, *c*, taken at the same time as the radial. There are two auricular waves, *a*, to one carotid pulse.

immediately preceding the arterial pulse, as in Fig. 261. In Fig. 290 the carotid pulse, *c*, is immediately preceded by a wave, *a*, which from its position in the cardiac cycle is undoubtedly auricular in origin. The patient from whom this was got was a ruddy-faced elderly man, sixty-six years of age. He felt in fair health, and was capable of considerable exertion. There was some albumin in the urine. The heart's dulness could not be accurately made out on account of the voluminous lungs.



The rate of the heart varied remarkably. Some days it would be about forty-two per minute, on other days it would vary from twenty-three to thirty-five. The movements in the veins, though slight, were readily visible. These always appeared much more numerous than the carotid or radial pulse—two or three jugular pulsations to one radial. There was always present a systolic mitral murmur, and occasionally during a long pause one could detect a slight whiff, which evidently corresponded in time with one of the waves in the veins that I have suggested are due to the auricle. The pulse had shown this peculiar rhythm for over two years. Imperfect as the tracings are, they still show some facts of the most curious kind. Fig. 290 shows, as I have said, the auricular wave, *a*, immediately preceding the carotid wave. In all the tracings the carotid wave is large. The tracings of the pulse in the neck are often affected by the




FIG. 291.—Shows the same as Fig. 290, except that there is a delay before the carotid pulse, *c*, appears after the auricular wave, *a*.

carotid pulse. When the venous distension is slight, as in this case, then the pulse in the veins cannot be got without including the carotid pulse in the tracing, because the vein lies by the side of the carotid. But the presence of the carotid here is fortunate as demonstrating its relation to the movements in the vein. Fig. 291 is another tracing from the same patient. It shows the same features as Fig. 290, with this important exception—the wave, *a*, is always farther from the carotid pulse. In Fig. 290 the carotid pulse follows immediately on the auricular wave. In Fig. 291 there is a distinct interval. While one felt the pulse one could perceive that the rate altered from time to time. Thus in Fig. 292 the first two beats of the radial pulse are much slower than the last two. If the tracing representing the carotid and jugular pulse be studied, a curious condition is found. There are actually three small waves, *a*, to one carotid pulse in the one case, and only two small waves in the other. It will be found, however, that the auricular waves, *a*, are all equally separated the one from the other. It will also

be noted that while the auricular wave, *a*, preceding the third carotid beat, *c*, in the tracing (Fig. 292) is immediately followed by the carotid pulse, the wave, *a*, preceding the next carotid beat is followed at a short distance by the carotid beat. On another occasion the pulse rate fell to twenty-eight, and the three auricular waves to the one pulse beat are constant (Fig.




FIG. 292.—Shows the same as the two preceding tracings. Here the rate of the carotid, *c*, and of the radial varies, so that there is sometimes two and sometimes three auricular waves, *a*, for one pulse beat in the carotid, *c*; or radial. The auricular waves, *a*, preceding the carotid are separated from the carotid by varying intervals.

293). The waves are larger here. The size of the venous pulse used to vary—sometimes large as here, sometimes it disappeared altogether. The wave, *a*, that immediately follows the carotid pulse in this tracing I have assumed to be auricular, because it occurs at the same interval as the other auricular waves, and its presence completes the regular rhythm of the auricle. The only other thing it might be is the dicrotic wave of the carotid pulse; but this wave, as is well seen in the radial pulse, is of a




FIG. 293.—Shows the same as the three preceding tracings. The pulse rate was twenty-eight per minute, and there are three auricular waves to one carotid or radial pulse. The jugular pulse was larger when this tracing was taken.

small size, and on careful measurement is found to occur earlier in the cycle. Further, the wave, *a*, has a variable relation to the carotid pulse when it follows this pulse. Thus in Fig. 292 it follows the carotid wave at a distinct interval after the third beat, because the wave, *a*, preceding that carotid pulse is close to the carotid wave. The wave, *a*, follows immediately on the fourth carotid pulse, because the wave, *a*, preceding that beat is some distance in front of it. The rhythm of the auricle is preserved, whatever the period at which the ventricle contracts.

The complete discordance between the auricular and ventricular rhythm is well illustrated in Fig 294. It will be seen that the first carotid wave is preceded at a brief interval by an auricular wave, *a*, while the second carotid wave is preceded at a

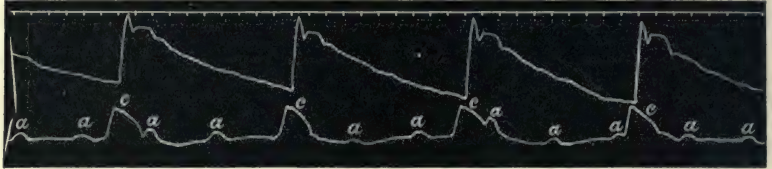

FIG. 294.—Shows the complete dissociation of the auricular wave, *a*, from the carotid pulse.

much longer interval by the auricular wave, *a*. Here in fact the carotid pulse occurs at the same period that the auricular wave was due. The auricular wave evidently did appear because its rhythm continues unaltered, but it is masked by the larger carotid wave, the apparatus only recording the larger movement.

§ 220. *Explanation of the phenomenon.*—The explanation that commends itself to my judgment is that the auricle maintains its rhythm, but the ventricle does not respond to the beat of the auricle. There is evidently a deadening of the irritability of the ventricle. This is not only evident from the ventricle failing to respond to the auricular rhythm, but also from the fact that the ventricular systole occurs at times at a distinct interval after the auricular systole, and again actually during the auricular systole. One explanation might be, that in this case the ventricle did really contract, but that the wave was not propagated to the radial or carotid pulse. While I have no direct evidence to advance against this proposition, I would point out the demonstrable fact of the ventricle contracting at independent intervals shows that it has a rhythm of its own, only occasionally yielding to the stimulus that succeeds the auricular contraction. It might be suggested that the occasional presence of a faint bruit during the pause of the arterial pulse might be due to an imperfect ventricular systole, but I am more inclined to the view that it was due to an auricular systole, and that probably there is here stenosis of the mitral orifice. The character of the murmur was different from those already described (§ 179). In the cases there described where a systolic murmur was present, the murmur during the premature systole began abruptly with the first sound and ended abruptly with



the second. In this case there was only a soft bruit, with no semblance to the usual sounds of the heart. The large character of the ventricular wave in the sphygmogram of the radial pulse also indicates a longer ventricular contraction than one would expect if there had been premature contractions between the pulse beats.

§ 221. *The ventricles acted together.*—An additional argument in favour of the interpretation I have suggested—namely, that the auricles contracted regularly and more frequently than the ventricles—is to be found in the study of the movements of the right ventricle. In this case there was a total absence of the ventricular wave in the venous pulse, even when it was of large size, as in Fig. 293. But there was in this patient a remarkable indrawing of the epigastrium with each pulse beat. I have already pointed out (§ 28) that the right ventricular systole, when it affects the

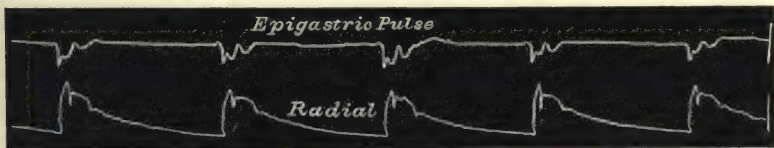


FIG. 295.—Simultaneous tracings of the epigastric pulsations and of the radial pulse. The epigastric pulse tracing shows an indrawing during systole due to the contraction of the right ventricle. The right and left ventricles therefore act in harmony.

epigastrium, causes a sinking-in during the emptying of the ventricle. In Fig. 295 a tracing of this epigastric movement is taken at the same time as the radial pulse, and it shows a depression coincident with each pulse beat. As this depression is due to the systole of the right ventricle, in this tracing we have evidence that both ventricles acted in harmony. We can further surmise that there was no premature contraction of the ventricles, as, if such were the case, there would have been evidence of it in the epigastric tracing.

§ 222. *Did the auricles act together?*—From the cases that have come under my observation I have not been able to get evidence of what the left auricle was doing. But Chauveau<sup>53</sup> has described a case that bears a striking resemblance to the one I have just described. While the radial pulse was beating at the rate of twenty-four per minute, there was a pulsation in the jugular vein at the rate of from sixty to sixty-four per minute. He obtained tracings of the apex beat, and while there were large

beats due to the ventricular systole, and which corresponded in time with the radial pulse, there were more numerous small elevations that corresponded in time with the jugular pulse, and which he interpreted as being due to the left auricle contracting and distending the left ventricle. From the study of his tracings, and from their resemblance to the tracings I have given, I am also of his opinion, so that in all probability in all these cases the auricles have the same rhythm.

## CHAPTER XXVIII

### IRREGULAR HEART ACTION WITH PARALYSIS OF THE AURICLE

§ 223. Varied forms of pulse irregularity.

224. Agreement in rhythm of both ventricles.

225. Bigeminal pulsation in the pulmonary artery.

(All the tracings in this chapter are from patients suffering from advanced mitral disease)

§ 223. *Varied forms of pulse irregularity.*—The chief points connected with the pulse in cases of advanced mitral disease that strike the observer are the great variations in the rate and rhythm. The type of irregularity is most varied. There may be only the occasional occurrence of a premature beat, or the premature beat may occur regularly after each full beat. Sometimes in the latter case the premature beat may be scarcely perceptible in the radial pulse (Fig. 80), or it may even be altogether absent (Figs. 81, 300, and 304). When absent the pulse then appears abnormally slow, and it is only by observing other signs of the heart movement that we can determine the nature of the slow pulse. But the heart may actually become very slow in advanced mitral disease, and the resulting slow pulse is not then due to a dropped beat (Fig. 305). The individual pulse beats may show a great variation in size and character even within the limits of a short tracing. Thus in Fig. 296 there are two small beats, x and x. They can scarcely be called premature beats, for the distance that separates them from the preceding full beat is not greater than the distance between some of the other full beats. Nor are they followed by a lengthened pause. Even when the beats follow one another with increased rapidity the systolic period may not be shortened, as in Fig 298. The radial tracing here resembles the youthful type of irregularity. From such con-



siderations as these, while it can be asserted that no definite characteristic can be assigned to the pulse after auricular paralysis, it is nevertheless readily seen that the irregularities are extremely common and of the most varied description.

§ 224. *Agreement in rhythm of both ventricles.*—The ventricles almost invariably contract together. In only a few instances have I found evidence of their separate or independent contractions, and with one exception the heart was dying when the arrhythmia occurred.




FIG. 296.—Simultaneous tracings of the jugular and radial pulses. The jugular pulse is of the ventricular type, and the tracing shows complete agreement in rhythm between the right and left ventricles.

Fig. 296 is a tracing of the venous pulse of the ventricular type taken at the same time as the radial pulse. The irregularities are of the most varied forms, but both ventricles act in perfect harmony. One curious feature is the constancy in the size of the venous pulse wave, as compared with the duration of the radial pulse. At x and x the radial pulse beat is very minute, while the corresponding venous pulse wave is of the same



FIG. 297.—Simultaneous tracings of the jugular and radial pulses, showing the harmony in rhythm between the two ventricles when the irregularity consists of premature beats occurring singly and in groups. The jugular pulse is of the ventricular form.

size as the wave preceding and following it. The reason for this is, that the force opposing the contraction of the left ventricle (the aortic pressure) was so great that the ventricular contraction was barely able to overcome it. On the other hand, the force opposing the contraction of the right ventricle (pressure in the great veins) was so slight that even a weakened ventricular contraction had no difficulty in overcoming it. This is a character common to all the forms of irregularity in paralysis of the auricle,

viz., the size of the venous pulse does not vary in the same proportion as the size of the arterial pulse (see § 176).

Fig. 297 is from another patient, and shows a venous pulse due to the right ventricle, taken at the same time as the radial pulse. The radial pulse represents premature systoles singly and

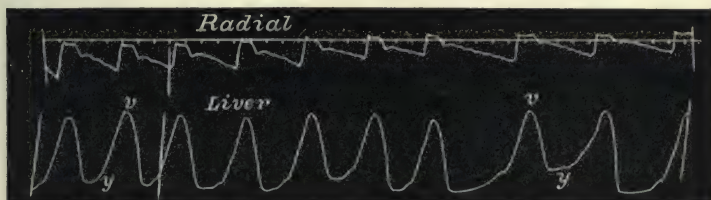


FIG. 298.—Simultaneous tracings of the radial and liver pulses. The liver pulse is of the ventricular form.

in groups, with an exact correspondence in time of the venous pulse. The same correspondence is manifested in tracings of the liver pulse. In Fig. 298 the radial and liver pulses are shown to be exactly synchronous in all the irregularities present.

When dealing with a slow pulse due to a missed beat (§ 109) I showed that the apex beat due to the premature systole was often present when there was little or no indication

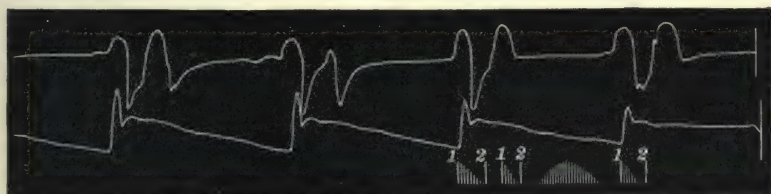


FIG. 299.—Simultaneous tracings of the apex beat and radial pulse, showing a premature systole of the left ventricle, which is unrepresented in the radial pulse.

in the radial or carotid pulse. If in suitable cases we can get a tracing either of the venous or the liver pulses, it will be found that the second wave is always very distinct. In Fig. 299 the apex beat and the radial pulse are taken together. During the pause there is a well marked premature systole in the apex tracing, while there is no indication of anything happening in the radial pulse. At the same visit Fig. 300 was taken, and here there is shown a well marked premature systole of the right ventricle, causing the second of the linked beats in

the liver pulse. In the liver pulse of another patient (Fig. 301) the same events are shown, and in the radial pulse there are certain undulations which may indicate that a contraction




FIG. 300.—Simultaneous tracings of the liver and radial pulses, showing that the right ventricle (the liver pulse) prematurely contracts, causing the second of the linked beats in the liver pulse, and corresponds in rhythm with the apex beat in Fig. 299.

of the ventricle had taken place, although not of sufficient strength to propagate a pulse wave perceptible to the finger, or even to create a distinct wave in the tracing. The correspondence in the sounds and murmur in such cases has already been




FIG. 301.—Shows the same thing as Fig. 300.

commented upon (§ 179). In a third patient, who presented exactly the same form of irregularity, viz. two liver and venous pulses to one radial pulse (as in Fig. 302), I obtained a good tracing of the liver and apex beat at the same time (Fig. 303).

In this tracing (Fig. 303) the harmony of rhythm between



FIG. 302.—Simultaneous tracings of the liver and radial pulses, showing a double pulse in the liver preceding the long pause, and a single pulse preceding the short pause in the radial pulse.

the two ventricles is well illustrated. When there are two beats of the left ventricle (apex beat), there are two beats of the liver pulse (right ventricle). Similarly, the solitary beats appear in both tracings. The sounds and murmurs heard are diagrammatically represented in the tracing. Fig. 304 is a tracing of the radial pulse, taken at the same visit, and shows a very slow



pulse with an occasional short beat. The slow pulse of mitral disease is very often of this nature—in reality a pulsus bigeminus, where the premature beat scarcely reaches the radial pulse. But it must not be assumed that all slow pulses are of this character.

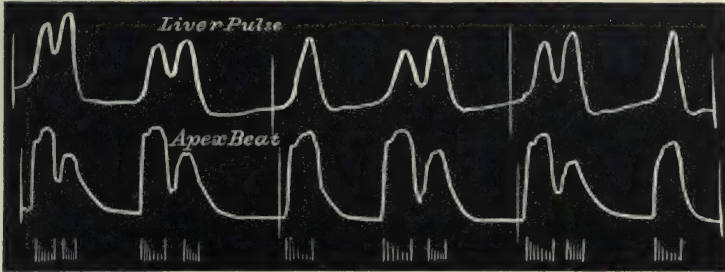


FIG. 303.—Simultaneous tracings of the liver pulse and apex beat, showing complete harmony in the rhythm of both ventricles. The sounds and murmurs present are diagrammatically represented.

Thus Fig. 305 was taken from the same patient as gave Fig. 296 thirteen days later, during which time the heart had come under the influence of digitalis. Fig. 218 was got from the same patient shortly before her death. In Figs. 305 and 218




FIG. 304.—Tracing of a slow pulse, whose real nature is revealed by the two preceding figures.\*

the pulse is very slow, but the venous pulse testifies in Fig. 305 that there was no dropped beat in the radial pulse, and during the pause in the pulse the heart was silent, but the apex beat shows that there was a dropped beat when Fig. 218 was taken.



FIG. 305.—Simultaneous tracings of the jugular and radial pulses, showing a slow pulse with only one beat of the right ventricle, in contrast to the slow pulse of the same patient in Fig. 218.

§ 225. *Bigeminal pulsation in the pulmonary artery.*—So far the study of the right heart has been by means of the backward flow of blood from the right ventricle. In Fig. 306 I am able to show a unique tracing of the pulsus bigeminus of the pulmonary artery. The tracing was taken from the second

left interspace near the sternum. In the first part of the tracing the pulse in the pulmonary artery is inscribed at the same time as the radial pulse. In the latter part of the tracing the carotid

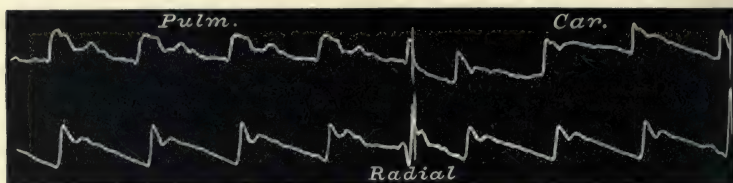


FIG. 306.—Simultaneous tracings of the pulse in the pulmonary artery and radial pulse, and of the carotid and radial pulses. Showing the presence of the bigeminal pulse in the pulmonary artery.

and radial are taken together. In Fig. 307 the apex beat and the radial pulse were taken immediately before Fig. 306. The double apex beat here shows that there were two beats of the




FIG. 307.—Simultaneous tracings of the apex beat and radial pulse, showing two beats of the apex to one radial pulse.

left ventricle for one in the radial. A suspicion of the premature beat may be found in some of the radial and carotid beats, but it is well marked in the pulse of the pulmonary artery.

## CHAPTER XXIX

### IRREGULAR HEART ACTION WHERE THERE IS DISCORD- ANCE OF THE RIGHT AND LEFT CHAMBERS OF THE HEART (HEMISYSTOLE)

- § 226. Hemisystole a rare symptom.
- 227. Hemisystole with the auricles active.
- 228. Hemisystole with the auricles paralysed.

§ 226. *Hemisystole a rare symptom.*—It has long been a subject for discussion whether it is possible for one half of the heart to contract while the other stands still. On the one hand, clinical observers have been found who have not hesitated to assert that they have seen, heard, and felt the two sides of the heart contract independently; on the other hand, it has been as positively asserted that such discordance is incompatible with life. It is very doubtful if the evidence on which many clinical observations demonstrating the lack of harmony between the ventricles are based, has been trustworthy. Many of these observations have depended upon the study of the movements of the heart itself. But, unfortunately, interpretation of the cardiac movement is so surrounded with difficulties that little reliance can be placed on observations based upon the evidence afforded by the usual means of clinical examination. From what has already been said about the heart during the period when a pulse beat has been missed, it will be seen that it is far from easy to tell what is taking place in the different chambers of the heart. Again, evidence of the discordance has been sought for in the movements of the veins in the neck. But here again little reliance can be placed on inspection, because it is very difficult to be certain whether the neck pulsation may not be due to the auricle. As has already been shown, there is no doubt that the rhythm of the right auricle and of the left ventricle does sometimes depart



from the normal. But the evidence of a discordance of the two ventricles has never yet been demonstrated in the human subject, so far as my reading has gone. That it must be very unusual, unless in a dying heart, I am very certain. I have taken a very large number of observations from a great many patients, and there are only a very few cases where I have been able to say that the two sides had not acted simultaneously. It may be that even in these cases another interpretation of the facts may arise.

§ 227. *Hemisystole with the auricles active*.—A male, aged forty-two years, consulted me lately. He had been a collier and a very hard drinker. When he called to see me he was very short of breath, suffering intense præcordial pain, and had a quick irregular pulse. The pain was induced by his walking up a somewhat steep road, and was undoubtedly an attack of angina




FIG. 308.—Simultaneous tracings of the jugular and radial pulses. The auricle preserves its rhythm during the irregular periods in the radial pulse. The wave, *a'*, is the auricular wave during the premature contraction of the left ventricle. The absence of the ventricular wave, *v*, after the wave, *a'*, indicates that the right ventricle had contracted early, evidently synchronous with the premature contraction of the left ventricle.

pectoris. The lungs were voluminous and prevented the mapping out of the heart's dulness with accuracy. The heart did not appear to be enlarged. There was no murmur. There was marked pulsation in the veins of the neck. Tracings taken of the radial pulse showed that the irregular pulse was due to premature systoles of the ventricle occurring singly and in groups. In Fig. 308 there are three isolated (xxx) instances of the premature systole occurring singly. It will be seen that the auricular waves (*a* and *a'*) maintain their rhythm during this irregular period, and practically correspond to the description given in Chapter XXVI.

When the irregularity took the form of a series of premature beats, a most curious and interesting discordance between the rhythm of the radial pulse and jugular pulse was revealed. The upper tracing in Fig. 309 shows the jugular pulse pursuing its course with a steady unaltered rhythm. In the period *x* to *x* there are three beats of the radial pulse. This period corre-

sponds in time to two beats when the pulse is regular. It also corresponds in duration to the irregular periods in Fig. 308, the only difference being that in Fig. 308 after the premature beat there is a long pause; while in Fig. 309 another small beat occurs during this long pause. In the jugular pulse there are two auricular waves during this period, and there is no auricular wave preceding the two premature beats (*pp*). This instance might be looked upon as an illustration of the ventricles being stimulated to premature contraction, while the auricles pursued the even tenor of their way, and that it corresponds to the form of irregularity described in Chapter XXVI. But there seems to be more than that present in this case. In describing the irregularity due to stimulation of the ventricles alone it was pointed out that usually there was evidence that the two

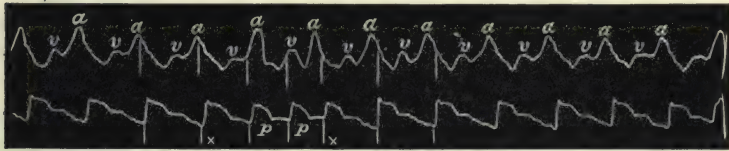


FIG. 309.—Simultaneous tracings of the jugular and radial pulses during irregular action of the left ventricle. The jugular pulse preserves an unaltered rhythm throughout, both right chambers (*a* and *v*) being regular in their rhythm. In the radial there is a marked irregularity from *x* to *x*, the two beats, *pp*, evidently being premature. Here the right and left ventricular have not contracted simultaneously. Compare with Fig. 308 from the same patient.

ventricles contracted irregularly together, while the right auricle maintained its wonted rhythm, as in Fig. 308. Here, on the other hand, there seems to be reason in assuming that the right ventricle maintained the same rhythm as the right auricle. The wave, *v*, due to the right ventricle in the jugular pulse in Fig. 309, is just as evident during the period when the radial pulse is irregular as at other times, in marked contrast to what happens in Fig. 308. I am therefore disposed to suggest that here we have an evidence of both chambers of the right heart acting regularly while the left ventricle acted irregularly.

This is a very exceptional case, being the only instance of the kind in a very large number of observations. The conditions under which it was obtained were also exceptional. It is seldom one has the opportunity of getting tracings of the venous and radial during an attack of angina pectoris. During this period of cardiac distress the heart must have been abnormally stimulated. I have made numerous examinations of the patient since,

and the pulse has been invariably regular, and I have not seen him again with a paroxysm of cardiac pain.\* (Another instance of a curious discordance between the right and left hearts is given in § 239.)

§ 228. *Hemisystole with the auricles paralysed.*—Fig. 310 was taken from a lad aged twelve years, dying from great dilatation

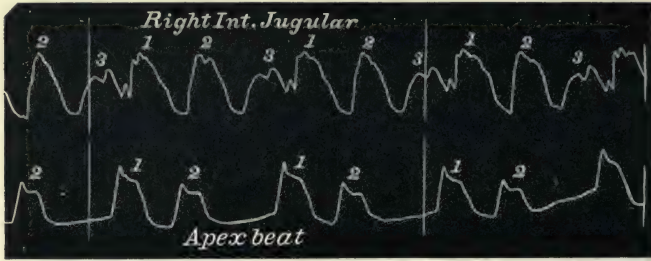


FIG. 310.—Simultaneous tracings of the jugular pulse and apex beat. The jugular pulse is of the ventricular form, and shows a wave (3) due to the right ventricle when the left does not contract.

of the heart consequent upon mitral stenosis. The pulse for short periods would be of the bigeminal form, two beats following one another, then a long pause, as is well shown in the apex tracing. But during the period occupied by the two apex beats

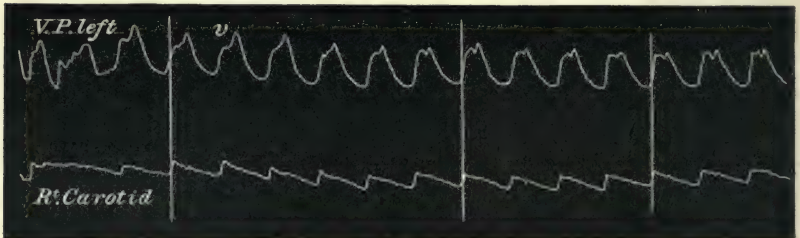


FIG. 311.—Simultaneous tracings of the jugular and carotid pulses. The venous pulse is of the ventricular form.

and the pause it will be seen there are three well marked waves in the veins. The venous pulse during the whole time the patient was under observation was of the ventricular form (Fig. 311). Every third wave of the jugular pulse in Fig. 310 is smaller than the others, and the falling line of the wave is interrupted by the earlier occurrence of the succeeding wave. Here

\* The patient dropped down dead three months after these observations were made.



it seems to me there is distinct evidence of three beats of the right ventricle to two beats of the left. We have seen already how frequently the left ventricle pauses for a longer time than usual after an early occurring systole. Whether the greater accumulation of blood of the right heart stimulated the ventricle to contraction I do not know, but it is curious how its diastole

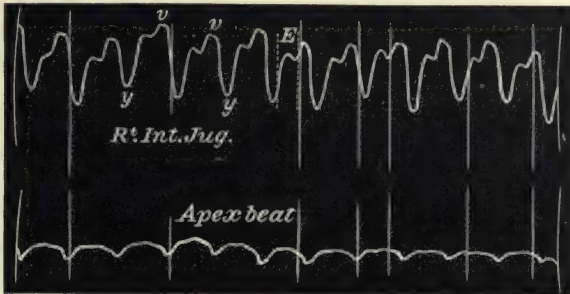


FIG. 312.—Simultaneous tracings of the jugular pulse and of the apex beat. The venous pulse is of the ventricular form.

is cut short after the third wave to accept the rhythm of the left ventricle.

In another patient, a female aged thirty-three years, suffering from extreme heart failure consequent on mitral regurgitation, the result of old standing myocarditis, for a considerable time before her death the venous pulse was of the ventricular form (Figs. 312 and 313). Shortly before her death the pulsations in the jugular




FIG. 313.—Simultaneous tracings of the radial and jugular pulses. The venous pulse is of the ventricular form, and continues during the pauses in the radial pulse (o and o).

vein were much more numerous than the arterial pulse. Thus Figs. 314 and 315 show not only more waves in the jugular tracing than in the carotid, but also that there is a discordance in the rhythm.

The irregularity in this case is more marked than in the last, for in that case when the left ventricle did contract, the right contracted also at the same time. I do not think that there

could be any doubt in the interpretation of the waves in Figs. 314 and 315. With these exceptions, in all the numerous tracings I

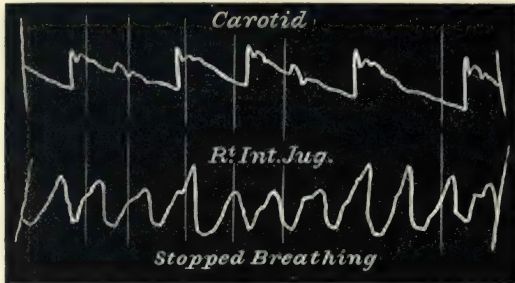


FIG. 314.—Simultaneous tracings of the carotid and jugular pulses. The jugular pulse is of the ventricular form, and the two pulses show an absence of harmony between the action of the two ventricles.

have taken the ventricles have invariably been shown to contract together, even when there was a demonstrable discordance between

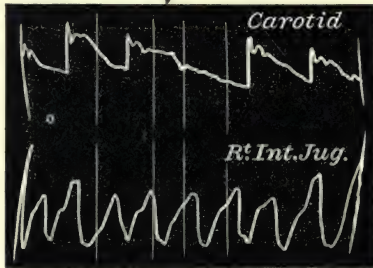


FIG. 315.—Shows the same as Fig. 314.

their rhythm and that of the right auricle. It is to be noted that in the two last cases the discordance occurred in dying hearts.

## CHAPTER XXX

### THE CAUSES OF PULSE IRREGULARITY

- § 229. The premature systole.
- 230. Cushny's experiments compared with clinical observations.
- 231. A local stimulus probably the cause of pulse irregularity due to premature beats.
- 232. Pulse irregularity and vagus influence.
- 233. The youthful form of irregularity probably due to vagus influence.
- 234. The pulse in auricular paralysis.
- 235. The pulse (arterial and venous) in digitalis poisoning.

IN this chapter I propose to discuss the points in connection with pulse irregularity that seem to lead us towards an appreciation of its cause. While I may venture upon suggestions as to the immediate cause, I do not for a moment imagine that my suggestions are indisputable or that my interpretations are correct. They may, however, have some value in drawing attention to certain conditions under which pulse irregularity arises.

In discussing this subject we will consider the cause of the premature systole in the adult type of irregularity, the cause of the youthful type of irregularity and its probable relation to the vagus nerve, the results of auricular paralysis, and the effects of digitalis in producing pulse irregularity.

§ 229. *The premature systole.*—In my earlier study of this subject, published in 1894, I drew attention to the similarity of the early occurring imperfect pulse beat, as I then called the premature pulse wave, to the early occurring imperfect systole manifested in the experiments on animals, found in such tracings as those of Hürthle and Marey (see Figs. 62 and 63). I also pointed out that these premature systoles were found sometimes associated with the systoles of both auricle and ventricle, and at other times with the systole of



the ventricle alone, the auricle maintaining its wonted rhythm. This distinction, as also the difference between the youthful type of irregularity and that where a premature beat occurred, were put forward somewhat diffidently. Since 1894 I have carried the inquiry over a very much wider field, and am able not only to confirm my earlier suggestions, but also to point out other equally interesting observations. I dwell upon this perhaps unnecessarily, but with some satisfaction, for since then two other writers have independently come to similar conclusions in regard to the premature systole, and one has given experimental proof of the correctness of my observations on the human subject. Of course neither of these writers was aware of my paper, and they were perfectly justified in considering their results as original observations. The admirable papers of Wenckebach<sup>20</sup> and Cushny<sup>21</sup> have strengthened materially the confidence I have in the propriety of the division of pulse irregularities given here, and Cushny's experiments amplify the evidence in favour of my conclusions.

§ 230. *Cushny's experiments compared with clinical observations.*—Cushny's experiments were performed on the exposed

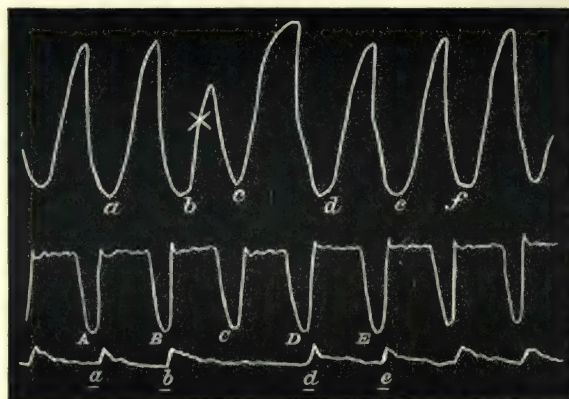


FIG. 316.—The upper tracing was drawn by the ventricle, the next by the auricle, the third by a sphygmograph attached to the carotid artery. During systole the auricular and ventricular levers made a stroke downwards. During diastole they rose again. Stimulation applied to the ventricle at  $\chi$  causes a premature systole of the ventricle, and a missed beat in the carotid, but has no effect upon the auricular rhythm (Cushny).

hearts of dogs, and the movements of the auricles and ventricles were recorded separately by a system of levers, a tracing of the carotid pulse being taken at the same time. When a single

electric shock was passed through the ventricle at any time except in the refractory period it was followed by a premature contraction of that chamber (Fig. 316). Sometimes the premature systole was of sufficient strength to cause a pulse beat in the carotid, at other times it failed to do so. Thus Cushny says: "In Fig. 316 a premature systole (*c*) of the ventricle was induced by an electric shock which reached that chamber at a point indicated by the cross lines *x* in the ventricular tracing. It was succeeded by relaxation, and the ventricle then remained quiescent until it was raised to activity (*d*) by an impulse descending from the auricle. The auricular rhythm was unaffected by the irregularity of the ventricle. If the course of each impulse be followed from the auricle to the ventricle, and finally to the pulse, it is found that *A* is followed by *a*, and then by *a*, *B* by *b* and *b*. But *C* beginning in the auricle has no effect on the ventricle, which it reaches during the premature systole, *c*—that is, during a refractory period. *D* is followed by *d*, however, and later by *d*, and the normal sequence is then reinstated."

This experimental demonstration is a proof of the correctness of the explanation given in Chapter XXVI, and the tracings 274,

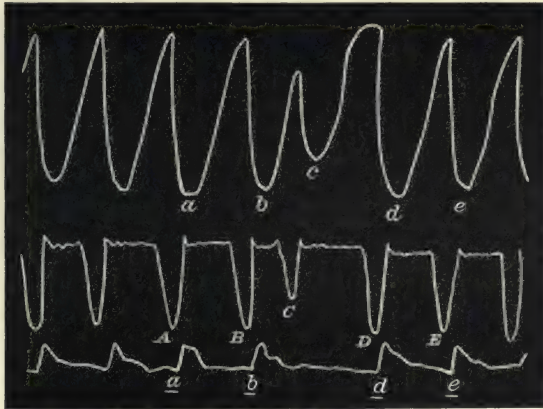


FIG. 317.—Inscribed in the same way as Fig. 316. The electric stimulus was applied to the auricle, and there results a premature systole of the auricle, followed by a premature systole of the ventricle, while the beat is absent from the carotid (Cushny).

275, 276, 278, 279, 280, and 308 demonstrate that what took place in this electrically stimulated dog's heart occurred in the human hearts, namely, a premature contraction of the ventricle,

while the auricle maintained its rhythm. "When an electric shock is passed through an auricle (Fig. 317) a premature systole is caused in that chamber exactly as in the ventricle, but it does not remain limited to the auricle, but is transmitted to the ventricle, which contracts prematurely, as if it had received a direct stimulus. A weak premature pulse is sometimes seen in the artery, but here again the blood expelled is generally too small in amount to cause any appreciable movement, and the tracing displays a complete intermission. In Fig. 317 *A* gives rise to *a* and *a*, *B* to *b* and *b*, and *C* to *c*, which is not followed by a distinct movement in the artery. The next normal auricular systole, *D*, is followed by *d* and *d*, and *E* by *e* and *e*."

This experiment verifies the interpretation of the tracings 264-271, although in all these the premature systole was well-marked in the radial pulse.

§ 231. *A local stimulus probably the cause of pulse irregularity due to premature beats.*—Apart from the testimony that these experiments bear to the action of the chambers, they bring us a little nearer to the cause of the irregularity. The fact that local stimulation of the auricle or ventricle produces this form of irregularity in the dog suggests that some local stimulus is the cause in the human being. The changes that affect the muscle wall are often so gross that the local nervous mechanism is bound at times to be materially altered. I know that physiologists doubt or deny the presence of an independent intrinsic nervous mechanism, but the conditions under which they study the nerve mechanism are very different from what occurs in the diseased hearts of human beings. What the nature of this disturbance in the nerve supply in the heart is, I cannot imagine. Nor does the study of the nature of the disease affecting the heart help much. Thus in two cases of tricuspid stenosis where the premature systole was occasionally present, each case presented a different form. In Fig. 280 the auricle maintained its rhythm while the ventricle prematurely contracted; while in Fig. 266 both auricle and ventricle prematurely contracted. If it be granted that a local stimulus may be the cause of the occasional premature systole, it will be from the same source that we must seek for the cause of the bigeminal pulse when the heart takes on that rhythm for long periods, as well as for the cause of certain cases of rapid heart action. I have already shown that the continued bigeminal pulse may be due either to



stimulation affecting the auricle and ventricle or affecting the ventricle alone. It is not likely that the stimulation of either the vagus or sympathetic would allow the auricle to escape its influence in the one case and to be affected by its stimulation in the other. Again, where groups of premature systoles occur together presumably a local stimulus is at work. In one of Marey's experiments he showed that when the electric stimulation of the heart was continued for a short time, a group of premature systoles followed. In like manner, we may at one time detect an occasional premature systole in patients, and at other times groups of these premature systoles. I have already drawn attention and illustrated this in the paragraph dealing with paroxysmal tachycardia, where in some cases at least it can be demonstrated that the rapid heart action is but a long continued series of premature systoles. As neither section of the vagus nor stimulation of the sympathetic is capable of producing such enormous quickening, we are driven to the conclusion that a local stimulation is at work in producing the various forms of irregularity due to premature systoles.

§ 232. *Pulse irregularity and vagus influence.*—The fact that on experimental stimulation of the vagus, the heart's action becomes slow and irregular has so impressed many writers that when they discover an irregular pulse in a patient they unhesitatingly recognise vagus influence. Thus such expressions as "a vagus pulse," a pulse "irregular from loss of vagus control," are very common. Personally, I am at a loss to understand what forms of irregularity are supposed to be indicated by these statements. Certain writers I know imagine that the bigeminal pulse, for instance, is due to vagus stimulation, and that such a pulse as Fig. 287 is a typical vagus pulse. Indeed, one of the most experienced experimental physiologists expressed to me most dogmatically that such a pulse as this was "a vagus pulse." At the time I accepted his opinion as being correct. But further consideration convinced me that it could not be due to vagus stimulation, for the reason that the same stimulation that produces single premature systoles also produces groups of premature systoles that result, as has already been shown, in a rapid heart action. As vagus stimulation slows the heart's action, it is impossible that it should be concerned in the production of premature systoles that result in increased rate of the heart beats (see the series of tracings, Figs. 323-327).

§ 233. *The youthful form of irregularity probably due to vagus influence.*—I think that the pulse that I have described as the youthful form of irregularity is more likely to be due to vagus action. I have no direct proof that it is so, but the following are the reasons that incline me to the idea. First, the character of the pulse, which shows a slowing of the heart's action by the irregular prolongation of the diastole. Other forms of slowing are mainly due to premature systoles whose strength is insufficient to propagate a wave to the artery. From what has already been said the premature systoles seem inconsistent with vagus stimulation. Second, in children there is an unstable condition of cardiac activity, shown by the readiness with which the sympathetic can be stimulated, the child's pulse being for this reason an unreliable guide. But during a period of great quiet and rest the pulse tends to become slow and irregular, evidence pointing to diminution or abeyance of the sympathetic influence, and in consequence of the predominance of the vagus influence. It is on the approach of puberty that the well-balanced antagonism between the two systems of nerve supply to the heart tends to become established. The tendency to this predominant manifestation of the influence of the one over that of the other is not nearly so frequent nor so readily excited in the healthy adult. Third, when the slowing of the heart evidently originates in the brain, as in the slow irregular pulse occasionally found in tuberculous meningitis and other cerebral affections, the irregularity is always, in my experience, of this type. One may infer in such cases that the heart's rhythm is modified by the disease affecting the centre of the vagus. The resulting slow pulse is thus entirely due to the prolongation of the diastole, and not to the occurrence of premature beats.

§ 234. *The pulse in auricular paralysis.*—It is a matter of common experience that many patients who present symptoms of advanced failure of the heart due to disease of the mitral valves, do present a pulse with certain characters common to all, viz. a pulse small, irregular, often of low pressure, but, when carefully compressed, sometimes being of good pressure. These characters may undoubtedly be present in weakly persons with no valvular disease. The pulse in advanced mitral disease is small, because when there is great incompetence of the mitral valves the blood flows freely back into the auricle during the ventricular systole. When there is stenosis, a diminished

amount of blood reaches the ventricle, and part of it is usually expelled back during the ventricular systole, because regurgitation is often present as well. The strength of the pulse will depend upon the strength of the heart muscle, and it will be found to vary not only in separate individuals but in the same case, according to the degree of heart failure. It is, however, the irregularity that is the most striking symptom. In the early stages of mitral disease irregularity is by no means frequent. In the later stages it is doubtful if any case is continually free from it. The reason for this great difference is to be found in the loss of the controlling influence of the auricle. The function of the auricle being to regulate the supply of blood to the ventricles (and it may be that the normal rhythm is to some extent dependent upon the regular supply of blood), and this regulating influence being lost, the ventricle is stimulated to contract at uncertain intervals. I have no clear idea of how the stimulus to contraction arises, and so cannot definitely say how the auricle modifies the ventricular rhythm. But as a matter of observation I can with confidence state that the heart has a very great tendency to irregular action when the auricles lose their power of contraction. In an analysis of all my cases that have presented undoubted evidence of paralysis of the auricle secondary to mitral disease, every one has been irregular. Most of these have, indeed, shown periods of regularity, but they have at all times shown long periods of irregular action, even when, for them, in fair health.

In marked contrast to these cases is the persistent regularity of the pulse in tricuspid stenosis, so long as the auricle is capable of independent action. In looking over the tracings of the seven patients who have died from tricuspid stenosis, I have only found two that showed irregularity while the auricles were vigorous and active, and in both the irregularity was a very rare event. If I extend the list and include all the patients who have had a liver pulse of the auricular form (about twenty in all), I have never detected another instance, even though the patients were at times suffering from extreme heart failure. The exceptional instances have been given in Figs. 266 and 280. The irregularity was due in the one case to premature action of the auricle, and in the other to premature stimulation of the ventricles. The patient in the latter case lived for seven years after this, and though repeatedly examined never had an



irregular pulse until there was evidence of paralysis of the auricle. In this case, given to illustrate the change of the auricular pulse to the ventricular, it will be noted that the tracings showing the presence of an auricular wave are regular, and the tracing given, showing the auricular paralysis, is irregular (Figs. 183-186). As a matter of fact I never found this patient's pulse regular after I detected the absence of the auricular wave, the irregularity being usually very great. In another patient, who died when symptoms of the auricular paralysis were setting in, no irregularity was ever detected until shortly before death (Figs. 189-193). I had had her under observation for several years, and had watched her through several attacks of extreme heart failure. The auricular liver pulse was always evident, but there never was found any trace of irregular rhythm.

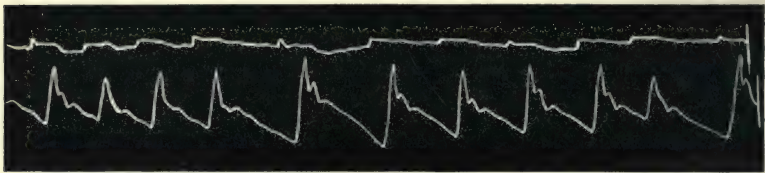


FIG. 318.—Simultaneous tracings of a slight movement in the neck, due to the carotid, and of the radial pulse. The tracing from the neck was taken from the same situation as the jugular in Figs. 179 and 266, and demonstrates the absence of the jugular pulse and the appearance of irregularity in the radial pulse with paralysis of the auricle.

I have already remarked, in speaking of paralysis of the auricle, that in a patient with tricuspid stenosis, where paralysis of the auricle ensued in consequence of the formation of a fibrinous clot in the auricle, that the pulse became irregular after the auricle was demonstrably inactive. Fig. 318 represents this irregularity. The movement in the neck is due to the carotid, and is in striking contrast to the large movement hitherto present, shown in Figs. 179 and 266.

§ 235. *The pulse (arterial and venous) in digitalis poisoning.*—Digitalis, it is well known, has a remarkable power of altering the rhythm of the heart, and many experiments in animals have demonstrated its action on the individual chambers. So far as I know, no evidence has been produced showing its action in the human being on any chamber but that of the left ventricle. It is but seldom indeed that one is able to demonstrate its action, because it is not wise to push it so far as to produce the

distinctive irregularity, and even when pushed it is only in a few cases that the venous pulse is available for investigation.

A female, aged twenty years, consulted me for weakness and shortness of breath. There was a well marked presystolic murmur. She was prescribed tincture of digitalis, and partook so heartily of the drug that in a fortnight she presented well

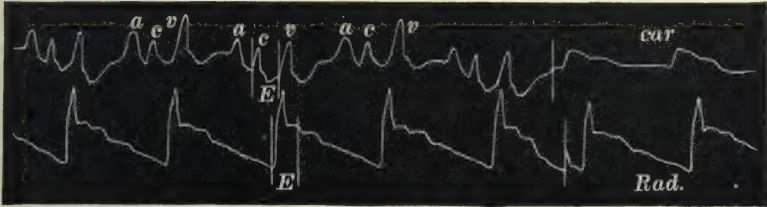


FIG. 319.—Simultaneous tracings of the jugular and radial pulses.

marked symptoms of digitalis poisoning—præcordial distress, dyspnœa, and a slow irregular pulse. The pulse varied in character from time to time, sometimes being quite regular, sometimes very slow for a few beats, and sometimes showing distinct beats due to premature systoles of the ventricle. Fig. 319 shows the venous and radial pulses during a regular period. It will be noted here how large and abrupt is the wave, *v*, due

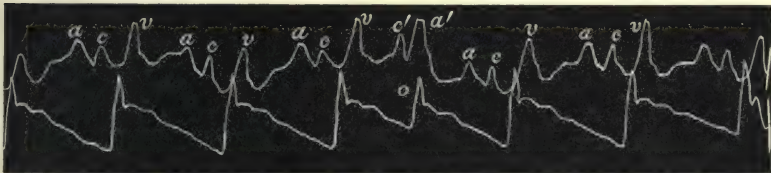


FIG. 320.—Simultaneous tracings of the jugular and radial pulses. The carotid wave, *c'*, follows at the same distance the preceding carotid wave, *c*, as the premature pulse in the radial follows the preceding pulse beat. The auricular wave, *a'*, follows the carotid wave, *c'*, but is separated from the preceding auricular wave, *a*, by the same distance that separates the auricular waves when the heart acts regularly. The auricular wave following *a'* occurs earlier, as if to take on the ventricular rhythm.

to the systole of the right ventricle after the closure of the semilunar valves. Figs. 320 and 321 show the radial pulse irregular on account of the occurrence of an occasional premature systole at *o*. The waves, *a'*, in the jugular pulse occur at regular intervals after the waves, *a*. These waves are auricular in origin. They appear exactly at the same intervals as the auricular waves when the pulse is regular. But the auricular waves, *a*, following the waves, *a'*, occur earlier, as if to take on

the ventricular rhythm. The carotid wave,  $c'$ , corresponds to the premature radial pulse at  $o$ , and it has no auricular wave preceding it. Here we have an illustration how the digitalis affects the heart by stimulating the ventricles to contract independently, and in front of the auricular contraction. Fig. 322 is a tracing from the same patient when the pulse was slow as well as irregular. It will be seen here that the auricle still




FIG. 321.—Shows the same as Fig. 320.

preserves its rhythm ( $a$ ). There are no premature pulse beats, but there are occasional long pauses. The radial and carotid pulses that appear after the long pauses are separated from their accompanying auricular waves by a longer interval than usual. The spaces  $o, o$  represent the time between the appearance of the auricular wave,  $a$ , in the venous pulse and the appearance of the carotid pulse,  $c$ . It is evident that there is a distinct delay in

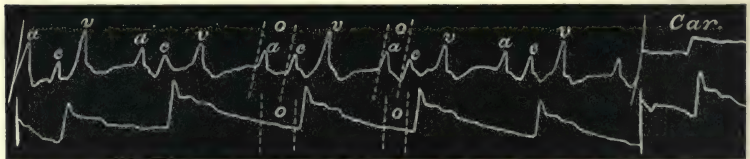


FIG. 322.—Simultaneous tracings of the jugular and radial pulses. Although the rhythm of the carotid ( $c$ ) and radial pulses varies, the auricular waves ( $a$ ) preserve their rhythm. Hence when the left ventricular diastole is prolonged, the arterial pulse (carotid and radial) is separated from the auricular wave by an abnormal distance (the space  $o$ ). Note that the wave,  $v$ , due to the right ventricle bears a constant relation to the carotid wave,  $c$ , but not to the auricular wave,  $a$ , showing that the two ventricles acted together.

the appearance of the carotid pulse after the auricular systole, particularly in the first period. In fact the irregularity in the pulse is manifestly due to a variation in the time of response of the ventricular systole after the auricular systole. It will be seen that the wave,  $v$ , preserves a constant time relationship to the carotid pulse,  $c$ , but not to the auricular wave,  $a$ . The wave,  $v$ , being due to the right ventricle, it is evident that it possesses the same rhythm as the left.



So far as this case throws any light upon the effects of digitalis, it demonstrates that the drug tends to render the ventricular contraction independent of the auricular. At one time the ventricular systole anticipates the auricular systole and contracts before it (Figs. 320 and 321). At another time the ventricles fail to respond at once to the stimulus after the auricular systole producing the slow pulse (Fig. 322).

This interpretation practically corresponds to the results obtained by experimental observation on animals whose hearts have been affected by digitalis. "Not infrequently the auricle and ventricle beat in different rhythms, the ventricle developing a spontaneous rhythm, which may either be faster or slower than the auricle" (Cushny).

## CHAPTER XXXI

### SOME INDETERMINATE POINTS CONCERNING THE VENOUS PULSE, AND SUMMARY

- § 236. The nature of the waves in the vein.
- 237. The symptom of auricular paralysis.
- 238. The relationship of the venous and arterial pressures.
- 239. The arhythmic contraction of the cardiac cavities.
- 240. The venous pulse in adherent pericardium.
- 241. Summary.

IN the consideration of the venous and liver pulses in the foregoing pages I have dealt only with a few of the many points of interest that this subject opens up in the study of the action of the heart. No doubt when the subject is more thoroughly understood other aspects will be studied and the interpretation given here substantiated or modified in many ways. In this chapter I shall touch upon a few points which, partly for their rarity and partly from incomplete observation, I have not been able to explain satisfactorily.

§ 236. *The nature of the waves in the vein.*—In the course of the explanation of the venous and liver pulses, I have practically assumed that the waves in the veins and in the liver, which are recorded on the tracings, are waves of blood sent back by the contracting auricle and ventricle. Although I am of opinion that such is essentially their nature, yet there are other factors that enter into their formation. If the blood in a superficial vein flowing towards the heart be intermittently stopped by pressure with the finger, the vein visibly distends during the stoppage and collapses when the pressure is removed. During each systole of the auricle a similar stoppage occurs, and the on-coming blood is temporarily arrested and the veins distend. If the engorgement of the right side of the heart is sufficiently

great, this distension can sometimes be seen in certain of the superficial veins. With the diastole of the auricle the contents of the veins rush into the auricle and the veins collapse. This swelling and collapse in the vein occurring rapidly presents the appearance of a pulsation in the vein. To such pulsation the term "negative pulse" has been applied. There is no doubt such circumstances modify the different forms of the venous pulse, and when the venous pulse is visible in the more distant and superficial veins, such as in the face and on the surface of the thorax, it is no doubt entirely of this nature. But in regard to the veins nearer the heart, such as in the internal jugulars, I am distinctly of the opinion that the waves of the venous pulse are due to blood being expelled backwards by the auricle or ventricle, a distinct backwash. No one who has studied well-marked cases showing the venous or liver pulse could doubt that there was present some much greater force than mere stasis in the vein due to stoppage of the stream. The pulsation not only offers considerable resistance to the compressing finger, and in the case of the liver to the compressing hand, but the wave at times is of sufficient strength to close the valves in such veins as the jugular, subclavian, and femoral so violently that a distinct sound is elicited by the suddenly stretched valves.

The character of the wave in the veins differs from that in the arteries in this way. The arteries are always distended and full of blood, and the pressure within them even at the end of the diastole is high, and when the ventricle contracts the distension of the artery occurs only to a very minute extent, practically imperceptible by our usual methods of observation (§ 52). The veins, on the other hand, are not distended at the end of diastole, but are to a great extent collapsed. With the systole of the auricle or ventricle a wave of blood passes back, distending the vein. What we obtain in taking a tracing of the venous pulse is a variation in the size of the vein. What we obtain in taking a tracing of the radial pulse by means of a sphygmograph is a variation of the pressure within the artery (§ 10). No doubt the size of the vein will vary with variations in the venous pressure, but the character of the tracing will not accurately represent these variations in pressure. Thus in the tracings of the ventricular venous pulse there is always a prolongation and often an increase in size of the wave during the postsphygmie period. A glance at Fig. 176 will show that during this



period the ventricular pressure is falling, and the ventricular cavity being in direct communication with the vein, the venous and ventricular pressures ought to correspond. But if one bears in mind that the contracting ventricle has sent back during the earlier period of its systole a wave of blood that has distended the vein, and that no diminution in the size of the vein can take place until the auricular pressure falls lower than the ventricular, distension of the vein must of necessity continue until the blood flows into the ventricle. The time when this occurs is on the opening of the auriculo-ventricular valves—these valves only opening when the auricular (or venous) pressure is higher than the ventricular. In many tracings the highest portion of the venous wave occurs during the postsphygmie period. I have already given an explanation of the probable cause for this (§ 176).

When a flowing stream is suddenly checked, a wave is sent back in the opposite direction. It has been suggested that the sudden and forcible contraction of the ostial veins may originate the waves present in the venous pulse. Apart from the fact that such a theory could not explain the gradual change of the venous pulse of the auricular form to one of the ventricular form, the force of such a wave could never attain the power that I have ascribed to these regurgitant waves.

§ 237. *The symptom of auricular paralysis.*—In discussing paralysis of the auricle I have shown how the paralysis may occur in dilatation of the heart consequent upon failing compensation in mitral disease (§ 157), or during a prolonged attack of paroxysmal tachycardia (§ 211). In one other instance I have found it occur, namely, during a prolonged period of irregular action of the heart. This case had some resemblance to those affected by paroxysmal tachycardia, but I hesitate to include it amongst them, and in the meantime present the facts as they appear to me, trusting that further experience may decide its true nature.

The tracings from this patient have already been given, to show the transition of a pulse with occasional premature beats to one where there was a long continuation of premature beats, resembling what might happen in paroxysmal tachycardia (§ 103, *b*).

The patient was a female, aged thirty-five years, and was eight months pregnant. For several years she suffered at times from breathlessness and irregular action of the heart. During the few

weeks she was under my care the pulse was usually irregular, the degree of irregularity varying very much. When the heart was irregular the venous pulse was always large, while, when the heart was regular it was scarcely perceptible, and it was with difficulty that I got the faint tracing of it in Fig. 323. The waves in the jugular, though slight, are recognisable, and the pulse is of the auricular type. In Fig. 324 the heart is acting irregu-




FIG. 323.—Simultaneous tracings of the jugular and radial pulses. The jugular venous pulse is of the auricular form. These and the following four tracings are from the same patient.

larly. The radial pulse shows three long pauses at xxx. The auricular waves, *a* and *a'*, in the venous pulse occur at regular intervals. During each long pause in the radial there is a large wave, *a'*, due to the auricle, and larger than the other auricular waves, for the reason already given (§ 215), namely, because at the period the auricle contracted the ventricle was in systole, and hence a larger wave was sent back into the veins. It will be




FIG. 324.—Simultaneous tracings of the jugular and radial pulses during irregular action of the heart. The auricle preserves its rhythm, there being a large wave, *a'*, during the premature contraction of the ventricles.

noted that after the large auricular wave, *a'*, there is never a ventricular wave. This tracing exemplifies the form of irregularity due to stimulation of the ventricles alone, corresponding to Cushny's tracing (Fig. 316). In Fig. 325 a very similar irregular condition is present, the difference being that every third arterial beat here is missed and is represented in the radial tracing by the aortic notch, *n'*. In these three tracings (Figs. 323, 324, and 325) the period *E*, representing the time when the semilunar valves are open, shows in the jugular pulse a great

fall, the auricular depression. In Fig. 326 the radial tracing shows two full beats in the centre of the tracing, all the others being premature beats. The beat preceding the full beats is

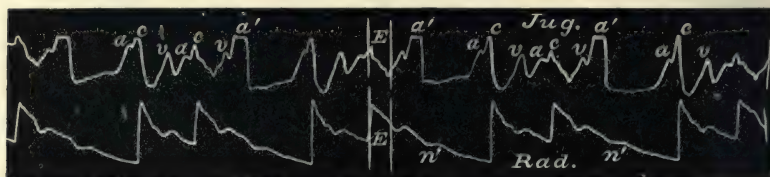


FIG. 325.—Shows the same as Fig. 324.

missed, and shows only a notch,  $n'$ , as in Fig. 325. The venous pulse at the time of the full radial beats shows the same features as are present with the full radial beats in the three preceding tracings, namely, a small auricular wave,  $a$ , the carotid wave,  $c$ ,

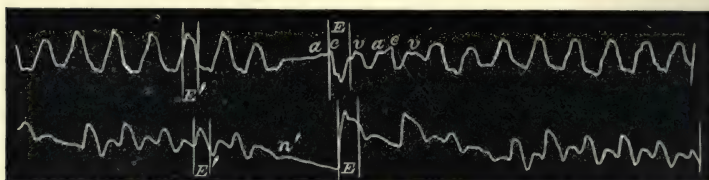


FIG. 326.—Simultaneous tracings of the jugular and radial pulses, showing two full radial beats in the centre of the tracing, all the others being premature beats. Corresponding to the ventricular systole  $E$ , there is a fall in the jugular pulse when the radial beat is full and a rise when it is premature.

the auricular depression during the period  $E$ , and the ventricular wave,  $v$ . But when the venous pulse corresponding to the premature beats is considered, a remarkable change is found. There is but one large wave and one large fall, and the period

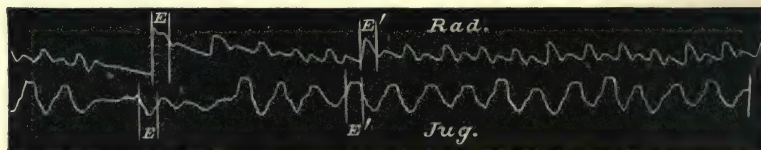


FIG. 327.—Shows the same as Fig. 326.

when this wave occurs is during the ventricular systole  $E$ , in striking contrast to the large depression at the time with the full radial beats, and in the preceding three tracings. In Fig. 327, with the exception of one full beat preceded by a missed



beat, the whole tracing consists of premature systoles. There is a depression of the venous pulse, *E*, corresponding to the one full radial beat, all the other beats have waves occurring at the same time as the radial pulse, *E'*.

The only explanation of this series of tracings that seems reasonable to me is that when the heart shows an occasional irregularity the auricle remains active, but that when a series of premature beats follow one another with great rapidity, the heart does not completely empty, but the residual blood becomes so great that the auricle is distended and is temporarily unable to contract, and hence waves of blood synchronous with and due to the ventricular systoles are sent back into the veins. The evidence of great engorgement was in the venous distension, for always during these attacks the veins in the neck were very full. If this interpretation is true we can see in these tracings the changes that take place in the heart during an attack of paroxysmal tachycardia. In the description of acute dilatation I showed that there was a marked change in the venous pulse, such as occurs here.

§ 238. *The relationship of the venous and arterial pressures.*—If one were simply to adopt the suggestions of some physiologists the question of this relationship would be an extremely simple one. When there is a rise in arterial pressure there is a fall in the venous pressure. When there is a rise in the venous pressure there is a fall in the arterial. But the question is far more complicated than this. I have not been able to formulate any definite laws that would seem to meet all the evidence that one finds in the study of heart affections. That some definite laws regulate the relationship there can be no doubt, but considerable attention will have to be paid to the subject before all the conditions are understood. I shall only refer to a few points I have observed, giving such explanation as seems most reasonable to my mind.

In failure of the heart, such as occurs in acute dilatation, whether due to failing compensation in valvular disease or from alcoholic or other muscle failure, there is invariably a marked lowering of the arterial pressure, and not infrequently a marked rise in the venous pressure, as seen in the distended and pulsating jugular veins. In one sense it is easy to understand the reason for this. In the typical examples quoted in § 209 the tracings there amply bear out the suggestion. Here the failing muscle

had not strength to pump onwards a sufficient quantity of blood, the blood stagnates in the heart, and the organ enlarges and its orifices dilate. Waves of blood are sent back through the tricuspid orifice and the ostial veins, and become visible in the jugular veins. There is here in consequence a great fall in the arterial pressure and a great rise in the venous.

In § 60 I referred to the fact that in cases of recurrent increase of arterial pressure associated with dyspnoea and other evidences of cardiac embarrassment, marked pulsation was sometimes present in the jugulars. The same increased sign of venous pressure is often met with in pregnancy during periods when the pulse is slow and the arterial pressure high, as in Figs. 47 and 200, which are both from pregnant women during temporary slowing of the pulse. This is also well seen in the tracings from the case of digitalis poisoning noticed in § 235. In all these instances there is evidence of increased arterial pressure associated with increased venous pressure. The reason that appears to me the most feasible is that during these attacks of increased arterial pressure there is a smaller output from the heart, and the blood accumulates in the heart till distension and widening of the venous orifices takes place. There is also probably less blood in the arterial system, for the contracted arterioles will naturally contain less blood. There is some evidence of this latter condition in the shrunken countenance that is sometimes seen in the elderly during one of these attacks of recurrent high arterial pressure. There are probably other factors present in modifying the pressures.

When a patient with a venous pulse, where there is no valvular disease, has a febrile attack, the venous pulse usually disappears. Here, I presume, there is a great widening of the arterial and capillary fields, and the blood is removed for the time from the venous to the arterial system. Besides, the heart is more vigorous in consequence of the heat acting as a stimulant. The disappearance of the venous pulse in febrile attacks I have frequently observed, and it is usually a good sign. It shows that the cardiac distension is slight and easily removed. When it persists in spite of the fever, it is, in some cases, a very serious sign, and indicates a considerable enfeeblement of the heart muscle. In a few cases of a temporary febrile character, I have seen it persist without any bad effects, but its persistence when the fever was long continued has always been of very serious significance. In

cases where there is a disappearance of the venous pulse without improvement in the patient's condition, it may possibly herald the near approach of death. Thus, in cases of pernicious anæmia I have observed its disappearance a few days before death. There are generally other symptoms pointing to the weakening of the patient, and the breathing becomes superficial and more rapid. In such cases passive congestion and œdema of the lungs has set in, and the abstraction of the blood from the veins naturally follows. *Post-mortem* examination always shows a large extent of hypostatic congestion. In such cases there is also great lowering of the arterial pressure.

§ 239. *The arrhythmic contraction of the cardiac cavities.*— In addition to the forms of arrhythmia described one occasionally meets with forms of irregularity difficult to understand. When

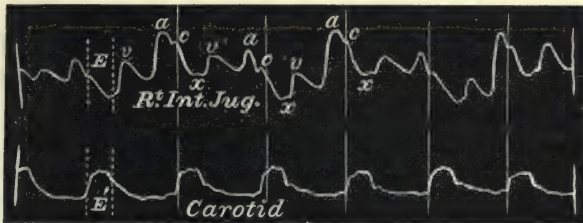


FIG. 328.—Simultaneous tracings of the jugular and carotid pulses. The jugular pulse is of the auricular form.

such an instance has come under my observation I have taken repeated tracings of the various movements in order to make sure that there is no error in observation. As a rule I have hitherto been able to unravel the meaning of the tracings I have taken, although sometimes I had to wait for years till a better illustrative case might arise. In course of time one is sure to come across similar forms of irregularity. But the following case has so far been unique in my experience, and although the tracings were taken more than eight years ago I am still unable to give a satisfactory explanation. The patient had mitral, tricuspid, and aortic stenosis. Her pulse during the few years she was under observation had invariably been quite regular. She suffered from periods of cardiac failure, and in recovering from such an attack about a year before she died I noticed for two days a peculiar want of rhythm in the action of the heart chambers. Fig. 328 shows the usual character of her jugular pulse taken at the same time as the carotid pulse. The jugular



pulse is of the usual auricular form, the auricular wave, *a*, being the most prominent feature. Fig. 329 shows the same jugular

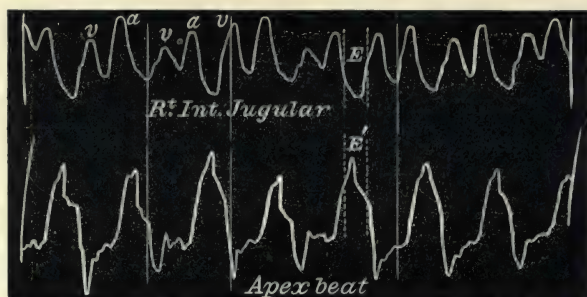


FIG. 329.—Simultaneous tracings of the jugular pulse and of the apex beat.

pulse taken with the apex beat. It is of the same nature as in Fig. 328, except that here the carotid wave is absent. In

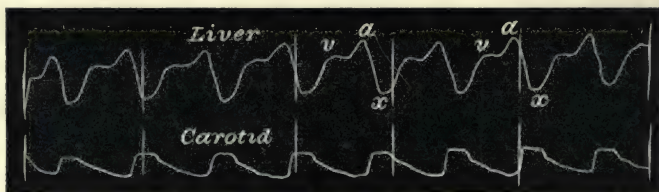


FIG. 330.—Simultaneous tracings of the liver and carotid pulses. The liver pulse is of the auricular form.

Fig. 330 the liver pulse is taken with the carotid, and it also is seen to be of the auricular form. The next three tracings show

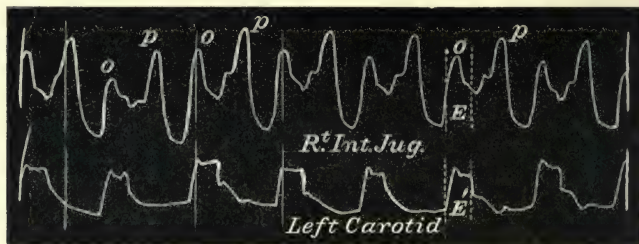


FIG. 331.—Simultaneous tracings of the jugular and carotid pulses, showing a curious form of arrhythmia.

a remarkable change in the time and character of the jugular and liver pulses. In Fig. 331, where the jugular and carotid pulse are taken together, the wave marked *o* is synchronous with

the carotid pulse. The period of ventricular outflow ( $E$ ) shows a rise,  $o$ , in the jugular pulse instead of the great depression in Fig. 328. The same change can be seen in Fig. 332, when the jugular pulse is taken with the apex beat. In the liver pulse the change is not so marked, although the character of the tracing is curiously changed (Fig. 333). In Fig. 334 the venous and liver pulses are taken together, and the time of the waves in the liver pulse agree with those in the venous—although the principal depression of the venous pulse is




FIG. 332.—Simultaneous tracings of the jugular pulse and apex beat, showing the same form of arrhythmia as Fig. 331.

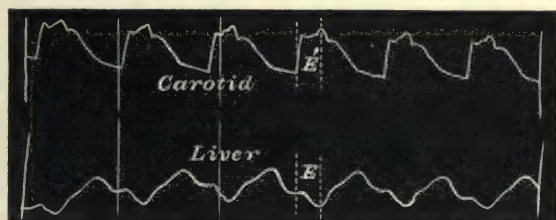


FIG. 333.—Simultaneous tracings of the carotid and liver pulses during the arrhythmic attack.

scarcely present in the liver. To explain this I can only suggest that the two sides of the heart are not acting together, that the wave,  $o$ , is due to the right auricle, and that the wave,  $p$ , represents

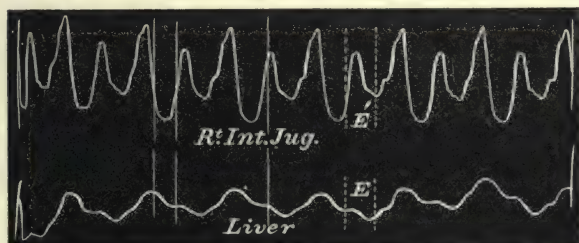


FIG. 334.—Simultaneous tracings of the jugular and liver pulses during the arrhythmic attack.

the postsphygmie portion of the wave due to the right ventricle. This view is borne out by the very striking resemblance of the venous pulse in Fig. 213 to that in Fig. 331. Both patients were recovering from heart failure, and both had valvular disease.

In Fig. 213 the interpretation is easy, as the carotid pulse serves as a standard.

§ 240. *The venous pulse in adherent pericardium.*—When the pericardium is adherent to the anterior thoracic wall (as in some cases of chronic mediastinitis), and when the visceral and parietal layers of the pericardium are also adherent, it would appear that a venous pulse of a very peculiar and distinctive type occurs. Friedreich described the symptoms, and suggested a very ingenious and probable explanation. According to him the venous pulse is characterised by a sudden collapse during the ventricular diastole. The cause for this is explained as follows: The adhesions between the heart and the anterior resilient chest wall drag in the chest during the ventricular systole. With the ventricular diastole the resilient chest wall suddenly rebounds outwards. This outward rebound straightens and depresses the diaphragm, and thus increases the size of the thoracic cavity. Consequently there is a sudden and considerable diminution of the intrathoracic pressure, and a lengthening of the superior vena cava, which result in the suction in of blood from the veins, producing in the jugulars a rapid diastolic depression. So far, however, I have not come across any tracings of the venous pulse demonstrating this particular phenomenon, and it must be a fact of rare occurrence, Friedreich's description appearing to be the only one. The rarity of its occurrence must be my excuse for introducing the following somewhat imperfect tracing, but as it demonstrates beyond the possibility of cavil the fact noted by Friedreich, it serves a useful purpose. The patient from whom it was obtained had been under the care of the late Dr. Leech of Manchester for nearly two years. The lad suffered from undoubted symptoms of mediastinitis with adherent pericardium. The heart was enlarged, and there had been evidence of cardiac failure, cedema of the legs, and enlarged liver. At one time there was present the typical pulsus paradoxus, with dilatation of the veins of the neck during inspiration and indrawing of the chest wall during ventricular systole. I saw the patient during a casual visit to the Manchester Infirmary, and obtained the accompanying tracing (Fig. 335) from the venous pulse at the same time as the radial pulse, by means of the clinical polygraph.

In the tracing it will be noticed that there are two main depressions, the smaller of the two, *x*, occurring during the period of the ventricular systole, *E* and *E'*. There can be no doubt that



this depression is due to the auricular diastole, and represents the usual auricular depression. The large depression, *z*, occurs immediately after the ventricular systole, and can only be attributed to the recoil of the chest wall after the systolic indrawing has




FIG. 335.—Simultaneous tracings of the radial and jugular pulses, showing a great depression occurring during the ventricular diastole. From a case of chronic mediastinitis.

ceased. The slight sharp wave immediately following the depression, *z*, is in all probability artificial, and due to the recoil of the membrane of the tambour after the very sudden filling of the vein which takes place at the end of this depression. In some of the curves the auricular and arterial waves are faintly indicated.

§ 241. *Summary.*—The venous pulse when visible in the jugular veins is an evidence of increased engorgement of the right side of the heart. The engorgement may be slight, in which case the chief features in the venous pulse are, a wave of blood sent back by the systole of the right auricle, and a depression due to the emptying of the vein by the diastole of the right auricle. There is usually present a smaller wave, the ventricular, in the mildest forms of regurgitation; this occurs after the closure of the pulmonary valves (or during the post-sphygmie period of the ventricular systole).

With increase of regurgitation this ventricular wave appears before the time of the closure of the pulmonary valves, but the last portion of this wave is always the most pronounced, and the time of closure of the pulmonary valves is often indicated on the tracings by a sudden increase in the size of the wave.

In advanced cases of tricuspid regurgitation, most commonly where there is disease of the mitral valves, this ventricular wave increases in size by encroaching more and more on the depression due to the auricular diastole. Both auricular wave and depression become less marked features in the venous pulse, and the engorgement may go so far that they may altogether disappear. When this happens the engorgement of the right auricle has reached

such a degree that the walls of the auricle are stretched and unable to contract. A venous pulse entirely due to the ventricular systole is therefore an evidence of paralysis of the auricle.

In the same manner the liver pulse may undergo variations. The regurgitation never produces a pulse in the liver, unless there is present some organic disease of the valves (mitral or tricuspid). The liver pulse and venous pulse when present in the same individual are always of the same type (auricular or ventricular).

The clinical significance of the venous pulse depends mainly on two conditions, namely, the type of pulse present, and the nature of heart change giving rise to it. The ventricular type results from a heart dilated in consequence of long standing failure consequent on valvular disease, and the engorgement is of a serious and permanent character. If the pulse be of the auricular type, then the condition of the heart giving rise to it gives an estimate of its importance. If it occurs in a heart debilitated from some recoverable ailment (as anæmia, pregnancy, typhoid fever, etc.), then it is of little practical significance. It is frequently present in patients suffering from failure of the muscular wall of the heart, as occurs in alcoholism, and in fibrous or fatty degeneration. It is then of very grave significance. It is often very marked in cases of pernicious anæmia and in some cases of malignant cachexia, and indicates grave weakening of the heart wall. Its presence in disease of the mitral valves is of variable significance. While the auricular wave shows that the auricle is active, the relative sizes of the auricular and ventricular waves sometimes indicate the amount of regurgitation present. When the ventricular wave becomes the larger of the two it surely indicates that the auricle is becoming embarrassed in its work.

A liver pulse is at all times a sign of advanced engorgement of the right side of the heart. A ventricular liver pulse is probably always present when there is a ventricular venous pulse, and has the same diagnostic significance. A liver pulse of the auricular type is somewhat rare, and is probably a diagnostic sign of tricuspid stenosis.

The venous and liver pulses give information concerning the action of the right auricle and ventricle during irregular action of the heart. The great majority of pulse irregularities can be divided into two groups: first, those where the irregularity is due to a variation in the duration of the ventricular diastole; and

second, where the irregularity is due to the occurrence of a premature ventricular systole. This premature systole may occur singly or a variable number may follow one another.

The first of these forms of irregularity occurs mostly in the young, and may be looked upon as a natural phenomenon due to slowing of the heart. The right auricle and ventricle can be demonstrated by means of the venous pulse, to participate in the same irregularity as the left ventricle.

The second of these two forms occurs but rarely in the young. It is common after middle age and in certain forms of heart failure. In some cases it can be demonstrated that both ventricles act irregularly while the right auricle preserves its rhythm. In other cases it can be shown that the right auricle also participates in the irregularity.

In cases with paralysis of the auricle, irregularity is extremely frequent. A very great variety of irregularity is shown under this circumstance, the pulse being sometimes very rapid in consequence of long series of premature beats, or extremely slow in consequence of premature systoles being too weak to affect the radial pulse, and again all forms of irregularity may follow one another with great rapidity.

Hemisystole is of rare occurrence, and it is impossible to recognise it except by obtaining graphic records of the movements caused by the circulation. Other rare forms of irregularity can only be correctly appreciated by means of graphic records.





# INDEX


	PAGE		PAGE
Adult type of Pulse irregularity	87, 262	Chloroform and the Pulse	114
Angina pectoris	76, 78, 292	Circulation, the object of the	47
Apex beat	30	Dicrotism	24
"    "    due to the right ventricle	39	Digitalis poisoning, Pulses in	304
"    "    interpretation of a tracing	32	Dilatation of the Heart, acute, in	
"    "    of the	32	mitral disease	244
Arhythmic contraction of the cardiac		"    in muscle failure	245
cavities	315	"    "    paroxysmal tachy-	
Arterial pressure	64	cardia	251
"    "    cause of increased	70	"    symptoms of	244
"    "    causes of	67	Dropped beat	95
"    "    Pulse in increased	69	Epigastric pulsation	37
"    "    Pulse in lowered	79	Exophthalmic goitre	122
"    "    recurrent high	71	Extra systole	90
"    "    standard of	68	Fever, Pulse in ( <i>see</i> Pulse)	112
"    "    symptoms associ-		Gout, arterial pressure in	72
ated with increased	73	Heart irregularities ( <i>see</i> Pulse Irregu-	
"    "    symptoms associ-		larities)	83, 257
ated with lowered	81	Heart movements	29
"    Pulse, digital examination of	63	"    "    cause of epigastric	
Arteries, condition of walls of	64	pulsation	37
"    constitution of	48	"    "    change from apex	
"    inspection of	63	beat due to left	
Auricle, hypertrophy of the	196	ventricle to one	
"    paralysis of the	209, 310	due to the right	
"    pressure in the	184	ventricle	41
Auricular Venous Pulse ( <i>see</i> Venous		"    "    nature of the	30
Pulse)	197	"    "    results of cardiac	
Blood as affecting the Pulse	50	aspiration	35
"    diminished in old age	57	"    "    shock due to the	
Bradycardia ( <i>see</i> Slow Pulse)	135	ventricular systole	44
Bright's Disease, arterial pressure		Hemisystole	291
in	70, 72, 73	"    with the auricles active	292
Capillary circulation, inspection of	58	"    "    "    para-	
"    field diminished in old age	57	lysed	294
Cardiac cycle, description of events	17, 181	Hepatic congestion	222
Cardiogram, clinical significance of	44	Hyperdicrotism	26
"    inverted	42	Infant's radial artery	55
Carotid Pulse, effect of, on jugular		Instruments	8
tracings	197		
Characteristic Pulses	149		

	PAGE		PAGE
Jugular Pulse ( <i>see</i> Venous Pulse).		Pulse, in advanced life . . . . .	56
"  "  inspection of . . . . .	179	"  "  ague . . . . .	137
"  "  valves, competence of . . . . .	178	"  "  aortic aneurysm . . . . .	155
Liver, congestive enlargement of the	221	"  "  "  regurgitation . . . . .	149
"  "  enlargement and pulsation of		"  "  "  stenosis . . . . .	153
"  "  the . . . . .	220	"  "  asthenic fever . . . . .	140
"  "  movements due to cardiac		"  "  atheroma of the arteries . . . . .	158
"  "  aspiration . . . . .	36	"  "  blocking of the lumen of	
"  "  pulse, absent in muscle failure	195	"  "  an artery . . . . .	157
"  "  auricular type sign of		"  "  febrile conditions . . . . .	137, 146
"  "  tricuspid stenosis . . . . .	195	"  "  mitral disease . . . . .	161, 285
"  "  differential diagnosis of		"  "  pneumonia . . . . .	145
"  "  the . . . . .	225	"  "  sthenic fever . . . . .	138
"  "  in congestive enlarge-		"  "  syncope . . . . .	81
"  "  ment . . . . .	222	"  "  increased frequency . . . . .	117
"  "  two forms of . . . . .	223	"  "  in affections of the myo-	
"  "  when established more		"  "  cardium . . . . .	120
"  "  constant than jugular	187	"  "  alcoholics . . . . .	121
Nerves of the Arteries . . . . .	49	"  "  exhausting diseases . . . . .	122
"  "  Heart . . . . .	48	"  "  exophthalmic goitre . . . . .	122
Ostial Veins, incompetence of the . . . . .	177	"  "  neurotic cases . . . . .	121
Palpitation . . . . .	123	"  "  palpitation . . . . .	123
Paralysis of the auricles . . . . .	209, 310	"  "  paroxysmal tachycardia . . . . .	124
Paroxysmal tachycardia . . . . .	124, 251	"  "  pregnancy . . . . .	121
Periods of life . . . . .	51	Pulse Irregularities . . . . .	83, 257
Polygraph . . . . .	10	"  "  adult type . . . . .	87, 262
Postsphygmic period . . . . .	17, 218	"  "  after fever . . . . .	86
Pregnancy, arterial pressure in . . . . .	72	"  "  "  middle age . . . . .	110
"  "  irregular Pulse in . . . . .	108	"  "  auscultation of	
"  "  prognostic value of ven-		"  "  the heart during . . . . .	92
"  "  ous and Liver Pulses in . . . . .	243	"  "  and chloroform . . . . .	114
"  "  Pulse in . . . . .	121	"  "  causes of . . . . .	297
"  "  venous Pulse in . . . . .	231	"  "  clinical signifi-	
Premature systole . . . . .	92, 297	"  "  cance of . . . . .	106
Presphygmic period . . . . .	17, 215	"  "  descriptive terms	
Pressure, relations of arterial, to		"  "  83, 259	
"  "  ventricular . . . . .	16	"  "  distinction be-	
"  "  relations of venous to		"  "  tween youthful	
"  "  auricular . . . . .	184	"  "  and adult types . . . . .	90
"  "  relations of venous to		"  "  estimation of	
"  "  arterial . . . . .	313	"  "  value of . . . . .	116
Presystolic murmur absent in auricu-		"  "  exceptional forms	
"  "  lar paralysis . . . . .	212	"  "  of . . . . .	102
Pulmonary artery, tracings of . . . . .	32, 290	"  "  indigitalis poison-	
Pulsation, epigastric . . . . .	37	"  "  ing . . . . .	304
"  "  in peripheral Veins . . . . .	176	"  "  in failing heart . . . . .	111
"  "  venous ( <i>see</i> Venous Pulse).		"  "  in fever . . . . .	112
Pulse, alleged delay in aortic re-		"  "  in hard work . . . . .	110
"  "  gurgitation . . . . .	150	"  "  in mental affec-	
"  "  alone not a safe guide . . . . .	3	"  "  tions . . . . .	111
"  "  and respiration . . . . .	163	"  "  in pregnancy . . . . .	108
"  "  dropped beat . . . . .	95	"  "  in pneumonia . . . . .	112
"  "  effects of ingestion of food . . . . .	54	"  "  misconception of	
"  "  of mental or muscular		"  "  symptoms of . . . . .	106
"  "  effort . . . . .	54	"  "  participation of	
"  "  of temperature . . . . .	54	"  "  heart chambers	
"  "  how the arteries affect the . . . . .	48	"  "  in . . . . .	98, 260
		"  "  predisposition to	
		"  "  with Auricles act-	
		"  "  ing regularly . . . . .	268
		"  "  with inhibition of	
		"  "  the Ventricles . . . . .	279



	PAGE		PAGE
Pulse irregularities with paralysis of the Auricles . . . . .	285	Venous and arterial pressure, re- lationship of . . . . .	313
"    "    youthful type . . . . .	84, 261	Venous Pulse, auricular form of . . . . .	197
"    radials compared . . . . .	65	"    "    cause of . . . . .	184
"    rate . . . . .	52, 64	"    "    change of, from auricular form to ventricular . . . . .	186
"    significance of peculiarities of the . . . . .	5	"    "    change of, due to variation in rate . . . . .	201
"    The, what is it? . . . . .	61	"    "    difficulty in recognis- ing . . . . .	228
"    wave . . . . .	65	"    "    in adherent peri- cardium . . . . .	318
Pulsus alternans . . . . .	94	"    "    in anaemia . . . . .	230
"    bigeminus . . . . .	90	"    "    in degeneration of Heart muscle . . . . .	234
"    bisferiens . . . . .	154	"    "    in exhausting diseases . . . . .	232
"    celer . . . . .	65	"    "    in fatty loaded Heart . . . . .	232
"    durus . . . . .	64	"    "    in muscle failure . . . . .	195, 236
"    mollis . . . . .	64	"    "    in paroxysmal tachy- cardia . . . . .	251
"    paradoxus . . . . .	171	"    "    in pregnancy . . . . .	231, 243
"    tardus . . . . .	65	"    "    recognition of events in a . . . . .	181
Response, cardiac field . . . . .	4	"    "    in recoverable condi- tions . . . . .	230
Slow Pulse . . . . .	135	"    "    represents the auricular pressure . . . . .	184
"    "    due to inhibition of the Ventricle . . . . .	136, 279	"    "    significant of cardiac dilatation . . . . .	229
"    "    due to missed beats 97, 136, 213, 288	288	"    "    ventricular form . . . . .	209
"    "    normal . . . . .	133, 201	"    "    what it shows . . . . .	175
Sounds produced by valves in the veins . . . . .	178, 252	Venous and liver Pulse, cases illus- trating changes in . . . . .	188
Sphygmogram, definition of the . . . . .	16	"    clinical significance of . . . . .	228
"    features due to in- strumental defect . . . . .	20	"    conditions giving rise to the constitution of the . . . . .	181
"    interpretation of a . . . . .	16	"    difference between the . . . . .	224
Sphygmograph . . . . .	8	"    grouping of cases . . . . .	229
Stasis in the Liver . . . . .	217	"    in mitral disease . . . . .	242
"    "    Veins . . . . .	200, 217	"    in pregnancy . . . . .	243
Tricuspid stenosis . . . . .	196	"    two forms of . . . . .	193
"    valves, incompetence of . . . . .	177	Ventricle, apex beat due to right . . . . .	39
Vagus influence in Pulse irregulari- ties . . . . .	301, 302	"    period of contraction . . . . .	32
Valsalva's experiment . . . . .	165	"    "    of filling . . . . .	32
Vasomotor angina pectoris . . . . .	78	"    "    of outflow . . . . .	33
Veins, incompetence of ostial . . . . .	177	"    "    of relaxation . . . . .	34
"    Inspection of . . . . .	59	"    retraction of yielding structures in neigh- bourhood . . . . .	35
"    movement of blood in the . . . . .	176	Youthful type of irregularity . . . . .	84, 261
"    nature of the Waves in the . . . . .	308		
Vena cava, relation of the, to the venous flow . . . . .	177-		









CATALOGUE  
OF  
YOUNG J. PENTLAND'S  
PUBLICATIONS.

EDINBURGH: 11 TEVIOT PLACE.  
LONDON: 38 WEST SMITHFIELD, E.C.

MARCH 1901.





# CATALOGUE

OF

## MEDICAL PUBLICATIONS

ISSUED BY

**YOUNG J. PENTLAND,**  
EDINBURGH and LONDON.

---

**Aitchison, Robert S., M.B., C.M., F.R.C.P.Ed.,**

Visiting Physician, St. Cuthbert's Poorhouse Hospital, Edinburgh.

SYNOPSIS OF THERAPEUTICS. Arranged for the use of Prescribers. With Posological Table and an arrangement of the Poisons. 18mo, cloth, pp. xii., 120. Price 3s.

**Alexander, William, M.D., F.R.C.S.,**

Honorary Surgeon, Royal Southern Hospital, Liverpool; Visiting Surgeon, Liverpool Workhouse Hospital; Acting Honorary Consulting Surgeon, Epileptic Institution, Manor House, Maghull.

THE TREATMENT OF EPILEPSY. 8vo, cloth, pp. x., 220, with 9 illustrations. Price 7s. 6d.

**Anderson, M'Call, M.D., F.F.P.S.(Glasg.),**

Professor of Medicine in the University of Glasgow; Physician, Glasgow Western Infirmary.

CONTRIBUTIONS TO CLINICAL MEDICINE. 8vo, cloth, pp. xii., 416, with 28 illustrations. Price 10s. 6d. nett.

**Behrens, Dr. W. J.**

TEXT-BOOK OF GENERAL BOTANY. Translation from the Second German Edition. Revised by PATRICK GEDDES, F.R.S.E., Professor of Botany in the University of Dundee. 8vo, cloth, pp. viii., 374, with 408 illustrations, finely engraved on wood, and 4 analytical tables. *New and cheaper edition.* Price 5s.

**Berry, George A., M.B., F.R.C.S.Ed.,**

Ophthalmic Surgeon, Edinburgh Royal Infirmary; Senior Surgeon, Edinburgh Eye Dispensary; Lecturer on Ophthalmology, University of Edinburgh.

**DISEASES OF THE EYE.** A Practical Treatise for Students of Ophthalmology. Second Edition, revised and enlarged. 8vo, cloth, pp. xxiv., 728, with 197 illustrations, including many coloured figures from original drawings. Price 25s. (*Pentland's Medical Series, Volume Second.*)

**THE ELEMENTS OF OPHTHALMOSCOPIC DIAGNOSIS.** For the use of Students attending Ophthalmic Practice. Crown 8vo, cloth, pp. xii., 83. Price 3s. 6d.

**Billings, John S., A.M., M.D., LL.D., (Harv. and Edin.), D.C.L. (Oxon.),**

Member of the National Academy of Sciences, Surgeon, U.S.A., etc.

**THE NATIONAL MEDICAL DICTIONARY.** Including English, French, German, Italian, and Latin Technical Terms used in Medicine and the Collateral Sciences, and a Series of Tables of useful data. In two volumes, Imperial 8vo, pp. xlvi., 1530. Price 50s. nett.

**Bramwell, Byrom, M.D., F.R.C.P.Ed.,**

Lecturer on the Principles and Practice of Medicine, and on Practical Medicine and Medical Diagnosis, in the Extra-Academical School of Medicine, Edinburgh; Physician, Edinburgh Royal Infirmary.

**DISEASES OF THE HEART AND THORACIC AORTA.** Large 8vo, cloth, pp. xvi., 783. Illustrated with 226 wood engravings, and 68 pages of lithograph plates, exhibiting 91 figures—317 illustrations in all. Price 25s.

**INTRACRANIAL TUMOURS.** 8vo, cloth, pp. xvi., 270, with 116 illustrations. Price 14s.

**Brockbank, Edward Mansfield, M.D., M.R.C.P.,**

Honorary Physician, Ancoats Hospital, Manchester.

**THE MURMURS OF MITRAL DISEASE.** 8vo, cloth, pp. viii., 48, with 5 illustrations. Price 3s. 6d.

**Bruce, Alexander, M.D., F.R.C.P.Ed.,**

Lecturer on Neurology in the School of Medicine, Edinburgh; Assistant Physician (formerly Pathologist), Edinburgh Royal Infirmary; Pathologist to the Royal Hospital for Sick Children.

**ILLUSTRATIONS OF THE NERVE TRACTS IN THE MID AND HIND BRAIN AND THE CRANIAL NERVES ARISING THEREFROM.** Royal 4to. Illustrated with a series of 27 coloured plates from original drawings, and numerous figures throughout the text. Price 50s. nett.

**Bruce, J. Mitchell, M.A., M.D., F.R.C.P.,**

Physician and Lecturer on the Principles and Practice of Medicine, Charing Cross Hospital; Consulting Physician to the Consumption Hospital, Brompton; Examiner in Medicine, University of Cambridge.

THE PRINCIPLES OF TREATMENT AND THEIR APPLICATIONS IN PRACTICAL MEDICINE. 8vo, cloth, gilt top, pp. xvi., 614. Price 16s. (*Pentland's Medical Series, Volume Seventh.*)

**Bruen, E. T., M.D.,**

Assistant Professor of Physical Diagnosis, University of Pennsylvania; one of the Physicians to the Philadelphia and University Hospitals.

OUTLINES FOR THE MANAGEMENT OF DIET; or, The Regulation of Food to the Requirements of Health and the Treatment of Disease. Crown 8vo, cloth, pp. 138. Price 4s. 6d.

**Burnett, Charles Henry, A.M., M.D.,**

Aural Surgeon to the Presbyterian Hospital; one of the Consulting Aurists to the Pennsylvania Institution for the Deaf and Dumb; Lecturer on Otology, Women's Medical College of Pennsylvania, Philadelphia.

DISEASES AND INJURIES OF THE EAR: their Prevention and Cure. Crown 8vo, cloth, pp. 154, with 5 illustrations. Price 4s. 6d.

**Carmichael, James, M.D., F.R.C.P.Ed.,**

Physician, Royal Hospital for Sick Children; University Lecturer on Disease in Children, Edinburgh.

DISEASE IN CHILDREN: a Manual for Students and Practitioners. Crown 8vo, cloth, pp. xvi., 591. Illustrated with charts. Price 10s. 6d. (*Pentland's Students' Manuals.*)

**Cheyne, W. Watson, F.R.S., F.R.C.S.,**

Professor of Surgery, King's College; Surgeon to King's College Hospital, and Paddington Green Children's Hospital, London.

TUBERCULOUS DISEASE OF BONES AND JOINTS: Its Pathology, Symptoms, and Treatment. 8vo, cloth, pp. xvi., 374. Illustrated with numerous wood engravings throughout the text. Price 14s. nett.

THE TREATMENT OF WOUNDS, ULCERS, AND ABSCESSSES. Second Edition. Crown 8vo, cloth, pp. xvi., 197. Price 3s. 6d.



SUPPURATION AND SEPTIC DISEASES. Three Lectures delivered at the Royal College of Surgeons of England. 8vo, cloth, pp. xii., 102, with 4 illustrations. Price 5s.

### **Crocker, H. Radcliffe, M.D., F.R.C.P.,**

Physician to the Department for Diseases of the Skin, University College Hospital, London.

ATLAS OF THE DISEASES OF THE SKIN. In a series of Illustrations from Original Drawings with Descriptive Letterpress. Complete in Sixteen Fasciculi, containing 96 plates, exhibiting 238 figures printed in colours, from original drawings specially prepared for the work. Price 21s. each Fasciculus. Sold only by subscription. Also in 2 vols., handsomely bound in half morocco, gilt tops, the plates mounted on linen guards,—Price 18 Guineas nett.

### **“Compend” Series, The.**

**A Series of Handbooks to assist Students preparing for Examinations.**

COMPEND OF HUMAN ANATOMY, INCLUDING THE ANATOMY OF THE VISCERA. By SAMUEL O. L. POTTER, M.D., M.R.C.P. (Lond.), Cooper Medical College, San Francisco. Sixth Edition, revised and enlarged. Crown 8vo, cloth, pp. 289, with 117 engravings and 16 full-page plates. Price 5s.

COMPEND OF OBSTETRICS. By HENRY G. LANDIS, A.M., M.D., late Professor of Obstetrics and Diseases of Women in Starling Medical College. Fourth Edition. Crown 8vo, cloth, pp. 118, with 17 illustrations. Price 4s. 6d.

COMPEND OF DISEASES OF CHILDREN. By MARCUS P. HATFIELD, A.M., M.D., Professor of Diseases of Children, Chicago Medical College. Crown 8vo, cloth, pp. 186, with coloured plate. Price 4s. 6d.

COMPEND OF GENERAL PATHOLOGY AND MORBID ANATOMY. By H. NEWBERY HALL, PH.G., M.D., Professor of Pathology and Medical Chemistry, Post-Graduate Medical School; Surgeon to the Emergency Hospital, etc., Chicago. Crown 8vo, cloth, pp. 204, with 91 illustrations. Price 4s. 6d.

COMPEND OF DENTAL PATHOLOGY AND DENTAL MEDICINE. By GEO. W. WARREN, D.D.S., Clinical Chief, Pennsylvania College of Dental Surgery. Crown 8vo, cloth, pp. 109. With 4 illustrations. Price 4s. 6d.

## Cunningham, D. J., M.D., F.R.S.,

Professor of Anatomy and Chirurgery, Trinity College, Dublin.

MANUAL OF PRACTICAL ANATOMY. Second Edition. In 2 vols., crown 8vo, cloth, illustrated with 372 wood engravings, and 2 coloured plates. Vol. I.—Upper Limb, Lower Limb, Abdomen; Vol. II.—Thorax, Head and Neck. Price per volume, 12s. 6d. (*Pentland's Students' Manuals.*)

TEXT-BOOK OF ANATOMY. By BRITISH TEACHERS. Edited by D. J. CUNNINGHAM, M.D., F.R.S., Professor of Anatomy and Chirurgery, Trinity College, Dublin. In one volume, royal 8vo, with 700 engravings from original drawings. *In press.* The articles are contributed by Professor A. H. YOUNG (Manchester), Dr. ARTHUR ROBINSON (London), Professor ARTHUR THOMSON (Oxford), Dr. D. H. HEPBURN and Dr. HAROLD STILES (Edinburgh), Professor A. M. PATERSON (Liverpool), Professor R. HOWDEN (Newcastle), Professor A. BIRMINGHAM (Dublin), Professor A. F. DIXON (Cardiff), and the EDITOR.

## Davidson, Andrew, M.D., F.R.C.P.Ed.,

Late Visiting and Superintending Surgeon, Civil Hospital; Professor of Chemistry, Royal College, Mauritius.

GEOGRAPHICAL PATHOLOGY. An inquiry into the Geographical Distribution of Infective and Climatic Diseases. In 2 vols., large 8vo, cloth, pp. xvi., 1006. Illustrated with maps and charts. Price 31s. 6d.

HYGIENE AND DISEASES OF WARM CLIMATES. In a Series of Articles by Eminent Authorities. Edited by ANDREW DAVIDSON, M.D., F.R.C.P.Ed., Late Visiting and Superintending Surgeon, Civil Hospital; Professor of Chemistry, Royal College, Mauritius; Author of "Geographical Pathology." The Articles are contributed by Sir JOSEPH FAYRER, Drs. MACNAMARA, PATRICK MANSON, LANE NOTTER, E. A. BIRCH, R. W. COPPINGER, DAVID BRUCE, G. M. STERNBERG, MONTAGU LUBBOCK, HY. CAYLEY, PROSPERO SONSINO, THE EDITOR, etc. etc. One volume, royal 8vo, cloth, pp. xx., 1016. Illustrated with 7 full-page plates and 97 figures throughout the text. Price 31s. 6d.

**Davis, Edward P., A.M., M.D.,**

Professor of Obstetrics and Diseases of Infancy in the Philadelphia Polyclinic; Clinical Professor of Obstetrics, Jefferson Medical College, Philadelphia.

A TREATISE ON OBSTETRICS FOR STUDENTS AND PRACTITIONERS. Large 8vo, cloth, pp. 553, illustrated with 217 engravings and 30 plates in colours and monochrome. Price 16s. nett.

**Dercum, Francis X., A.M., M.D., Ph.D.,**

Clinical Professor of Nervous Diseases, Jefferson Medical College, Philadelphia; President of the American Neurological Association.

A TEXT-BOOK ON NERVOUS DISEASES. By American Authors. Royal 8vo, cloth, pp. xvi., 1056. Illustrated with 341 engravings and 7 coloured plates. Price 25s. nett.

\* \* The list of contributors includes the following well-known names :—

N. E. BRILL, M.D.	JAMES HENDRIE LLOYD, M.D.
CHARLES W. BURR, M.D.	CHARLES K. MILLS, M.D.
JOSEPH COLLINS, M.D.	S. WEIR MITCHELL, M.D., LL.D.
CHARLES L. DANA, M.D.	CHARLES A. OLIVER, M.D.
F. X. DERCUM, M.D.	WILLIAM OSLER, M.D.
E. D. FISHER, M.D.	FREDERICK PETERSON, M.D.
LANDON CARTER GRAY, M.D.	MORTON PRINCE, M.D.
C. A. HERTER, M.D.	G. E. DE SCHWEINITZ, M.D.
GEORGE W. JACOBY, M.D.	WHARTON SINKLER, M.D.
W. W. KEEN, M.D., LL.D.	M. ALLEN STARR, M.D.
PHILIP COOMBS KNAPP, M.D.	JAMES C. WILSON, M.D.

**De Schweinitz, G. E., A.M., M.D.,**

Professor of Ophthalmology in the Philadelphia Polyclinic; Clinical Professor of Ophthalmology in the Jefferson Medical College, Philadelphia.

TOXIC AMBLYOPIAS; their Classification, History, Symptoms, Pathology, and Treatment. Royal 8vo, cloth, pp. 238, with 46 figures in the text, and 9 full-page plates. Price 16s. nett.



## Edinburgh Medical Journal.

Edited by G. A. GIBSON, M.D., D.Sc., F.R.C.P.Ed., Physician, Edinburgh Royal Infirmary.

*Assisted in Special Departments by—*

- A. LOCKHART GILLESPIE, M.D., F.R.C.P.Ed., Medical Registrar, Edinburgh Royal Infirmary (*Medicine*).
- ALEXIS THOMSON, M.D., F.R.C.S.Ed., Assistant Surgeon, Edinburgh Royal Infirmary (*Surgery*).
- FRANCIS W. N. HAULTAIN, M.D., F.R.C.P.Ed., Physician for Diseases of Women, Deaconess Hospital, Edinburgh (*Obstetrics and Gynaecology*).
- RALPH STOCKMAN, M.D., F.R.C.P.Ed., Professor of Materia Medica in the University of Glasgow (*Therapeutics*).
- R. F. C. LEITH, M.A., M.B., B.Sc., F.R.C.P.Ed., Professor of Pathology, Mason University College, Birmingham (*Pathology*).
- D. J. CUNNINGHAM, M.D., D.Sc., F.R.S., LL.D., D.C.L., Professor of Anatomy in the University of Dublin (*Applied Anatomy*).
- THOS. H. MILROY, M.D., B.Sc., Demonstrator of Physiology, University of Edinburgh (*Physiology*).
- Sir J. BATTY TUKE, M.D., D.Sc., F.R.C.P.Ed., Physician Superintendent, Saughton Hall Asylum; and J. MACPHERSON, M.D. F.R.C.P.Ed. (*Insanity*).
- W. ALLAN JAMIESON, M.D., F.R.C.P.Ed., Physician for Diseases of the Skin, Edinburgh Royal Infirmary (*Diseases of the Skin*).
- P. M'BRIDE, M.D., F.R.C.P.Ed., Aural Surgeon and Laryngologist, Edinburgh Royal Infirmary; and A. LOGAN TURNER, M.D., F.R.C.S.Ed., Surgeon for Diseases of Ear and Throat, Deaconess Hospital, Edinburgh (*Diseases of the Ear, Throat, and Nose*).
- GEORGE A. BERRY, M.B., F.R.C.S.Ed., Ophthalmic Surgeon, Edinburgh Royal Infirmary; and W. G. SYM, M.D., F.R.C.S.Ed., Senior Assistant Ophthalmic Surgeon, Edinburgh Royal Infirmary (*Diseases of the Eye*).
- G. H. MELVILLE DUNLOP, M.D., F.R.C.P.Ed., Extra Physician, Royal Hospital for Sick Children, Edinburgh (*Diseases of Children*).
- C. HUNTER STEWART, M.B., D.Sc., F.R.S.E., Professor of Public Health, University of Edinburgh (*Public Health*).
- HARVEY LITTLEJOHN, M.A., B.Sc., M.B., F.R.C.S.Ed., Lecturer on Medical Jurisprudence, Surgeons' Hall, Edinburgh (*Medical Jurisprudence*).

The Volumes begin with the Issues for January and July.

*Subscription One Guinea per annum (in advance) post free. For the Colonies and Abroad, Twenty-four Shillings per annum (in advance) post free. Single Numbers Two Shillings each.*

**Felkin, R. W., M.D., F.R.S.E., F.R.G.S.,**

Formerly Lecturer on Diseases of the Tropics and Climatology, School of Medicine, Edinburgh.

**GEOGRAPHICAL DISTRIBUTION OF SOME TROPICAL DISEASES AND THEIR RELATION TO PHYSICAL PHENOMENA.** 8vo, cloth, pp. 54. Illustrated with 16 coloured maps. Price 5s.

**Frost, W. Adams, F.R.C.S.,**

Ophthalmic Surgeon and Lecturer on Ophthalmic Surgery, St. George's Hospital; Surgeon, Royal Westminster Ophthalmic Hospital, London.

**THE FUNDUS OCULI**, with an Ophthalmoscopic Atlas, illustrating its Physiological and Pathological Conditions. In one handsome 4to volume, extra cloth, gilt top, with 47 plates, exhibiting 107 beautifully coloured figures, and numerous engravings in the text. Price 63s. nett.

**Fuller, Eugene, M.D.,**

Instructor in Genito-Urinary and Venereal Diseases, Post-Graduate Medical School, New York.

**DISORDERS OF THE MALE SEXUAL ORGANS.** Large 8vo, cloth, pp. 242. Illustrated with 8 plates and 25 figures in the text. Price 9s.

**Gibbes, Heneage, M.D.,**

Professor of Pathology in the University of Michigan; formerly Lecturer on Histology in the Medical School, Westminster Hospital.

**PRACTICAL PATHOLOGY AND MORBID HISTOLOGY.** 8vo, cloth, pp. 362. Illustrated with 60 photographic reproductions. Price 12s. 6d.

**Gibson, G. A., M.D., D.Sc., F.R.C.P.Ed.,**

Lecturer on the Principles and Practice of Medicine in the Edinburgh Medical School; Physician, Edinburgh Royal Infirmary.

**DISEASES OF THE HEART AND AORTA.** 8vo, cloth, pp. xxiv., 932. Illustrated with 210 figures in the text. Price 24s. (*Pentland's Medical Series, Volume Sixth.*)

**TEXT-BOOK OF MEDICINE.** By British Teachers. Edited by G. A. GIBSON, M.D., D.Sc., F.R.C.P.Ed. 2 vols. Royal 8vo, each pp. xxiv., 872, with 122 illustrations. *Just ready.*

\* \* \* The list of Contributors is as follows:—J. O. AFFLECK, HENRY ASHBY, A. G. AULD, JOHN ROSE BRADFORD, ALEXANDER BRUCE,

J. MITCHELL BRUCE, SIR LAUDER BRUNTON, W. S. COLMAN, G. A. GIBSON, A. LOCKHART GILLESPIE, SIR WILLIAM GOWERS, V. D. HARRIS, HERBERT P. HAWKINS, W. ALLAN JAMIESON, the late A. A. KANTHACK, CLAUDE B. KER, T. W. P. LAWRENCE, A. P. LUFF, HECTOR MACKENZIE, PATRICK MANSON, SIDNEY MARTIN, SIR JOHN WILLIAM MOORE, F. W. MOTT, THOMAS OLIVER, W. PASTEUR, R. W. PHILIP, S. RISIEN RUSSELL, WILLIAM RUSSELL, RALPH STOCKMAN, FREDERICK TAYLOR, JAMES TAYLOR, W. ALDREN TURNER, W. HALE WHITE, R. T. WILLIAMSON, G. E. CARTWRIGHT WOOD, G. SIMS WOODHEAD.

### **Gibson, G. A., M.D., D.Sc., F.R.C.P.Ed.,**

Lecturer on the Principles and Practice of Medicine in the Edinburgh Medical School; Physician, Edinburgh Royal Infirmary;

and

### **Russell, William, M.D., F.R.C.P.Ed.,**

Assistant Physician, Edinburgh Royal Infirmary; Lecturer on Pathology and Morbid Anatomy, School of Medicine, Edinburgh.

**PHYSICAL DIAGNOSIS.** A Guide to Methods of Clinical Investigation. Third Edition, revised and enlarged. Edited by FRANCIS D. BOYD, Assistant Physician, Royal Infirmary, Edinburgh. Crown 8vo, pp. xvi., 376, with many illustrations. (*Pentland's Students' Manuals.*) *In press.*

### **Graham, James, M.A., M.D.,**

Late Demonstrator of Anatomy, Sydney University; Medical Superintendent, Prince Alfred Hospital, Sydney.

**HYDATID DISEASE IN ITS CLINICAL ASPECTS.** 8vo, cloth, pp. xvi., 204, with 34 full-page coloured plates. Price 16s.

### **Hall, H. Newbery, Ph.G., M.D.,**

Professor of Pathology and Medical Chemistry, Post-Graduate Medical School; Surgeon to the Emergency Hospital, etc., Chicago.

**COMPEND OF PATHOLOGY AND MORBID ANATOMY.** Crown 8vo, cloth, pp. 204, with 91 illustrations. Price 4s. 6d.

### **Hare, Hobart Amory, M.D., B.Sc.,**

Professor of Therapeutics and Materia Medica, Jefferson Medical College, Philadelphia.

**SYSTEM OF PRACTICAL THERAPEUTICS.** By Various Authors. Edited by HOBART AMORY HARE, M.D. In 6 volumes, royal 8vo, cloth, of about 500 pages each. Price per volume, 12s. 6d. nett, carriage free.

Supplement, bringing the work up to date, in two volumes, royal 8vo, cloth. Price 25s. nett, carriage free.



**Hatfield, Marcus P., A.M., M.D.,**

Professor of Diseases of Children, Chicago Medical College.

COMPEND OF DISEASES OF CHILDREN. Crown 8vo, cloth, pp. 186, with coloured plate. Price 4s. 6d.

**Haultain, F. W. N., M.D., F.R.C.P.Ed.,**

Lecturer on Midwifery and Diseases of Women, School of Medicine; Physician for Diseases of Women, Deaconess' Hospital; Obstetric and Gynecological Physician, Royal Dispensary, Edinburgh; and

**Ferguson, J. Haig, M.D., F.R.C.P.Ed.,**

Lecturer on Midwifery and Diseases of Women, School of Medicine and Jubilee Institute for Nurses.

HANDBOOK OF OBSTETRIC NURSING. Third Edition, revised and enlarged. Crown 8vo, cloth, pp. xvi., 263. Illustrated with coloured plate and 37 wood engravings. Price 5s.

**Hayem, Georges, M.D.,**

Professor of Clinical Medicine in the Faculty of Medicine of Paris.

PHYSICAL AND NATURAL THERAPEUTICS: the Remedial Uses of Atmospheric Pressure, Climate, Heat and Cold, Hydrotherapeutic Measures, Mineral Waters, and Electricity. Edited by HOBART AMORY HARE, M.D., Professor of Therapeutics and Materia Medica, Jefferson Medical College, Philadelphia. Large 8vo, cloth, pp. 426, with 113 illustrations in the text. Price 14s.

**Hirst, Barton Cooke, M.D.,**

Professor of Obstetrics in the University of Pennsylvania; and

**Piersol, George A., M.D.,**

Professor of Embryology and Histology in the University of Pennsylvania.

HUMAN MONSTROSITIES. In handsome folio, containing about 230 pages of text, illustrated with engravings and 39 full-page photographic plates from Nature. In four fasciculi. Price 25s. each nett, carriage free. The edition is limited, and is for sale only by subscription.

**Holland, J. W., M.D.,**

Professor of Medical Chemistry and Toxicology, Jefferson Medical College, Philadelphia.

THE URINE AND THE COMMON POISONS, MEMORANDA, CHEMICAL AND MICROSCOPICAL, FOR LABORATORY USE. Second Edition, revised and enlarged. Oblong crown 8vo, cloth, pp. 65, with 28 illustrations. Price 4s.

**Hygiene and Diseases of Warm Climates.**

(See DAVIDSON.)

**Jamieson, W. Allan, M.D., F.R.C.P.Ed.,**

Physician for Diseases of the Skin, Edinburgh Royal Infirmary; Lecturer on the Diseases of the Skin, University of Edinburgh.

**DISEASES OF THE SKIN.** A Manual for Students and Practitioners. Fourth Edition, revised and enlarged. 8vo, cloth, pp. xx., 660, with 9 coloured illustrations. Price 21s. (*Pentland's Medical Series, Volume First.*)

**Johnstone, Alexander, F.G.S.,**

Lecturer on Botany, School of Medicine, Edinburgh.

**BOTANY.** A Concise Manual for Students of Medicine and Science. Crown 8vo, cloth, pp. xvi., 260, with 164 illustrations and a series of floral diagrams. Price 6s. (*Pentland's Students' Manuals.*)

**Journal of Pathology and Bacteriology.**

Edited, with the Collaboration of Distinguished British and Foreign Pathologists, by GERMAN SIMS WOODHEAD, M.D., Professor of Pathology in the University of Cambridge; Assisted in Special Departments by Allan Macfadyen, M.D., Sidney Martin, M.D. (Lond.) (*Pathological Chemistry*); S. G. Shattock, F.R.C.S. (*Morbid Anatomy and Histology*); G. E. Cartwright Wood, M.D. (Edin.) (*Bacteriology*). Subscription, One Guinea per annum (in advance), post free. Volumes I. to VI. in extra cloth binding. Price 25s. each nett.

---

It has been felt for some time that the want in this country of a Journal dealing specially with General and Experimental Pathology has militated most seriously against the free interchange of ideas, not only between English-speaking pathologists, but also between British and Foreign workers.

Although the Transactions of the Pathological Society deal with communications which are brought before its members, there is no medium in which longer articles, and especially those from workers throughout the United Kingdom and abroad, can be brought

before a less limited circle of readers. It has been thought desirable, therefore, to found a journal specially devoted to the publication of original contributions to General Pathology, Pathological Anatomy, and Experimental Pathology, including Bacteriology. These articles will, of course, be mainly from British Laboratories and Hospitals; but the co-operation of many distinguished Continental, American, and Colonial Pathologists has been obtained, and papers written or edited by them will be placed before our readers.

In order to increase the interest and extend the usefulness of the Journal, it is intended that, in addition to original articles, critical summaries of work done in special departments of Pathology and Bacteriology shall from time to time be published. All articles appearing in the Journal will be signed.

The Journal appears at least four times a year, but it will be issued more frequently if necessary, in order to ensure publication of all papers as early as possible after they are received.

The numbers issued throughout the year form a volume, royal 8vo, of about 500 pages. They are printed on good paper, and freely illustrated with Chromo-lithographs and figures in black and white.

Amongst those who collaborate are the following:—J. G. Adami, Montreal; S. Arloing, Lyons; B. Bang, Copenhagen; Ch. Bouchard, Paris; R. Boyce, Liverpool; J. Rose Bradford, London; H. Buchner, Munich; Sir Charles Cameron, Dublin; Angelo Celli, Rome; A. Chantemesse, Paris; A. B. Charrin, Paris; A. Chauveau, Paris; W. Watson Cheyne, London; H. Chiari, Prague; W. T. Councilman, Boston; D. D. Cunningham, Calcutta; S. Delépine, Manchester; J. Dreschfeld, Manchester; D. Drummond, Newcastle; Von Esmarch, Koenigsberg; Ch. Firket, Liège; R. H. Fitz, Boston; P. Grawitz, Greifswald; W. S. Greenfield, Edinburgh; E. H. Hankin, Agra; Victor Horsley, London; F. Hueppe, Prague; O. Israel, Berlin; Alfred Lingard, Poonah; Lord Lister, London; O. Lubarsch, Rostock; P. Marie, Paris; E. Metchnikoff, Paris; F. W. Mott, London; Robert Muir, Glasgow; E. Nocard, Alfort; T. Oliver, Newcastle; J. Orth, Göttingen; William Osler, Baltimore; J. F. Payne, London; T. Mitchell Prudden, New York; J. M. Purser, Dublin; J. C. Salomonsen, Copenhagen; Sir J. Burdon Sanderson, Oxford; C. S. Sherrington, Liverpool; J. Lorrain Smith, Belfast; A. M. Stalker, Dundee; H. Stilling, Lausanne; I. Straus, Paris; T. P. Anderson Stuart, Sydney; R. Thoma, Dorpat; E. Trevelyan, Leeds; Sir John Batty Tuke, Edinburgh; L. Vaillard, Paris; Rudolf Virchow, Berlin; H. Marshall Ward, Cambridge; A. Weichselbaum, Vienna; C. Weigert, Frankfort a/M; W. H. Welch, Baltimore; Sir Samuel Wilks, Bart., London; A. E. Wright, Netley; Von Zenker, Erlangen; E. Ziegler, Freiburg.



**Keating, John M., M.D., LL.D.,**

Fellow of the College of Physicians of Philadelphia; late Visiting Obstetrician to the Philadelphia Hospital, and Lecturer on Diseases of Women and Children, Philadelphia Hospital.

A NEW PRONOUNCING DICTIONARY OF MEDICAL TERMS. *New Impression.* Large 8vo, cloth, pp. 818. Price 7s. 6d. nett.

**Keating, John M., M.D., LL.D.,**

and

**Coe, Henry C., M.D., M.R.C.S.,**

Professor of Gynæcology, New York Polyclinic.

CLINICAL GYNÆCOLOGY, MEDICAL AND SURGICAL. By American Teachers. 2 vols., royal 8vo, cloth extra, gilt tops, pp. xviii., 994. Illustrated with 34 full-page plates and 377 engravings in the text. Price 25s. nett.

**Keith, Skene, F.R.C.S.Ed.,**

GYNÆCOLOGICAL OPERATIONS, EXCLUSIVE OF THOSE INTERFERING WITH THE PERITONEAL CAVITY. 8vo, cloth extra, pp. xii., 118. Illustrated with 44 figures. Price 5s. nett.

**Keith, Skene, F.R.C.S.Ed.,**

Assisted by

**Keith, George E., M.B., C.M.**

TEXT-BOOK OF ABDOMINAL SURGERY. A Clinical Manual for Practitioners and Students. 8vo, cloth, gilt top, pp. xvi., 508. With 34 illustrations. Price 16s. (*Pentland's Medical Series, Volume Fourth.*)

**Kelynack, T. N., M.D.(Vict.), M.R.C.P.(Lond.),**

Pathologist, Manchester Royal Infirmary; Demonstrator and Assistant Lecturer in Pathology, Owens College, Manchester.

RENAL GROWTHS: THEIR PATHOLOGY, DIAGNOSIS, AND TREATMENT. 8vo, cloth, pp. xvi., 269. With 96 illustrations. Price 12s. 6d. nett.

**Landis, Henry G., A.M., M.D.,**

Late Professor of Obstetrics and Diseases of Women in Starling Medical College.

COMPEND OF OBSTETRICS. Fourth Edition, thoroughly revised, enlarged, and improved. Crown 8vo, cloth, pp. 118, with 17 illustrations. Price 4s. 6d.

**Leuckart, Rudolf,**

Late Professor of Zoology and Comparative Anatomy in the University of Leipsic.

THE PARASITES OF MAN AND THE DISEASES WHICH PROCEED FROM THEM. A Text-Book for Students and Practitioners. Translated from the German with the co-operation of the Author by WILLIAM E. HOYLE, M.A. (Oxon.), M.R.C.S., F.R.S.E., Curator of the Museums, Owens College, Manchester. Natural History of Parasites in General.—Systematic Account of the Parasites Infesting Man.—PROTOZOA.—CESTODA. Large 8vo, cloth, pp. xxviii., 772. Illustrated with 404 engravings. Price 31s. 6d.

**Lockwood, Charles Barrett, F.R.C.S.,**

Hunterian Professor, Royal College of Surgeons of England; Assistant Surgeon to St. Bartholomew's Hospital; Surgeon to the Great Northern Central Hospital, London.

TRAUMATIC INFECTION. Hunterian Lectures delivered at the Royal College of Surgeons of England. Crown 8vo, cloth, pp. xii., 138. Illustrated with 27 wood engravings in the text. Price 3s.

ASEPTIC SURGERY. Second Edition. Crown 8vo, cloth, pp. xvi., 264. Price 4s.

THE RADICAL CURE OF HERNIA, HYDROCELE, AND VARICOCELE. Crown 8vo, cloth, pp. xii., 279, with 23 illustrations. Price 4s. 6d.

**McBride, P., M.D., F.R.C.P.Ed.,**

Surgeon to the Ear and Throat Department of the Royal Infirmary; Lecturer on the Diseases of the Throat and Ear in the University, and in the School of Medicine of the Royal Colleges, Edinburgh.

DISEASES OF THE THROAT, NOSE, AND EAR. A Clinical Manual for Students and Practitioners. Third Edition, revised and partly rewritten. 8vo, cloth, pp. xvi., 744, with 46 coloured illustrations from original drawings. Price 25s. (*Pentland's Medical Series, Volume Third.*)

**Maclaren, P. H., M.D., F.R.C.S.Ed.,**

Surgeon, Edinburgh Royal Infirmary; formerly Surgeon in charge of the Lock Wards, Edinburgh Royal Infirmary; Examiner in the Royal College of Surgeons, Edinburgh.

ATLAS OF VENEREAL DISEASES. A Series of Illustrations from Original Paintings, with Descriptions of the Varied Lesions, their Differential Diagnosis and Treatment. In 10 fasciculi, price 6s. each; or complete in one handsome royal quarto volume, extra cloth, price 63s. nett.

**Maguire, Robert, M.D., F.R.C.P.,**

Physician to, and Joint Lecturer on Pathology, St. Mary's Hospital; Assistant Physician, Consumption Hospital, Brompton, London.

THE INVOLUTION OF LIFE: A Scheme of Pathology. 8vo, cloth, pp. 23. Price 1s. 6d. nett.

**Martin, Sidney, M.D., F.R.S., F.R.C.P.,**

Physician, University College Hospital; Professor of Pathology, University College, London.

FUNCTIONAL AND ORGANIC DISEASES OF THE STOMACH. 8vo, cloth, pp. xx., 506. Illustrated with 57 engravings throughout the text. Price 16s. (*Pentland's Medical Series, Volume Fifth.*)

**Mills, Charles K., M.D.,**

Professor of Mental Diseases and of Medical Jurisprudence in the University of Pennsylvania; Clinical Professor of Neurology in the Women's Medical College, Pennsylvania.

THE NERVOUS SYSTEM AND ITS DISEASES. A Practical Treatise on Neurology for the Use of Physicians and Students. Large 8vo, cloth, pp. xxx., 1056, with 459 illustrations. Price 25s.

THE NURSING AND CARE OF THE NERVOUS AND THE INSANE. Crown 8vo, cloth, pp. 147. Price 4s. 6d.

**Morison, Alexander, M.D., F.R.C.P.Ed.,  
M.R.C.P.Lond.,**

Physician in charge of Out-Patients to the Great Northern Central Hospital and the Children's Hospital, Paddington Green; Physician to the St. Marylebone General Dispensary, London.

ON THE RELATION OF THE NERVOUS SYSTEM TO DISEASE AND DISORDER IN THE VISCERA. Being the Morison Lectures delivered before the Royal College of Physicians in Edinburgh in 1897 and 1898. 8vo, cloth, gilt top, pp. xvi., 132; with 39 illustrations. Price 7s. 6d.



**Morrow, Prince A., M.D.,**

Clinical Professor of Genito-Urinary Diseases; formerly Lecturer on Dermatology in the University of the City of New York; Surgeon to Charity Hospital, New York.

SYSTEM OF GENITO-URINARY DISEASES, SYPHILOLOGY, AND DERMATOLOGY. By VARIOUS AUTHORS. Edited by PRINCE A. MORROW, M.D. In 6 divisional volumes of about 550 pages each. Royal 8vo, cloth extra, gilt tops, illustrated with coloured plates and engravings throughout the text. Price per volume, 14s. nett. Sold only by subscription.

**Muir, Robert, M.A., M.D., F.R.C.P.Ed.,**

Professor of Pathology, University of Glasgow,  
and

**Ritchie, James, M.A., M.D., B.Sc.,**

Lecturer on Pathology, University of Oxford.

MANUAL OF BACTERIOLOGY. Second Edition, revised and enlarged. Crown 8vo, cloth, pp. xx., 564, with 126 illustrations. Price 12s. 6d. (*Pentland's Students' Manuals.*)

**Murray, R. Milne, M.B., F.R.C.P.Ed.,**

Assistant Physician, Royal Maternity and Simpson Memorial Hospital; Lecturer on Midwifery and Diseases of Women, School of Medicine, Edinburgh.

MANUAL OF MIDWIFERY. Crown 8vo, with numerous illustrations, pp. 500 or thereby. *Preparing.*

**Muskett, Philip E., L.R.C.P. & S. Ed.,**

Late Surgeon to the Sydney Hospital; formerly Senior Resident Medical Officer, Sydney Hospital.

PRESCRIBING AND TREATMENT IN THE DISEASES OF INFANTS AND CHILDREN. Third Edition, revised, enlarged, and re-arranged. 18mo, pp. xx., 334, in flexible leather binding for the pocket. Price 6s. 6d.

**Musser, John H., M.D.,**

Assistant Professor of Clinical Medicine in the University of Pennsylvania; Physician to the Philadelphia and the Presbyterian Hospitals, etc.

PRACTICAL TREATISE ON MEDICAL DIAGNOSIS. For Students and Physicians. Royal 8vo, cloth, pp. viii., 866. Illustrated with 162 engravings and 2 coloured plates. Price 24s.

**Newman, David, M.D.,**

Surgeon, Glasgow Royal Infirmary.

**MALIGNANT DISEASE OF THE THROAT AND NOSE.**  
8vo, cloth, pp. xii., 213, with 3 illustrations. Price **8s. 6d.**

**Norris, W. F., A.M., M.D.,**

Professor of Ophthalmology, University of Pennsylvania;

and

**Oliver, C. A., A.M., M.D.,**

Surgeon to the Wills Eye Hospital, Philadelphia.

**TEXT-BOOK OF OPHTHALMOLOGY.** Royal 8vo, cloth,  
pp. viii., 622. Illustrated with 5 coloured plates and 357 woodcuts.  
Price **25s.**

**Oliver, Thomas, M.D., F.R.C.P.,**

Physician, Royal Infirmary, Newcastle-on-Tyne; Professor of Physiology, University of Durham.

**LEAD POISONING, IN ITS ACUTE AND CHRONIC FORMS.** 8vo, cloth, pp. xii., 122, with 32 illustrations, mostly in colours. Price **10s. 6d.**

**Osler, William, M.D., LL.D., F.R.S., F.R.C.P.,**

Professor of Medicine in the Johns Hopkins University, and Physician-in-Chief to the Johns Hopkins Hospital, Baltimore.

**THE PRINCIPLES AND PRACTICE OF MEDICINE.**  
Third Edition, thoroughly revised and largely rewritten. 8vo, cloth,  
pp. xvi., 1182, with charts and illustrations. Price **24s.**

**LECTURES ON ANGINA PECTORIS AND ALLIED STATES.** 8vo, cloth, pp. viii., 160. Price **6s. nett.**

**Park, Roswell, A.M., M.D.,**

Professor of the Principles and Practice of Surgery and of Clinical Surgery in the Medical Department of the University of Buffalo; Surgeon to the Buffalo General Hospital, etc.

**A TREATISE ON SURGERY,** by American Authors, for Students and Practitioners of Surgery and Medicine. Edited by **ROSWELL PARK, A.M., M.D.** 2 volumes, large 8vo, cloth, pp. 1603. Illustrated with 807 engravings and 38 full-page plates in colours and monochrome. Price **34s. nett.**

**Parvin, Theophilus, M.D., LL.D.,**

Professor of Obstetrics and Diseases of Women and Children in Jefferson Medical College, Philadelphia, and one of the Obstetricians to the Philadelphia Hospital.

THE SCIENCE AND ART OF OBSTETRICS. Third Edition, thoroughly revised. Large 8vo, cloth, pp. 685, with 269 wood engravings and 2 coloured plates. Price 18s.

**Pekelharing, C. A.,**

Professor in the Faculty of Medicine, University of Utrecht ;

and

**Winkler, C.,**

Lecturer in the University of Utrecht.

BERI-BERI: Researches concerning its Nature and Cause and the Means of its Arrest. Translated by JAMES CANTLIE, M.A., M.B., F.R.C.S. 8vo, cloth, pp. xvi., 160, with coloured illustrations from original drawings. Price 10s. 6d. nett.

**Potter, Samuel O. L., M.D., M.R.C.P. (Lond.),**

Cooper Medical College, San Francisco.

COMPEND OF HUMAN ANATOMY, Including the Anatomy of the Viscera. Sixth Edition, revised and enlarged. Crown 8vo, cloth, pp. 289, with 117 engravings and 16 full-page plates. Price 5s.

**Schäfer, E. A., LL.D., F.R.S.,**

Professor of Physiology, University of Edinburgh.

TEXT-BOOK OF PHYSIOLOGY. By British Physiologists. Edited by E. A. SCHÄFER, F.R.S., Professor of Physiology, University of Edinburgh. 2 vols., royal 8vo. Vol. I., pp. xx., 1036, with 3 plates and 93 illustrations in the text. Price 31s. 6d. Vol. II., pp. xxiv., 1365, with 449 illustrations in the text. Price 42s.

\* \* The list of contributors is as follows:—Professor Sir BURDON SANDERSON (Oxford), Professor GAMGEE, Dr. GASKELL (Cambridge), Professor GOTCH (Oxford), Professor SHERRINGTON (Liverpool), Professor M'KENDRICK (Glasgow), Professor HALLIBURTON (King's College), Professor HAYCRAFT (Cardiff), Dr. PEMBREY (Guy's), Professor STARLING (University College), J. N. LANGLEY (Cambridge), Professor WAYMOUTH REID (Dundee), B. MOORE (Charing Cross), F. G. HOPKINS (Cambridge), LEONARD HILL (London Hospital), W. H. R. RIVERS (Cambridge), J. S. EDKINS (St. Bartholomew's), A. A. GRAY (Glasgow), D. NOEL PATON (Edinburgh), and the Editor.



**Schech, Philip, M.D.,**

Lecturer in the University of Munich.

**DISEASES OF THE MOUTH, THROAT, AND NOSE.**  
Including Rhinoscopy and Methods of Local Treatment.  
Translated by R. H. BLAIKIE, M.D., F.R.S.E., formerly Surgeon,  
Edinburgh Ear and Throat Dispensary; late Clinical Assistant, Ear  
and Throat Department, Royal Infirmary, Edinburgh. 8vo, cloth,  
pp. xii., 302, with 5 wood engravings. Price 9s.

**Schmiedeberg, Dr. Oswald,**

Professor of Pharmacology, and Director of the Pharmacological Institute, University of Strassburg.

**ELEMENTS OF PHARMACOLOGY.** Translated under the  
Author's supervision, by THOMAS DIXSON, M.B., Lecturer on  
Materia Medica in the University of Sydney, N.S.W. 8vo, cloth,  
pp. xii., 223, with 7 illustrations. Price 9s.

**Sheild, A. Marmaduke, M.B. (Cantab.),  
F.R.C.S.,**

Surgeon and Surgeon in Charge, Throat Department, St. George's Hospital, London.

**SURGICAL ANATOMY:** For Students. Crown 8vo, cloth, pp.  
xii., 226. Price 6s. (*Pentland's Students' Manuals.*)

**Skene, Alexander J. C., M.D.,**

Professor of Gynecology in the Long Island College Hospital, Brooklyn New York.

**MEDICAL GYNECOLOGY:** A Treatise on the Diseases of  
Women from the Standpoint of the Physician. 8vo, cloth, pp.  
vi., 530, with illustrations in the text. Price 21s.

**Smith, W. Ramsay, M.B., B.Sc.,**

Formerly Demonstrator of Anatomy, School of Medicine, Minto House; Late Senior Assistant to the Professor of Natural History, University of Edinburgh.

**EXAMINATION QUESTIONS.** Set for the Professional Exam-  
inations in Edinburgh University during a period of ten years,  
selected from the Calendars.

**NATURAL HISTORY,** arranged and annotated. Price 1s. nett.

**BOTANY,** arranged and annotated. Price 1s. 6d. nett.

**CHEMISTRY,** answered and annotated. Price 2s. nett.

**ANATOMY,** answered and annotated. Price 2s. nett.

**MATERIA MEDICA AND THERAPEUTICS,** answered and  
annotated. Price 2s. nett.

**PHYSIOLOGY,** answered and annotated. Price 2s. nett.

**PATHOLOGY.** *In Press.*

**MIDWIFERY AND GYNÆCOLOGY,** answered and annotated.  
Price 1s. 6d. nett.

**PRACTICE OF PHYSIC,** answered and annotated. Price 1s. 6d. nett.

**SURGERY,** answered and annotated. Price 1s. 6d. nett.

**MEDICAL JURISPRUDENCE AND PUBLIC HEALTH** answered and annotated. Price 2s. nett.

### **Smith, W. Ramsay, M.B., B.Sc.,**

Formerly Demonstrator of Zoology, University of Edinburgh;  
and

### **Norwell, J. Stewart, B.Sc.**

**ILLUSTRATIONS OF ZOOLOGY, INVERTEBRATES AND VERTEBRATES.** New and cheaper Edition. Crown 4to, extra cloth, gilt top, with 70 plates exhibiting over 400 figures. Price 7s. 6d.

### **Snell, Simeon, F.R.C.S.Ed.,**

Ophthalmic Surgeon, Sheffield Royal Infirmary; Professor of Ophthalmology, University College, Sheffield.

**A PRACTICAL GUIDE TO THE EXAMINATION OF THE EYE.** For Students and Junior Practitioners. Crown 8vo, cloth, pp. xvi., 177, with 88 illustrations in the text. Price 5s.

### **Starr, Louis, M.D.,**

Late Clinical Professor of Diseases of Children in the Hospital of the University of Pennsylvania; Physician to the Children's Hospital, Philadelphia.

**DISEASES OF THE DIGESTIVE ORGANS IN INFANCY AND CHILDHOOD.** With Chapters on the Investigation of Disease and on the General Management of Children. Second Edition. Post 8vo, cloth, pp. 396, with illustrations. Price 10s.

### **Stephenson, Sydney, M.B., F.R.C.S.Ed.,**

Surgeon to the Ophthalmic School, Hanwell, London.

**EPIDEMIC OPHTHALMIA: Its Symptoms, Diagnosis, and Management.** 8vo, cloth, pp. xvi., 278. Illustrated with a coloured plate and 25 figures in the text. Price 9s. nett.

### **Stewart, Sir Thomas Grainger, M.D., LL.D.,**

Late Physician in Ordinary to Her Majesty the Queen, for Scotland; Professor of the Practice of Physic and of Clinical Medicine in the University of Edinburgh.

**LECTURES ON GIDDINESS AND ON HYSTERIA IN THE MALE.** Second Edition. Crown 8vo, cloth, pp. x., 89, with 13 illustrations. Price 2s. 6d. nett.

## System of Gynecology and Obstetrics.

By American Authors. Edited by MATTHEW D. MANN, A.M., M.D., Professor of Obstetrics and Gynecology in the Medical Department of the University of Buffalo, N.Y.; and BARTON COOKE HIRST, M.D., Associate Professor of Obstetrics in the University of Pennsylvania; Obstetrician to the Philadelphia and Maternity Hospitals; Gynecologist to the Orthopædic Hospital. In 8 very handsome volumes, royal 8vo, cloth, of about 400 pages each. Fully illustrated with engravings and coloured plates. Price 12s. 6d. each nett. For sale by subscription only.

## Talamon, Ch.,

Physician to the Tenon Hospital, Paris.

APPENDICITIS AND PERITYPHLITIS. Translated from the French by RICHARD J. A. BERRY, M.B., C.M., Late President of the Royal Medical Society, Edinburgh. Crown 8vo, cloth, pp. viii., 240. Price 6s.

## Taylor, Robert W., M.D.,

Clinical Professor of Venereal Diseases at the College of Physicians and Surgeons (Columbia College), New York; Surgeon to Bellevue Hospital, and Consulting Surgeon to City (Charity) Hospital, New York.

THE PATHOLOGY AND TREATMENT OF VENEREAL DISEASES. Royal 8vo, cloth, pp. 1002. Illustrated with 230 engravings in the text and 7 coloured plates. Price 22s. nett.

## Text-Book on Nervous Diseases. By American Authors.

See DERCUM.

## Text-Book of Physiology. By British Physiologists.

See SCHÄFER.

## Text-Book of Medicine. By British Teachers.

See GIBSON.

## Text-Book of Pharmacology and Therapeutics. By British and American Teachers.

See WHITE.

## Thomson, J. Arthur, M.A.,

Regius Professor of Natural History in the University of Aberdeen.

OUTLINES OF ZOOLOGY. Third Edition, revised and enlarged. Crown 8vo, cloth, pp. xx., 820, with 323 illustrations in the text. Price 15s. (*Pentland's Students' Manuals.*)



**Walley, Thomas, M.R.C.V.S.,**

Late Principal of the Edinburgh Royal (Dick's) Veterinary College; Professor of Veterinary Medicine and Surgery.

**A PRACTICAL GUIDE TO MEAT INSPECTION.** Fourth Edition, thoroughly revised and edited by J. M'FADYEAN, Principal and Professor of Comparative Anatomy, Royal Veterinary College, London. Post 8vo, cloth, pp. xvi., 198, with coloured illustrations. Price **10s. 6d.** *In Press.*

**Waring, H. J., M.S., B.Sc.(Lond.), F.R.C.S.,**

Demonstrator of Operative Surgery, and Senior Demonstrator of Anatomy, St. Bartholomew's Hospital; Senior Assistant Surgeon, Metropolitan Hospital; Surgeon to the Belgrave Hospital for Children, London.

**DISEASES OF THE LIVER, GALL BLADDER, AND BILIARY SYSTEM;** their Pathology, Diagnosis, and Surgical Treatment. 8vo, cloth, pp. xvi., 385, with 58 engravings. Price **12s. 6d. nett.**

**MANUAL OF OPERATIVE SURGERY.** Crown 8vo, cloth, pp. xxxii., 662, with 420 illustrations in the text. Price **12s. 6d.**

**Warren, Geo. W., D.D.S.,**

Clinical Chief, Pennsylvania College of Dental Surgery.

**COMPEND OF DENTAL PATHOLOGY AND DENTAL MEDICINE.** Crown 8vo, cloth, pp. 109. Price **4s. 6d.**

**Webster, J. Clarence, B.A., M.D., F.R.C.P.Ed.,**

Professor of Midwifery and Diseases of Women in the University of Chicago; formerly Demonstrator of Gynæcology, M'Gill University; Assistant Gynæcologist, Royal Victoria Hospital, Montreal; Assistant to the Professor of Midwifery and Diseases of Women and Children in the University of Edinburgh.

**ECTOPIC PREGNANCY:** its Etiology, Classification, Embryology, Diagnosis, and Treatment. 8vo, cloth, pp. xvi., 240, with 22 pages of plates and 15 figures throughout the text. Price **12s. 6d. nett.**

**RESEARCHES IN FEMALE PELVIC ANATOMY.** Demy 4to, cloth, gilt top, xiv., 129. Illustrated with 26 full-page coloured plates, from original drawings. Price **30s. nett.**

**TUBO-PERITONEAL ECTOPIC GESTATION.** Demy 4to, cloth, gilt top, pp. xii., 54. Illustrated with 11 full-page plates, exhibiting numerous figures, mostly coloured. Price **16s. nett.**

**PRACTICAL AND OPERATIVE GYNECOLOGY.** Crown 8vo, cloth, pp. xvi., 295. Illustrated with 54 engravings. Price **7s. 6d.**

DISEASES OF WOMEN. A Text-Book for Students and Practitioners. Crown 8vo, cloth, pp. xxiv., 688, with 241 illustrations. Price 14s.

**White, W. Hale, M.D., F.R.C.P.,**

Physician and Lecturer on Medicine, Guy's Hospital, London.

TEXT-BOOK OF PHARMACOLOGY AND THERAPEUTICS.  
Royal 8vo, pp. xxiv., 1016. *In Press.*

**Williamson, Richard T., M.D., M.R.C.P.,**

Medical Registrar, Manchester Royal Infirmary; Hon. Medical Officer, Pendleton Dispensary; Assistant to Professor of Medicine, Owens College, Manchester.

DIABETES MELLITUS AND ITS TREATMENT. 8vo, cloth, pp. xvi., 417, with 18 illustrations (two coloured). Price 12s. 6d. nett.

**Winckel, Dr. F.,**

Professor of Gynæcology and Director of the Royal Hospital for Women; Member of the Supreme Medical Council and of the Faculty of Medicine in the University of Munich.

TEXT-BOOK OF OBSTETRICS, including the Pathology and Therapeutics of the Puerperal State. Designed for Practitioners and Students of Medicine. Translated from the German under the supervision of J. CLIFTON EDGAR, A.M., M.D., Adjunct Professor of Obstetrics in the Medical Department of the University of the City of New York. Royal 8vo, cloth, pp. 927. Illustrated with 190 engravings, mostly original. Price 28s.

**Woodhead, G. Sims, M.D., F.R.C.P.Ed.,**

Professor of Pathology, University of Cambridge.

PRACTICAL PATHOLOGY: A Manual for Students and Practitioners. Third enlarged and thoroughly revised Edition. 8vo, cloth, pp. xxiv., 652, with 195 coloured illustrations, mostly from original drawings. Price 25s.

**Woodhead, G. Sims, M.D., F.R.C.P.Ed.,**

and

**Hare, Arthur W., M.B., C.M.**

PATHOLOGICAL MYCOLOGY: An Enquiry into the Etiology of Infective Diseases. Section 1.—Methods. 8vo, cloth, pp. xii., 174, with 60 illustrations, mostly original (34 in colours). Price 8s. 6d.

## CLASSIFIED INDEX.

<b>Abdominal Surgery,</b> . . . . .	KEITH.
<b>Abscesses</b> (Treatment), . . . . .	CHEYNE.
<b>Anatomy</b> (Practical), . . . . .	CUNNINGHAM.
" (Text-Book), . . . . .	CUNNINGHAM.
" (Compend of), . . . . .	POTTER.
" (Surgical), . . . . .	SHEILD.
" (Examination Questions), . . . . .	SMITH.
" (Female Pelvic), . . . . .	WEBSTER.
<b>Angina Pectoris,</b> . . . . .	OSLER.
<b>Appendicitis,</b> . . . . .	TALAMON.
<b>Aseptic Surgery,</b> . . . . .	LOCKWOOD.
<b>Atlases</b> (Brain), . . . . .	BRUCE.
" (Eye), . . . . .	FROST.
" (Skin), . . . . .	CROCKER.
" (Venereal Diseases), . . . . .	MACLAREN.
<b>Bacteriology,</b> . . . . .	MUIR & RITCHIE.
" . . . . .	WOODHEAD & HARE.
" <b>and Pathology, Journal of.</b>	
<b>Beri-Beri,</b> . . . . .	PEKELHARING.
<b>Bones and Joints</b> (Disease of), . . . . .	CHEYNE.
<b>Botany</b> (Text-Book), . . . . .	BEHRENS.
" (Manual), . . . . .	JOHNSTONE.
" (Examination Questions), . . . . .	SMITH.
<b>Brain</b> (Tumours), . . . . .	BRAMWELL.
, (Illustrations of Nerve Tracts), . . . . .	BRUCE.
<b>Chemistry</b> (Examination Questions), . . . . .	SMITH.
<b>Children</b> (Diseases), . . . . .	CARMICHAEL.
" (Compend of Diseases), . . . . .	HATFIELD.
" (Treatment of Diseases), . . . . .	MUSKETT.
" (Digestive Organs in), . . . . .	STARR.
<b>Clinical Gynæcology,</b> . . . . .	KEATING & COE.
" <b>Medicine</b> . . . . .	ANDERSON.
"       " . . . . .	GIBSON & RUSSELL.



Clinical Medicine, . . . . .	MUSSER.
Dental Pathology, . . . . .	WARREN.
Dermatology (Atlas), . . . . .	CROCKER.
" . . . . .	JAMIESON
" . . . . .	MORROW.
Diabetes Mellitus, . . . . .	WILLIAMSON.
Diagnosis (Ophthalmoscopic), . . . . .	BERRY.
" (Physical), . . . . .	GIBSON & RUSSELL.
" (Medical), . . . . .	MUSSER.
Dictionary of Terms (5 languages), . . . . .	BILLINGS.
" . . . . .	KEATING.
Diet, . . . . .	BRUEN.
Digestive Organs in Children, . . . . .	STARR.
Ear (Diseases), . . . . .	BURNETT.
" . . . . .	M'BRIDE.
Ectopic Gestation, . . . . .	WEBSTER.
Edinburgh Medical Journal.	
Epidemic Ophthalmia, . . . . .	STEPHENSON.
Epilepsy, . . . . .	ALEXANDER.
Examination Questions, . . . . .	SMITH.
Eye (Diseases), . . . . .	BERRY.
" (Atlas), . . . . .	FROST.
" (Diseases), . . . . .	NORRIS & OLIVER.
" (Examination of), . . . . .	SNELL.
" (Epidemic Ophthalmia), . . . . .	STEPHENSON.
" (Toxic Amblyopias), . . . . .	DE SCHWEINITZ.
Genito-Urinary Diseases, . . . . .	MORROW.
Geographical Pathology, . . . . .	DAVIDSON
Gestation (Ectopic), . . . . .	WEBSTER.
Giddiness, . . . . .	STEWART.
Gynæcological Operations, . . . . .	KEITH.
Gynæcology (Text-Book), . . . . .	KEATING & COE.
" (Medical), . . . . .	SKENE.
" (Examination Questions), . . . . .	SMITH.
" (Practical), . . . . .	WEBSTER.
" (Manual), . . . . .	"
" and Obstetrics (System of), . . . . .	MANN & HIRST.
Heart (Diseases), . . . . .	BRAMWELL.
" (Mitral Murmurs), . . . . .	BROCKBANK.

<b>Heart</b> (Diseases), . . . . .	GIBSON.
„ (Angina Pectoris), . . . . .	OSLER.
<b>Hernia</b> , . . . . .	LOCKWOOD.
<b>Human Monstrosities</b> , . . . . .	HIRST & PIERSOL.
<b>Hydatid Disease</b> , . . . . .	GRAHAM.
<b>Hygiene and Diseases of Warm Climates</b> , . . . . .	DAVIDSON.
<b>Hysteria</b> , . . . . .	STEWART.
<b>Infective Diseases</b> , . . . . .	LOCKWOOD.
<b>Intracranial Tumours</b> , . . . . .	BRAMWELL.
<b>Involution of Life</b> , . . . . .	MAGUIRE.
<b>Joints</b> (Tuberculous Disease), . . . . .	CHEYNE.
<b>Journal of Pathology</b> , . . . . .	
„ (Edinburgh Medical), . . . . .	
<b>Jurisprudence, Medical</b> (Examination Questions),	SMITH.
<b>Kidney</b> (Renal Growths) . . . . .	KELYNACK.
<b>Lead Poisoning</b> , . . . . .	OLIVER.
<b>Life, Involution of</b> , . . . . .	MAGUIRE.
<b>Liver</b> (Diseases of), . . . . .	WARING.
<b>Malignant Disease of Throat and Nose</b> , . . . . .	NEWMAN.
<b>Materia Medica</b> (Examination Questions), . . . . .	SMITH.
<b>Meat Inspection</b> , . . . . .	WALLEY.
<b>Medical Diagnosis</b> , . . . . .	MUSSER.
„ <b>Dictionary</b> (5 languages), . . . . .	BILLINGS.
„ „ . . . . .	KEATING.
„ <b>Gynæcology</b> , . . . . .	SKENE.
„ <b>Jurisprudence</b> (Examination Questions),	SMITH.
<b>Medicine</b> (Clinical) . . . . .	ANDERSON.
<b>Medicine</b> (Text-Book of), . . . . .	GIBSON.
„ (Text-Book of), . . . . .	OSLER.
„ (Examination Questions), . . . . .	SMITH.
<b>Midwifery</b> (Treatise on), . . . . .	DAVIS.
„ (Compend of), . . . . .	LANDIS.
„ (Manual of), . . . . .	MURRAY.
„ (Text-Book), . . . . .	PARVIN.
„ (Examination Questions), . . . . .	SMITH.
„ (System of), . . . . .	MANN & HIRST.
„ (Text-Book of), . . . . .	WINCKEL.
<b>Mitral Murmurs</b> , . . . . .	BROCKBANK.
<b>Monstrosities</b> (Human), . . . . .	HIRST & PIERSOL.

<b>Morbid Anatomy,</b>	.	.	.	HALL.
<b>Mouth, Throat and Nose (Diseases),</b>	.	.	.	SCHECH.
<b>Natural History (Examination Questions),</b>	.	.	.	SMITH.
"    "    (Illustrations),	.	.	.	SMITH & NORWELL.
"    "    (Text-Book),	.	.	.	THOMSON.
<b>Nervous Diseases (Epilepsy),</b>	.	.	.	ALEXANDER.
"    "    (Text-Book),	.	.	.	DERCUM.
"    "    "    "    "    "	.	.	.	MILLS.
"    "    (Nursing),	.	.	.	MILLS.
<b>Nervous System and Visceral Disease,</b>	.	.	.	MORISON.
<b>Nose (Diseases),</b>	.	.	.	MCBRIDE.
"    (Diseases),	.	.	.	SCHECH.
<b>Nose and Throat (Malignant Disease of),</b>	.	.	.	NEWMAN.
<b>Nursing (Obstetric),</b>	.	.	.	HAULTAIN & FERGUSON.
"    (Insane),	.	.	.	MILLS.
<b>Obstetric Nursing,</b>	.	.	.	HAULTAIN & FERGUSON.
<b>Obstetrics (Text-Book of),</b>	.	.	.	DAVIS.
"    (Compend of),	.	.	.	LANDIS.
"    (Manual of),	.	.	.	MURRAY.
"    (Science and Art of),	.	.	.	PARVIN.
"    (System of),	.	.	.	MANN & HIRST.
"    (Text-Book of),	.	.	.	WINCKEL.
<b>Ophthalmia (Epidemic),</b>	.	.	.	STEPHENSON.
<b>Ophthalmology (Text-Book of),</b>	.	.	.	NORRIS & OLIVER.
<b>Ophthalmoscopic Diagnosis,</b>	.	.	.	BERRY.
<b>Ophthalmoscopy (Atlas of),</b>	.	.	.	FROST.
<b>Parasites of Man,</b>	.	.	.	LEUCKART.
<b>Pathological Mycology,</b>	.	.	.	WOODHEAD & HARE.
<b>Pathology (Geographical),</b>	.	.	.	DAVIDSON.
"    (Practical),	.	.	.	GIBBES.
"    (Compend of)	.	.	.	HALL.
"    (Dental),	.	.	.	WARREN.
"    (Practical),	.	.	.	WOODHEAD.
<b>Pathology and Bacteriology (Journal of).</b>	.	.	.	
<b>Pediatrics,</b>	.	.	.	CARMICHAEL.
"    "    "    "    "    "	.	.	.	HATFIELD.
"    "    "    "    "    "	.	.	.	MUSKETT.
"    "    "    "    "    "	.	.	.	STARR.
<b>Pharmacology,</b>	.	.	.	SCHMIEDEBERG.
"    (Text-Book),	.	.	.	HALE WHITE.
<b>Physical Diagnosis,</b>	.	.	.	GIBSON & RUSSELL.



Physiology (Examination Questions), . . . . .	SMITH.
"    (Text-Book), . . . . .	SCHÄFER.
Poisoning (Lead), . . . . .	OLIVER.
Practice of Medicine (Text-Book of), . . . . .	GIBSON.
"    "    (Text-Book of), . . . . .	OSLER.
"    "    (Exam. Questions), . . . . .	SMITH.
Pregnancy (Ectopic), . . . . .	WEBSTER.
Prescribing and Treatment of Children's Diseases, . . . . .	MUSKETT.
Renal Growths, . . . . .	KELYNACK.
Septic Diseases, . . . . .	CHEYNE.
Sexual Organs (Diseases), . . . . .	FULLER.
Skin Diseases (Atlas of), . . . . .	CROCKER.
"    "    . . . . .	JAMIESON.
"    "    . . . . .	MORROW.
Stomach (Diseases), . . . . .	MARTIN.
Surgery (Abdominal), . . . . .	KEITH.
"    (Aseptic), . . . . .	LOCKWOOD.
"    (Treatise on), . . . . .	PARK.
"    (Examination Questions), . . . . .	SMITH.
"    (Operative), . . . . .	WARING.
Surgical Anatomy, . . . . .	SHEILD.
Syphilology, . . . . .	MORROW.
"    . . . . .	TAYLOR.
System of Genito-Urinary Diseases, . . . . .	MORROW.
"    Gynæcology and Obstetrics, . . . . .	MANN & HIRST.
"    Therapeutics, . . . . .	HARE.
Teratology, . . . . .	HIRST & PIERSOL.
Therapeutics (Synopsis), . . . . .	AITCHISON.
"    (Principles of Treatment) . . . . .	BRUCE.
"    (System), . . . . .	HARE.
"    (Physical and Natural), . . . . .	HAYEM & HARE.
"    (Examination Questions) . . . . .	SMITH.
"    (Text-Book), . . . . .	HALE WHITE.
Throat (Diseases), . . . . .	SCHECH.
"    and Nose (Malignant Disease of), . . . . .	NEWMAN.
"    Nose and Ear (Diseases), . . . . .	MCBRIDE.
Toxic Amblyopias, . . . . .	DE SCHWEINITZ.
Traumatic Infection, . . . . .	LOCKWOOD.
Treatment (Principles of), . . . . .	BRUCE.

---

<b>Tropical Diseases,</b> . . . .	DAVIDSON.
"    "    "    "    "    "    "    "    "    "	FELKIN.
<b>Tumours (Intracranial),</b> . . . .	BRAMWELL.
<b>Ulcers (Treatment),</b> . . . .	CHEYNE.
<b>Urine,</b> . . . .	HOLLAND.
<b>Venereal Diseases,</b> . . . .	MACLAREN.
"    "    "    "    "    "    "    "    "    "	MORROW.
"    "    "    "    "    "    "    "    "    "	TAYLOR.
<b>Visceral Disease and Nervous System,</b> . . . .	MORISON.
<b>Warm Climates (Diseases),</b> . . . .	DAVIDSON.
<b>Women (Diseases of),</b> . . . .	KEATING & COE.
"    (Diseases), . . . .	SKENE.
"    (Diseases of), . . . .	WEBSTER.
<b>Wounds (Treatment),</b> . . . .	CHEYNE.
<b>Zoology (Examination Questions),</b> . . . .	SMITH.
"    (Illustrations of), . . . .	SMITH & NORWELL.
"    (Outlines of), . . . .	THOMSON.

128

390













**PLEASE DO NOT REMOVE  
CARDS OR SLIPS FROM THIS POCKET**

---

**UNIVERSITY OF TORONTO LIBRARY**

---

BioMed



